

Content available at: <https://www.ipinnovative.com/open-access-journals>

IP Indian Journal of Conservative and Endodontics

Journal homepage: <https://www.ijce.in/>

Case Report

Nasopalatine duct cyst: A jigsaw puzzle

Harleen Kaur¹, Munish Singla¹, Rupinder Bansal², Litik Mittal¹, Vaani Mahajan^{1,*}

¹Dept. of Conservative and Endodontics, Adesh Institute of Dental Sciences and Research, Bathinda, Punjab, India

²Dept. of Oral Surgery, Adesh Institute of Dental Sciences and Research, Bathinda, Punjab, India



ARTICLE INFO

Article history:

Received 16-08-2021

Accepted 10-09-2021

Available online 25-09-2021

Keywords:

Apical periodontitis

Cone beam computed tomography

Diagnosis

Nonodontogenic cyst

Nasopalatine duct cyst

Periapical radiograph

ABSTRACT

For the success of endodontic treatment outcome, diagnosis plays a very important role. Endodontic diagnosis is similar to a jigsaw puzzle which cannot be made from a single isolated piece of information. Radiography plays a vital role in diagnosing dental diseases. Overcoming the major disadvantage of two dimensional imaging of superimposing the dento-alveolar structures, 3 dimensional images by Cone Beam Computed Tomography is of great help. It is very common that when radiographs show a superimposition of the incisive foramen over the apex of maxillary central incisors, mimicking apical periodontitis, unnecessary endodontic treatment or retreatment may be prescribed. Diseases of non endodontic origin that affect the tooth apex, such as Nasopalatine duct cyst, should be included in the differential diagnosis. In the present case report the role of CBCT in diagnosis is being discussed.

This is an Open Access (OA) journal, and articles are distributed under the terms of the [Creative Commons Attribution-NonCommercial-ShareAlike 4.0 License](#), which allows others to remix, tweak, and build upon the work non-commercially, as long as appropriate credit is given and the new creations are licensed under the identical terms.

For reprints contact: reprint@ipinnovative.com

1. Introduction

Endodontic diagnosis is similar to a jigsaw puzzle which cannot be made from a single isolated piece of information. For the accurate diagnostic assessment, treatment planning and follow-up of patients suspected of having dental and maxillofacial disease, radiology is an essential aspect.¹ Until few years ago, periapical radiographs were the main radiographic investigation used in the endodontic treatment.² However, conventional radiography represents two-dimensional (2D) image of three dimensional (3D) objects with significant structure superimposition and unpredictable magnification. The advent of digital radiographic imaging introduced relevant improvements in endodontic diagnosis.³ The first Cone Beam Computed Tomography (CBCT) scanner was developed in 1997, represents new development in dento-maxillofacial radiology and precipitated a shift from 2

dimensional to 3 dimensional data acquisition, image reconstruction and visualization.⁴ Some of the non endodontic pathologies are misdiagnosed as endodontic lesions. The nasopalatine duct cyst (NPDC) can often be misdiagnosed as being endodontic in nature. It is one of the most common nonodontogenic, epithelial and developmental cysts of the oral cavity located in the midline of anterior maxilla near the incisive foramen, occurring in 1% of the population. Clinically, it is asymptomatic and with the lesion being detected on routine radiographs. However, many will present with one or more symptoms consisting primarily of swelling, drainage and pain.⁵ Tooth vitality is not affected by NPDC, however it is common to see evidence of root canal treatment when NPDC's are misinterpreted as a periapical lesion, the differential diagnosis becomes clouded.⁶ In such cases, conventional radiographs may not be sufficient enough to diagnose ambiguous pathology.⁷

* Corresponding author.

E-mail address: Vaanimahajan111@gmail.com (V. Mahajan).

2. Case Report

A 15-year-old girl patient presented to the Department of Conservative Dentistry and Endodontics, with a chief complaint of painless swelling on the anterior palate. The patient also complained of pus discharge from the swelling along with salty taste in the mouth since two days. There was no history of trauma. Clinical examination showed a swelling in the anterior palate with draining sinus (Figure 1). The swelling was fluctuant, round in shape, non tender with no discoloration of teeth was noted. Upon evaluating the vitality of the tooth with electric pulp tester, the associated tooth was found to be vital. Periapical radiograph showed a well defined, ovoid, unilocular radiolucency around the apex of tooth #11 with widening of periodontal ligament space (Figure 2). Afterwards, the tracing of sinus tract was done with number 25 gutta percha point. Radiographic examination revealed that the gutta percha was pointed in between the maxillary teeth #11 and 21 (Figures 1 and 2). Since, the sinus tract was not related to either of tooth #11 and 21. Hence, it was estimated that the lesion was non endodontic in nature. So, to confirm the diagnosis, the patient was referred for 3D diagnostic imaging i.e. Cone Beam Computed Tomography (CBCT). CBCT scan revealed that the lesion was non odontogenic in nature. It showed well-defined radiolucency in the region of nasopalatine canal approximately 9.7mm x 9.6mm in diameter in axial section with noticeable thinning and eroded palatal cortical bone with enlarged nasopalatine canal space in the sagittal section. Slight displacement of the teeth 11 and 21 was also seen (Figure 3). Based on clinical evaluation and 3D imaging, a diagnosis of nasopalatine duct cyst was considered. The treatment plan was established encompassing surgical enucleation of the lesion. All the investigations were done prior to the surgery. Under local anesthesia, the cyst was approached palatally followed by enucleation and cleaning of the surgical cavity. The flap was then repositioned and sutured (Figure 4).

3. Discussion

Nasopalatine duct cyst is the most common developmental, nonodontogenic cyst affecting the anterior maxillary region. It was first described by Meyer in 1914. The nasopalatine duct lining is believed to degenerate; however, sometimes the epithelial remnant persists may later proliferate due to trauma, bacterial infections or mucous retention that gives rise to NPDC.⁸ In majority of cases, it is asymptomatic and diagnosed accidentally on routine radiographic examination. But, in severe cases, it seems to become large, painless swelling in the anterior maxilla associated with discharge and burning sensation due to pressure on the nasopalatine nerve.⁶

Heart shaped radiolucency in NPDC is due to superimposition of anterior nasal spine seen in periapical

radiograph can cloud the judgment and misdiagnosed as periapical lesion.⁶ It is essential to differentiate nasopalatine type cysts from radicular cyst.

Presence of intact lamina dura and a positive response to pulp vitality tests, suggests the lesion to be of non odontogenic origin. Whereas, in radicular cyst, the tooth becomes non vital due to necrosis of pulp.⁹ Furthermore, alteration of horizontal angulation (Clark technique) of periapical radiograph changes the position of NPDC whilst radicular cyst maintain its position around the apex of the tooth.¹⁰ Histopathologic examination can also confirm the diagnosis. 71.8% of NPDCs have stratified squamous, pseudostratified cuboidal or columnar type of epithelium, depending on the location of the cyst⁸ whereas radicular cyst is lined by non keratinized stratified squamous epithelium.¹¹

Among the various imaging methods, periapical radiographs represents only 2 dimensional image of the dental lesion which can limit the accurate diagnosis.

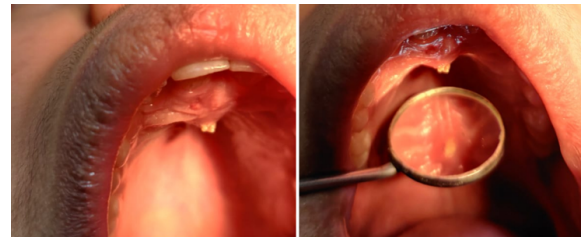


Fig. 1: Intraoral photograph showing the swelling on the anterior palate.

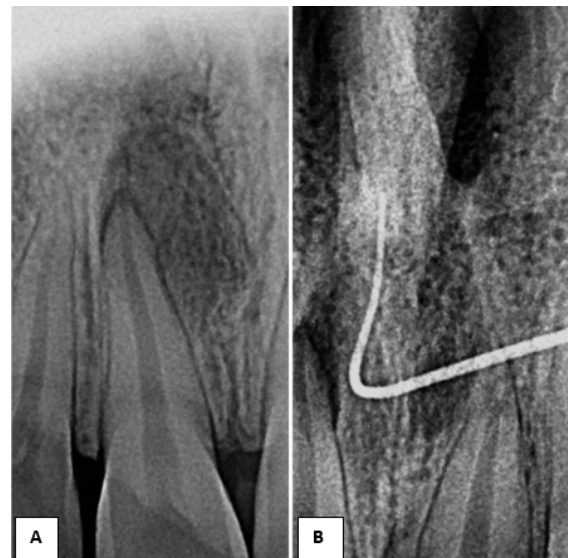


Fig. 2: Periapical radiograph(A) Showing well defined radiolucency at the apex of tooth #11 (B) Radiograph showing sinus tracing.

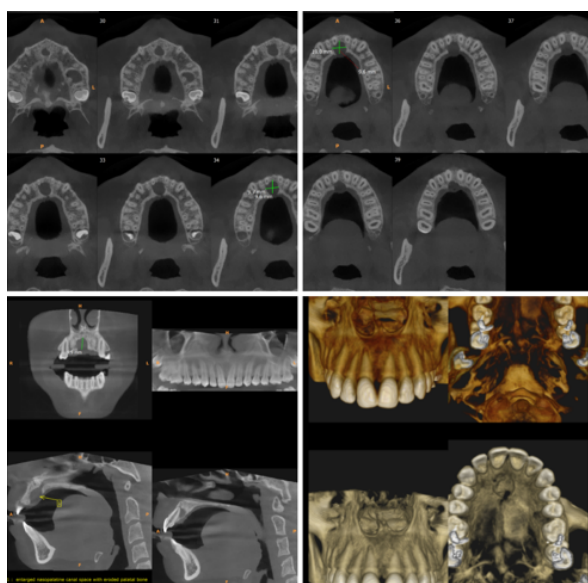


Fig. 3: CBCT demonstrating the radiolucency at the maxillary midline with eroded palatal bone and displacement of roots of teeth # 11 and 21.

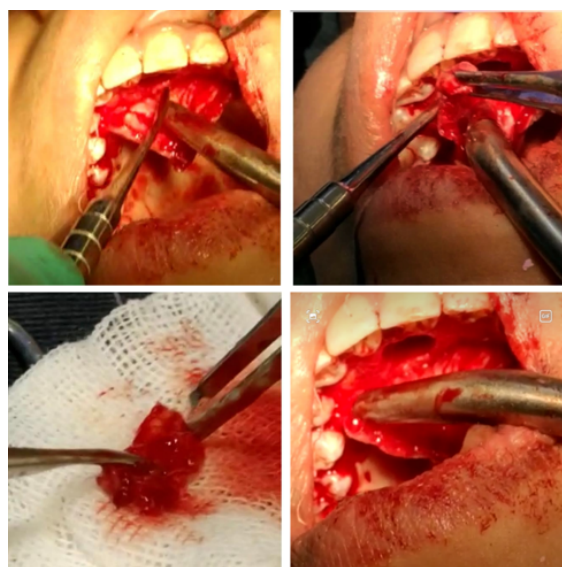

Fig. 4: Surgical enucleation the cyst.

Among the various imaging methods, periapical radiographs represents only 2 dimensional image of the dental lesion which can limit the accurate diagnosis. Advanced imaging techniques like cone beam computed tomography (CBCT) can be used to differentially diagnose the nasopalatine cyst from other maxillary anterior radiolucencies like radicular cyst or granuloma.³ The treatment recommended for NPDC is the surgical enucleation. It has good prognosis if performed properly.¹² Post operative complications may occur such as postoperative infection, hemorrhage, paraesthesia and

pain. Although, the recurrence rate is low ranging from 0-11%, still follow up of the patient should be taken in consideration.¹² The present case signifies the importance of correct diagnosis of such lesions which can be easily misinterpreted as periapical lesion leading to the inadvertent endodontic procedure in vital teeth.

4. Conclusion

Nasopalatine cyst is the most common developmental and non odontogenic cyst of the oral cavity with distinctive clinical features. It should be differentially diagnosed from the other radiolucencies present in the anterior maxillary region. With the advent of 3 dimensional imaging techniques such as CBCT, it allows better visualization of lesion boundaries for proper diagnosis and treatment of the lesion. The new diagnostic tools provide high-resolution images of oral structures, which help to make an initial diagnostic hypothesis and to plan surgery.

5. Source of Funding

None.

6. Conflict of Interest

None.

References

1. Sane VD, Gadre KS, R H. Role of Cone-Beam Computed Tomography in Diagnosis and Management of Nasopalatine Duct Cyst. *J Craniofac Surg.* 2014;25(1):92–4. doi:10.1097/SCS.0000000000000427.
2. Giudice RL, Nicita F, Puleio F. Accuracy of periapical radiography and cbct in endodontic evaluation. *Int J Dentistry.* 2018;2018:2514243. doi:10.1155/2018/2514243.
3. Panjwani S, Arora S, Rai S. Role of cone beam computed tomography in the prompt diagnosis of a nasopalatine duct cyst. *J Indian Acad Oral Med Radiol.* 2014;26(3):338–41. doi:10.4103/0972-1363.145023.
4. Suter VGA, Sendi P, Reichart PA. The nasopalatine duct cyst: An analysis of the relation between clinical symptoms, cyst dimensions and involvement of neighboring anatomical structures using cone beam computed tomography. *J Oral Maxillofac Surg.* 2011;69(10):2595–603. doi:0.1016/j.joms.2010.11.032.
5. Perez AT, Mamani MP, Santana E, Damante. Nasopalatine Cyst: A Silent Growing Lesion. *Biomed J Sci & Tech Res. Biomed J Sci Tech Res.* 2017;1(3):881–6. doi:10.26717/BJSTR.2017.01.000326.
6. I Qahtani A, AlDossari A, Nasser A, AlOtaibi K. Nasopalatine duct cyst: A diagnostic dilemma: A case report. *Dent Oral Craniofacial Res.* 2018;4(4):1–6. doi:10.26717/BJSTR.2017.01.000326.
7. Hilfer PB, Bergeron BE, Ozgul ES. Misdiagnosis of a nasopalatine duct cyst: A case report. *J Endod.* 2013;39(9):1185–8. doi:10.1016/j.joen.2013.04.033.
8. Shafer WG, Hine MK, Levy BM. Textbook of Oral Pathology. ; 2012. p. 1050.
9. Dedhia P, Dedhia S, Dhokar A. Nasopalatine Duct Cyst: A case report. *Case Rep Dent.* 2013;2013:869516. doi:10.1155/2013/869516.
10. Aparna M, Chakravarthy A, Acharya SR. A clinical report demonstrating the significance of distinguishing a nasopalatine duct cyst from a radicular cyst. *Br Med J.* 2014;2014:2013200329. doi:10.1136/bcr-2013-200329.

11. Harshitha KR, Varsha VK, C D. Radicular cyst: A case report. *Int J Appl Dent Sci*. 2015;1(4):20–22.
12. Oliveira LJ, Leao P, Alvarenga RR. Nasopalatine duct cyst: diagnosis, treatment and postoperative complications: report of two cases. *J Bras Patol Med Lab*. 2017;53(6):407–20. doi:10.5935/1676-2444.20170066.

Rupinder Bansal, Professor

Litik Mittal, Reader

Vaani Mahajan, P G Student

Author biography

Harleen Kaur, Professor

Munish Singla, Professor and HOD

Cite this article: Kaur H, Singla M, Bansal R, Mittal L, Mahajan V. Nasopalatine duct cyst: A jigsaw puzzle. *IP Indian J Conserv Endod* 2021;6(3):185-188.