

Content available at: <https://www.ipinnovative.com/open-access-journals>

IP Indian Journal of Conservative and Endodontics

Journal homepage: <https://www.ijce.in/>

Case Report

Non-surgical management of mandibular first premolar with vertucci type v root canal configuration: A case report

Neelam Mittal¹, Mohd Faisal Azeez^{1*}, Shelly Sharma¹

¹Faculty of Dental Sciences, BHU, Varanasi, Uttar Pradesh, India



ARTICLE INFO

Article history:

Received 03-06-2024

Accepted 06-08-2024

Available online 05-09-2024

Keywords:

Complex anatomy

Endodontic enigma

Mandibular first premolar

Nonsurgical management

Root canal morphology

Root canal treatment

Vertucci type V

ABSTRACT

Mandibular premolars are known for having a complex anatomy, often considered as enigma to endodontist. Thorough knowledge of the root canal morphology, appropriate assessment of the pulp chamber floor and proper interpretation of radiograph is a prerequisite for successful root canal therapy.

The complex anatomy and morphology of root canals can be classified according to VERTUCCI root canal classification system. VERTUCCI type V is a characterization given to a root where a canal is divided into two separate root canals with two separate apical foramina.

Such type of cases with complex anatomy of the root canal can be successfully managed if the clinician has thorough knowledge of root canals.

This is an Open Access (OA) journal, and articles are distributed under the terms of the [Creative Commons Attribution-NonCommercial-ShareAlike 4.0 License](https://creativecommons.org/licenses/by-nc-sa/4.0/), which allows others to remix, tweak, and build upon the work non-commercially, as long as appropriate credit is given and the new creations are licensed under the identical terms.

For reprints contact: reprint@ipinnovative.com

1. Introduction

The success of root canal treatment depends on cleaning, shaping and obturation of the canal spaces in all dimensions. Slowey^{1,2} has used the term “Endodontist’s enigma for mandibular first premolar because it is most difficult tooth to perform successful endodontic treatment as this tooth is having many anatomical configurations.

Anatomic root canal variations are classified into different types by the Vertucci. According to him, If a single root canal in the coronal region, divides into two separate canals in the apical region of tooth, Then, this configuration is known as type V.

Many studies showed that mostly mandibular first premolar shows one and two root canal system ranged from 69.3%-86% and 14%-25.5%³ respectively. However, some mandibular first premolars show type V canal configuration accounted for only 1.5% to 6.66% of all mandibular first premolars.^{3,4}

2. Case History

A 27year old male patient reported to the department of Conservative Dentistry and Endodontics, Faculty of Dental sciences with the chief complaint of pain and swelling in right lower back region of the mouth for the past 3 days. Patient’s medical and dental history was insignificant. Clinical examination revealed a carious right mandibular first premolar. The tooth was tender on percussion. Thorough radiographic examination revealed existence of single root with one canal in coronal region dividing into two separate canals in apical region, suggesting a Vertucci type V root canal configuration (Figure 1). Periapical radiolucency was observed in intraoral periapical radiograph, indicating periapical lesion.

The radiographic examination led to a diagnosis of chronic periapical abscess in right mandibular first premolar requiring endodontic therapy. After taking informed consent from the patient, the tooth was anaesthetized by 2% solution of lignocaine hydrochloride containing 1:80000 adrenaline and subsequently isolated with a rubber dam. Access cavity

* Corresponding author.

E-mail address: zksars@gmail.com (M. F. Azeez).

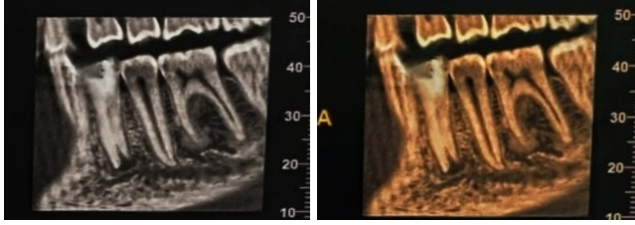


Figure 1: Preoperative intraoral radiograph of mandibular right 1st premolar showing two roots and periapical radiolucency (CBCT)

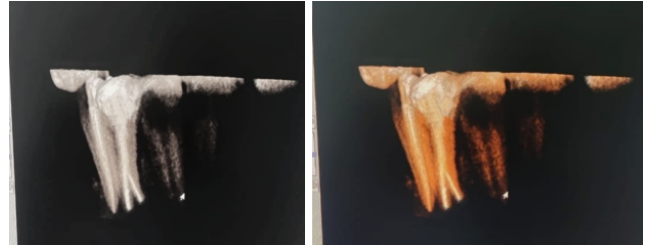


Figure 4: Radiograph of the mandibular right 1st premolar (Post-operative CBCT)

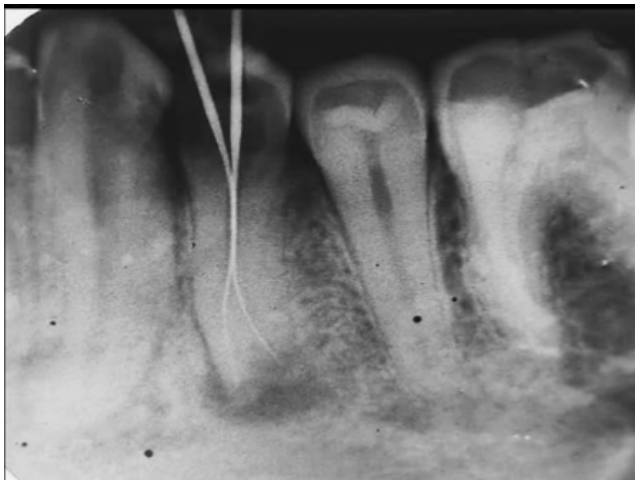


Figure 2: Radiograph of mandibular right 1st premolar (Working length)

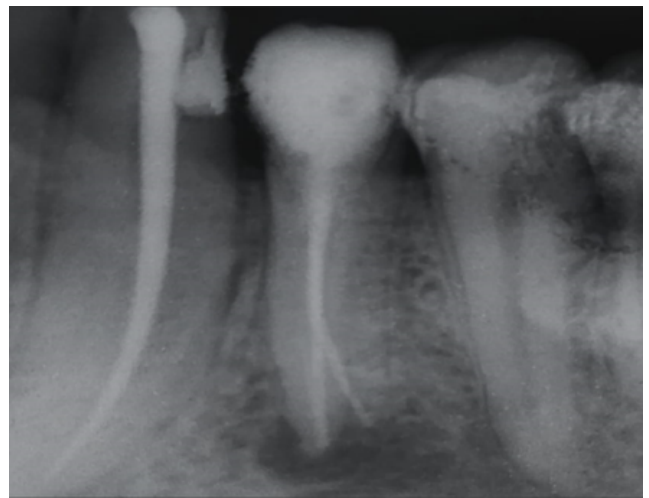


Figure 5: Periapical healing after 6 months

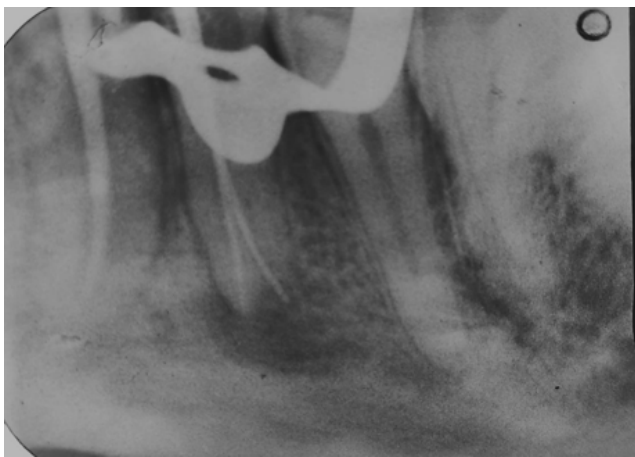

Figure 3: Radiograph of right mandibular 1st premolar (Master cone)

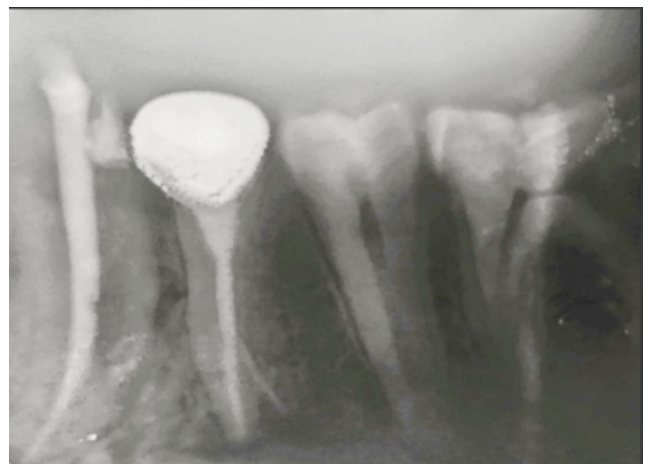


Figure 6: Crown restoration

was prepared with Endo Access bur and Endo Z bur with a high speed arotor handpiece. After complete deroofting of pulp chamber; the pulp chamber floor was thoroughly inspected to locate root canal orifices using DG 16 explorer.

First a #10K file inserted in buccal canal, the next #10K file was pre-curved and inserted in a distolingual direction to traverse the canal bifurcation into the second canal. Working length was taken using an electronic apex locator (J.MORITA- DENTA PORT ZX) and an IOPA radiograph was also taken to confirm the presence of a single coronal canal bifurcating into two separate canals in apical region (Figure 2).

Biomechanical preparation was done with protaper rotary instrument upto # 25/04 file. Irrigation procedure was carried out with 5.25% NaOCl and 17% EDTA. All canals were dried with sterile paper points and filled with calcium hydroxide (Ultracal) paste using Lentulo spiral (Dentsply Maillefer) size 25. The access chamber was sealed with Cavit (3M ESPE) and the patient was recalled after two weeks.

The patient was totally asymptomatic in second appointment, so after rubber dam isolation, Cavit was removed and calcium hydroxide was flushed from the canals using saline irrigation. Canals were dried using sterile paper points and gutta-percha master cones corresponding to the size of master apical file were inserted to the full working length and apical tug back was confirmed (Figure 3). Obturation was done using single cone technique with buccal canal first followed by lingual canal using AH plus sealer. The tooth was restored with composite resin (Figure 4).

2.1. Follow up examination

The follow up radiographs revealed remarkable reduction in the periapical pathology at 6 month (Figure 5) and nearly complete resolution of periapical pathology at 12 month follow up and the tooth was finally restored (Figure 6) with all-ceramic crown.

3. Discussion

The possibility of variations in root canal morphology must be considered before root canal treatment.¹ For the successful endodontic treatment anatomical variations, especially VERTUCCI type V root canal configuration, which is not very common in premolars should be kept in mind because canal preparation and obturation in such cases are challenging and inability to achieve this, can lead to treatment failure.

Proper and accurate interpretation of radiographs taken at different angulations, using paralleling technique are crucial for proper diagnosis of presence of number of roots and root canals existing in the tooth. Miyoshi et al concluded the presence of some variation in canal configuration if

the middle-root diameter appears equal or greater than the coronal diameter in the preoperative radiograph.⁵ Yoshioka et al, indicated the sudden narrowing of the canal system on a parallel radiograph is suggestive of multiple canals.^{6,7}

Bio-mechanical preparation of the root canals is done with rotary files because of its certain advantages over hand files like excellent flexibility, lower incidence of apical transportation and superior fracture resistance.⁸

Intracanal dressing in the form of calcium hydroxide was given in between the appointments. Calcium hydroxide was chosen due to its highly alkaline nature and release of hydroxyl ions thus making it highly efficient antibacterial agent.^{9,10} It can also be easily flushed off from the canals (more than 80%) thus not hampering the seal of root canal sealer with root canal wall.

Obturation was done with single cone technique, first buccal canal followed by lingual canal using AH plus sealer. Endodontic success largely depends on the post-op restoration, which if not done thoroughly can lead to microleakage and ultimately treatment failure. In this case composite resin restoration was done immediately after obturation, followed by full crown.

4. Conclusion

A proper knowledge of root canal anatomy promotes successful endodontic treatment. This case report describes the conservative management of mandibular first premolar with VERTUCCI type V root canal configuration which was diagnosed, treated and followed up till nearly complete resolution of periapical pathology at 12 months. Such type of cases with complex anatomy of the root canal can be successfully managed if the clinician has thorough knowledge of root canals.

5. Author Contribution

All authors have contributed significantly and are in agreement with the manuscript.

6. Informed Consent

Informed consent was obtained from patient in the study.

7. Source of Funding

The author have no source of funding and other support to declare.

8. Conflict of Interest

The author has no conflicts of interest to declare.

9. Acknowledgement

First, I would like to express a token of thanks to my institute (Faculty of Dental Sciences, BHU) for providing

me such a supportive and emerging environment. I would like to express my special thanks of gratitude to my Guide professor “Dr. Neelam mittal” and my senior “Dr. Shelly sharma” who helped me in completing my case report. I came to know about so many new things during publishing it. I am really thankful to them.

References

1. Ingle JL. A standardized endodontic technique utilizing newly designed instruments and filling materials. *Oral Surg Oral Med Oral Pathol.* 1961;14:83–91. doi:10.1016/0030-4220(61)90477-7.
2. Slowey RR. Root canal anatomy. Road map to successful endodontics. *Dent Clin North Am.* 1979;23(4):555–73.
3. Vertucci FJ. Root canal morphology and its relationship to endodontic procedures. *Endod Top.* 2005;10(1):3–29.
4. Mittal N, Kumar T, Parashar V. Endodontic Management of Mandibular Second Premolar with Type-III Vertucci: A Rare Case. *J Clin Diagn Res.* 2020;14(4):5–6. doi:10.7860/JCDR/2020/42484.13625.
5. Rödig T, Hülsmann M. Diagnosis and root canal treatment of a mandibular second premolar with three root canals. *Int Endod J.* 2003;36(12):912–9.
6. Yoshioka T, Villegas JC, Kobayashi C, Suda H. Radiographic evaluation of root canal multiplicity in mandibular first premolars. *J Endod.* 2004;30(2):73–4.
7. Sert S, Bayirli GS. Evaluation of the root canal configurations of the mandibular and maxillary permanent teeth by gender in the Turkish population. *J Endod.* 2004;30(6):391–8.
8. Bahrololoomi Z, Tabrizzadeh M, Salmani L. In Vitro Comparison of Instrumentation Time and Cleaning Capacity between Rotary and Manual Preparation Techniques in Primary Anterior Teeth. *J Dent, Tehran Univ Med Sci.* 2007;4(2):59–62.
9. Kim D, Kim E. Antimicrobial effect of calcium hydroxide as an intracanal medicament in root canal treatment: a literature review - Part I. In vitro studies. *Restor Dent Endod.* 2014;39(4):241–52.
10. Mittal N, Tomer A, Srivastava A. Treatment Of Mandibular First Premolar With Type IV Canal By Intentional Replantation. *J Conserv Dent.* 2000;3(2):81–5.

Author biography

Neelam Mittal, Senior Resident

Mohd Faisal Azeez, Junior Resident

Shelly Sharma, Senior Resident

Cite this article: Mittal N, Azeez MF, Sharma S. Non-surgical management of mandibular first premolar with vertucci type v root canal configuration: A case report. *IP Indian J Conserv Endod* 2024;9(3):146-149.