



## Case Report

# Direct pulp capping with bioactive materials – A case series

Paromita Mazumdar<sup>1</sup>, Deepshikha Chowdhury<sup>1,\*</sup>, Saikat Chatterjee<sup>1</sup>, Niladri Maiti<sup>2</sup>

<sup>1</sup>Dept. of Conservative Dentistry and Endodontics, Guru Nanak Institute of Dental Sciences and Research, Panihati, Kolkata, West Bengal, India

<sup>2</sup>Dept. of Dentistry, Jagannath Gupta Institute of Medical Sciences, Kolkata, West Bengal, India



### ARTICLE INFO

#### Article history:

Received 23-04-2020

Accepted 25-04-2020

Available online 25-05-2020

#### Keywords:

Activa Bioactive Composite resin

Direct pulp capping

Mineral Trioxide Aggregate

### ABSTRACT

The case series describes the use of Mineral Trioxide Aggregate (MTA) and a bioactive composite resin as a direct pulp capping agent after small pulpal exposure during caries excavation in permanent molars. After clinical examination, pulp sensibility with cold test and radiographic examinations in both cases, the teeth were diagnosed with reversible pulpitis. Caries removal was done and MTA was placed in patient 1 and the bioactive composite resin material was placed in patient 2 followed by composite resin restoration. At 1 week follow-up, patient's spontaneous symptoms had resolved in both the cases. Six months follow-up demonstrated maintenance of pulp vitality, clinical function, as well as the absence of pain/tenderness to percussion/palpation/cold sensitivity tests; periapical radiograph showed normal periodontium. These favourable results indicate that both Mineral Trioxide Aggregate and a bioactive composite resin can be successfully used as direct pulp capping agents.

© 2020 Published by Innovative Publication. This is an open access article under the CC BY-NC-ND license (<https://creativecommons.org/licenses/by/4.0/>)

## 1. Introduction

Direct pulp capping attempts healing of exposed pulp which is reversibly damaged by stimulating the formation of dentin bridge, thereby restoring the structure and function of the pulp-dentin complex.<sup>1</sup>

Pulp exposure during caries excavation can be challenging for the clinicians. Diagnosing the pulpal condition is necessary prior to treatment planning. When a tooth is diagnosed with reversible pulpitis, direct or indirect pulp capping maybe the treatment of choices depending upon several factors such as the presence or absence of a layer of dentin over the pulp, the area of exposure, the nature of hemostasis etc. Earlier, an exposed pulp was considered to be a doomed organ. However, with the introduction of calcium hydroxide in dentistry, pulp capping has proven to be effective in preserving the vitality of the pulp. Success rates range from 30 to 85 percent in two- to 10-year retrospective studies.<sup>2,3</sup>

Although calcium hydroxide has been used over the ages as a direct pulp capping material, long term studies have shown results to be unpredictable. One of the main disadvantage of calcium hydroxide is the formation of tunnel defects within the newly formed dentin bridge thereby creating a pathway for microbial invasion.

Mineral trioxide aggregate (MTA) is a bioactive silicate cement that has shown effective hard tissue formation by recruiting growth factors, thereby exerting an organising influence over the odontoblasts.<sup>4,5</sup>

Activa bioactive composite resin was introduced in 2015 by Pulpdent, USA. It is a composite resin that sets by dual cure technology. Manufacturer's claim that they have an "ionic shock absorbing matrix" consisting of diurethane methacrylate and modified polyacrylic acid, amorphous silica and modified polyacrylic acid. It releases and recharges calcium, phosphate and fluoride ions. The ionic interaction binds the resin to the minerals in the tooth, forming a strong resin-hydroxyapatite complex and a positive seal against microleakage.<sup>6</sup>

\* Corresponding author.

E-mail address: [deepshikha033@gmail.com](mailto:deepshikha033@gmail.com) (D. Chowdhury).

The case series describes the use of mineral trioxide aggregate and Activa bioactive composite resin as direct pulp capping agents.

## 2. Patient I

A female patient, aged 23 years, reported to the Department of Conservative Dentistry and Endodontics with the chief complaint of sensitivity in the lower left back teeth region for the last two weeks. The patient experienced sharp pain on consumption of cold beverages which lasted momentarily and was relieved a few seconds later. On clinical examination, occlusal caries in relation to tooth number 36 was observed. Clinically, the overall depth of the cavity was 2mm with the deepest portion having a depth of greater than 3.5mm in the central pit region (Figure 1 A). Intra oral periapical radiograph revealed radiolucency on the occlusal aspect of 36 involving enamel, dentin and approaching the mesial pulp horn. (Figure 1E) 36 responded positively to pulp sensitivity test with ethyl chloride spray (Endo frost, Coltene), thus indicating that the tooth was vital. The medical history of the patient was non-contributory. 36 was diagnosed with reversible pulpitis.

Since there was no obvious pulp involvement, caries excavation followed by vital pulp therapy was planned in relation to 36. After explaining the treatment procedure and obtaining signed informed consent from the patient, caries excavation was initiated with #6 Tungsten Carbide bur and a high-speed handpiece with water coolant under rubber dam isolation. After removal of hard carious lesion, the remaining soft infected dentin was removed with a spoon excavator. After caries excavation a pin point pulpal exposure was observed (Figure 1B). The cavity was cleaned with 0.9% saline, dried with sterile cotton pellets, and haemostasis was achieved in 2-3 minutes using 3% sodium hypochlorite (Prime dental). On the site of pulpal exposure, 1.5–2 mm thick ProRoot MTA White (Dentsply DeTrey GmbH, Konstanz, Germany) was placed (Figure 1C), which was covered with 2-mm-thick layer of resin modified glass ionomer (GC Fuji II LC, Fuji Corporation, Japan) base. Finally, the tooth was restored using nanohybrid composite resin (Filtek Z250 XT, 3M ESPE) on the same day. (Figure 1D)

The patient was recalled after twenty four hours; one month three and six months for clinical and radiographic follow up (Table 1, Figure 1 F, G, H).

## Patient II

A 27 year old male patient had reported to the department with chief the complaint of sensitivity in the upper left back teeth region for fifteen days. The patient experienced momentary pain lasting for 2-3 seconds on having cold beverages which was relieved once the stimulus was removed. On clinical examination, proximal caries with loss of tooth structure was seen on the mesial surface of 26 with the deepest portion having a probing depth of

greater than 3mm in the axial wall (Figure 2 A). Intra oral periapical radiographic examination revealed radiolucency on the mesial aspect of 26 involving enamel, dentin and approaching the pulp (Figure 2E). 26 responded positively to pulp sensitivity test with ethyl chloride spray (Endo frost, Coltene), thus indicating that the tooth was vital. The medical history of the patient was non-contributory. 26 was diagnosed with reversible pulpitis.

Since there was no direct pulpal involvement, caries excavation was planned followed by vital pulp therapy in relation to 26 followed by extraction of 25 in the subsequent visits. However, since the patient's source of chief complaint was 26, he desired to get it treated prior to the extraction of 25. The patient was advised prosthodontic rehabilitation of 25 based on the response of tooth number 26.

The treatment plan was explained to the patient and signed informed consent was obtained. Soft tissue diode LASER (810 ±10 nm, pulse length 50 microsecond to 30 seconds, 0.1-7 Watt ) was used to remove overgrown gingival tissue in order to prepare the gingival seat. Rubber dam was used to obtain a fluid tight seal then after for the restorative procedure.

Caries excavation was initiated with an air rotor handpiece and a # 4 round TC bur. The carious layer was removed and pin point bleeding was observed from the floor of the cavity (Figure 2B). Haemostasis was achieved within 2 minutes using an autoclaved cotton pellet soaked in 3 % Sodium hypochlorite

ACTIVA™ BioACTIVE-RESTORATIVE™ (A3.5 shade) was dispensed from the auto mix syringe supplied by the manufacturer and was applied to the floor of the cavity with a thickness of about 0.5mm and then light cured for 20secs as per the manufacturer's instruction. Overall, sufficient peripheral enamel was available along the cavity margins. The walls of the cavity were etched with 37% ortho phosphoric acid gel etchant for 15 seconds and then rinsed for another 15 seconds and dried with compressed oil free air.

A fifth-generation universal bonding agent was applied to the walls of the cavity and light cured for 20 seconds as per the manufacturer's instruction. The remaining part of the cavity was restored with a nanohybrid composite resin and light cured for 40 seconds as per the manufacturer's instruction. As 25 was a root stump, contouring of the restoration was done by initial cure with a metal band followed by final curing with mylar strip. (Figure 2C, D)

Post-operative radiograph was taken and periodic follow-ups were carried out at twenty four hours; one month three, six months (Figure 2F,G,H).

Patients were recalled after 24hrs, 1 month, 6 months and 1 year for clinical and radiographic follow up. Clinical assessment was done to assess sensitivity, pain, swelling, mobility, tenderness on percussion, formation of sinus tract, pulp sensitivity tests ( cold test and electric pulp

**Table 1:** Post-operative clinical follow up criteria

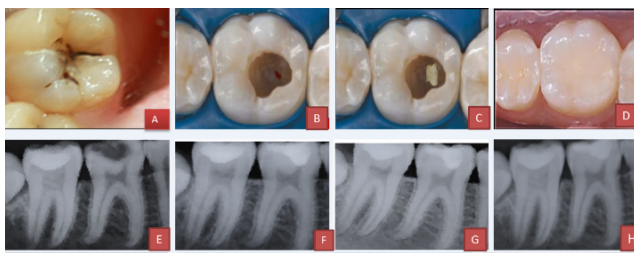
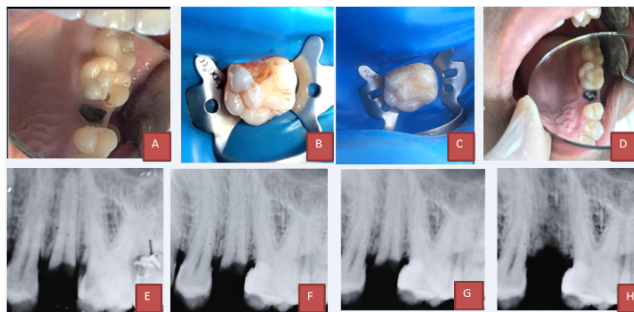
Tooth involved	Site of exposure	Sensitivity	Post – operative observations at 24 hrs , 1 month , 6 months, 1 year						Cold test	EPT	Follow - up period
			Pain	Swelling	Mobility	Tenderness on percussion	Sinus tract				
26	Mesial pulp horn	P* at 24 hrs and then subsided	A	A	A	A	A	A	Response similar to healthy contralateral tooth.‡	constant throughout the follow up	1 year
36	Mesial pulp horn	A†	A	A	A	A	A	A	response similar to healthy contralateral tooth.	constant throughout the follow up	1 year

\*P : present ,

†A: absent

‡At first 24 hrs , showed exaggerated response in response to healthy contralateral tooth but elicited constant response similar to healthy contralateral

test)(Table 1 ).

**Fig. 1:** A) Preoperative clinical picture of tooth 36. B) Pinpoint exposure found C) Layer of MTA placed on the exposure site. D) Tooth restored with RMGIC . E) Final restoration with composite resin**Fig. 2:** A) Preoperative intraoral periapical (IOPA) radiograph of 36. B) Post operative (IOPA) radiograph of 36. C) 1 month follow up IOPA radiograph of 36. D) 6 months follow up IOPA radiograph of 36. E) 1 year follow up IOPA radiograph of 36.

### 3. Discussion

Vital pulp therapy is a recommended procedure for all teeth diagnosed with reversible pulpitis or partially inflamed pulps.

Cold test was performed in both the cases, as it is a more definite pulp sensibility test compared to Electric Pulp Testing. Also chances of false negative or false positive

results are minimum compared to EPT. Also the history of the patient, clinical presentation along with cold test were corroborated to come to a definite diagnosis.

In 1756, gold foil was used for the first pulp capping procedure by Phillip Pfaff. However, the success of the procedure depends upon the circumstances under which it is performed such as site and size of exposure, the time required for hemostasis and the ability to sterilise the area and to place the restorative material effectively over the exposure site.

There are several materials that have been used as direct pulp capping agents over the years such as calcium hydroxide, zinc oxide eugenol cement, corticosteroids and antibiotics like hydrocortisone, polycarboxylate cement, collagen , growth factors such as platelet rich fibrin and concentrate growth factors, glass ionomer cement, mineral trioxide aggregate, biodentine, theracal, however the standard material for pulp capping of normal vital pulp tissue is calcium hydroxide which has an anti-bacterial effect because of its high pH.<sup>7-9</sup>

Calcium hydroxide has been proven to induce hard tissue proliferation. However, inherent disadvantages such as high solubility, poor adhesion and tunnel defects<sup>10</sup> have resulted in a quest for better pulp capping materials.

MTA was introduced by Torabinejad in early 1993. When MTA is mixed, tricalcium silicate reacts with water to form calcium silicate hydrogel which ultimately releases calcium hydroxide. There is recruitment of cytokines and growth factors (Vascular Endothelial Growth Factor)<sup>11</sup> which signal the odontoblasts to lay down reparative dentin. The material has a sandy texture, small particle size and good sealing ability.<sup>12</sup>

Bioactive glasses (BAGs) are relatively new materials in dentistry. They react with aqueous solutions and produce a carbonated apatite layer.<sup>13</sup>

ACTIVA stimulates mineral apatite formation by ionic interaction with the calcium and phosphate in the teeth. ACTIVA BioACTIVE-RESTORATIVE, when tested in vitro for microleakage without a bonding agent, compares favorably with leading composites tested with a

bonding agent (Scotchbond Universal Adhesive, 3M ESPE). ACTIVA bioactive restorative material has been used in the study as it has an ionic shock absorbing resin matrix with fluoride releasing properties. It bonds to the tooth structure chemically and has satisfactory handling properties. The material sets on exposure to curing lights (470-500 nm), making it possible to restore the tooth in the same visit, thus reducing chairside time too. Thus, this material was chosen in this study as a direct pulp capping agent.<sup>14</sup>

#### 4. Conclusion

Direct pulp capping with MTA which is commonly used material for direct pulp capping and recently introduced ACTIVA Bioactive restorative material has shown a favorable outcome on 1 year follow up. The vitality of the tooth in question was preserved and the patient was asymptomatic.

#### 5. Source of Funding

None.

#### 6. Conflict of Interest

None.

#### References

1. Asgary S, Ahmadyar M. W Vital pulp therapy using calcium-enriched mixture: An evidence-based review. *J Conserv Dent.* 2013;16(2):92–8.
2. Hørsted P, Søndergaard B, Thylstrup A, Attar KE, Fejerskov O. A retrospective study of direct pulp capping with calcium hydroxide compounds. *Endod Dent Traumatol.* 1985;1(1):29–34.
3. HAHN C, LIEWEHR F. Relationships between Caries Bacteria, Host Responses, and Clinical Signs and Symptoms of Pulpitis. *J Endod.* 2007;33(3):213–9.
4. WEAndelin, Shabahang S, Wright K, Torabinejad M. Identification of Hard Tissue After Experimental Pulp Capping Using Dentin Sialoprotein (DSP) as a Marker. *J Endod.* 2003;29(10):646–50.
5. Bogen G, Kim JS, K L. Bakland Direct pulp capping with Mineral Trioxide Aggregate: An Observational Study. *J Am Dent Assoc.* 2008;139:305–15.
6. Activa Bioactive Restorative Material;.
7. Barthel CR, Levin LG, Reisner HM, Trope M. TNF-alpha release in monocytes after exposure to calcium hydroxide treated Escherichia coli LPS. *J Int Endod.* 1997;30:155–9.
8. Ferracane J. *Materials in Dentistry, Principles and Applications.* Philadelphia: Lippincott, Williams & Wilkins; 2001.
9. Kitasako Y, Ikeda M, Tagami J. Pulpal responses to bacterial contamination following dentin bridging beneath hard-setting calcium hydroxide and self-etching adhesive resin system. *J Dent Traumatol.* 2008;24(2):201–6.
10. Camilleri J, Ford TRP. Mineral trioxide aggregate: a review of the constituents and biological properties of the material. *Int Endod J.* 2006;39(10):747–54.
11. Camilleri J, Montesin FE, Silvio LD, Ford TRP. The chemical constitution and biocompatibility of accelerated Portland cement for endodontic use. *Int Endod J.* 2005;38(11):834–42.
12. Qureshi A, Nandakumar, Pratapkumar S. Recent advances in pulp capping materials: an overview. *J Clin Diagn Res.* 2014;8(1):316–21.
13. Jalan A, Warhadpande M, Dakshindas D. A comparison of human dental pulp response to calcium hydroxide and Biodentine as direct pulp-capping agents. *J Conserv Dent.* 2017;20(2):129–33.
14. Roulet JF, Hussein H, Abdulhameed NF, Shen C. In vitro wear of two bioactive composites and a glass ionomer cement. *Dtsch Zahnärztl Z Int.* 2019;1:24–30.

#### Author biography

**Paromita Mazumdar** HOD

**Deepshikha Chowdhury** Post Graduate Trainee

**Saikat Chatterjee** Post Graduate Trainee

**Niladri Maiti** HOD

**Cite this article:** Mazumdar P, Chowdhury D, Chatterjee S, Maiti N. **Direct pulp capping with bioactive materials – A case series.** *IP Indian J Conserv Endod* 2020;5(2):79-82.