



Case Report

Endodontic management of radix entomolaris with middle mesial canal –A case report

Ipsita Pathak^{1,*}, Nazia Ali¹, Praveen Singh Samant¹, Raju Chauhan¹

¹Dept. of Conservative Dentistry & Endodontics, Saraswati Dental College, Lucknow, Uttar Pradesh, India



ARTICLE INFO

Article history:

Received 25-08-2020

Accepted 03-09-2020

Available online 07-09-2020

Keywords:

Anatomical variation

Radix entomolaris

Permanent mandibular first molar

Middle mesial canal

Root canal therapy

ABSTRACT

Mandibular molars exhibit variations in its internal anatomy; one among those is the presence of an extra canal in the mesial root called as middle mesial (MM) canal. Variation in the number of roots and canal morphology is not scarce. Presence of an additional root when found disto-lingually called as Radix entomolaris. This case report describes the treatment of chronic apical periodontitis with unusual morphology of mandibular first molars in 34 years old male patient. The treatment strategy included root canal therapy without the aid of any magnification devices.

© 2020 Published by Innovative Publication. This is an open access article under the CC BY-NC license (<https://creativecommons.org/licenses/by-nc/4.0/>)

1. Introduction

The primary aim of endodontic therapy is total debridement of pulp space and obturates the root canal system to prevent re-infection. The understanding of the variations of unusual root canal morphology can thus contribute to the successful outcome of the root canal treatment.^{1,2}

Different types of variations are found in mandibular first molar like numerous canals in both mesial and distal root, extra root as in radix entomolaris, radix paramolaris, C-shaped canal anatomy, etc.^{3–7} The incidence of middle mesial canals ranges between 2.07% - 13.3%, and incidence of radix entomolaris in Indian population are <5%.⁷ It is of foremost importance to locate all the root canals and scrupulous mechanical and chemical cleansing of the entire pulp space, followed by three-dimensional obturation with an inert filling material.⁸

2. Case Report

A 34 year old male patient came to Department of Conservative Dentistry & Endodontics, Saraswati Dental

College, with non-contributory medical history reported with a chief complaint of intermittent pain in the lower right back teeth region since 1 month. The pain used to intensify by thermal and physical stimuli. On clinical examination, a deep proximal caries was seen on the first molar, and the tooth was tender on percussion. The electric pulp testing revealed a delayed response.

On radiographic examination, the carious lesion involved the pulp with no apical changes. The case was diagnosed as chronic apical periodontitis in relation to right mandibular first molar (#46) (Figure 1). Based on clinical and radiographic interpretation, it was decided to perform endodontic therapy.

The tooth was anaesthetized followed by rubber dam isolation. The pulp chamber was opened using a large round bur and the access cavity was refined using EZ bur (Dentsply). Exploring the orifices was done with a sharp endodontic explorer a catch was found between the main mesial canals. A small instrument (#6 and 8 K File, Dentsply) was inserted into the canal using watch winding motion and slowly advanced into the root canal. Pulp extirpation was done, after checking the patency of all the five canals, with # 10K file. Totally five

* Corresponding author.

E-mail address: dripsitapathak@gmail.com (I. Pathak).

distinct orifices, three on the mesial root and two on the distal roots were detected (Figure 2). The working length (by # 15 K file) radiograph confirmed five distinct canal orifices. The radiograph showed the presence of an independent MM canal and a radix entomolaris (Figure 3). Biomechanical preparation was performed using ProTaper Gold File system (Dentsply) with crown-down technique. During the preparation, 5% sodium hypochlorite solution and 17% EDTA (Ethylenediaminetetraacetic acid) used as irrigant alternatively after every instrument change. Apical Preparation was done till F2 size for all the canals, after completion of chemo-mechanical preparation closed dressing was given and patient was reappointed after three days for obturation. In follow-up appointment as the tooth was asymptomatic, master cone radiograph was taken (Figure 4). The canals were dried using paper point. Obturation was done using corresponding ProTaper F2 cones with zinc oxide eugenol sealer. Radiograph was taken after obturation (Figure 5). The access cavity was sealed with a permanent restoration.

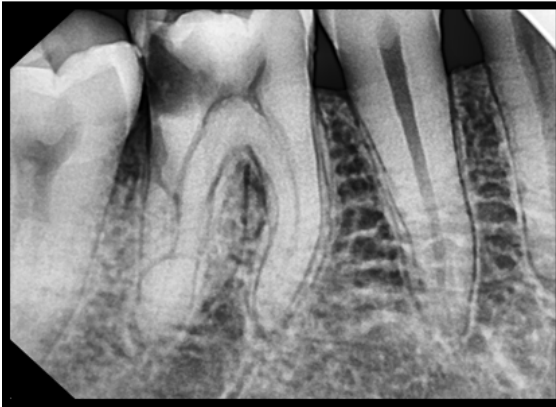


Fig. 1: Preoperative radiograph of #46 showing deep distal caries exposing the pulp.

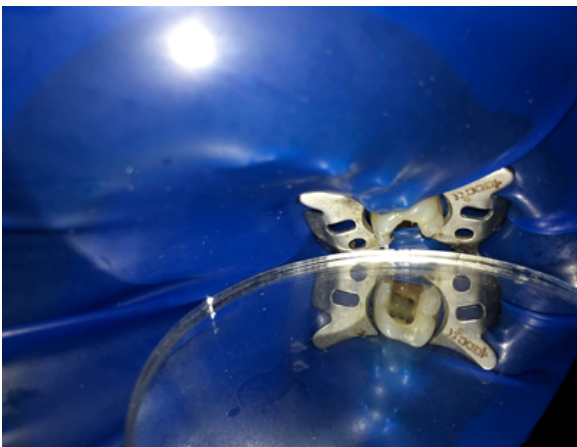

Fig. 2: Picture showing access cavity of #46 with five distinct canal

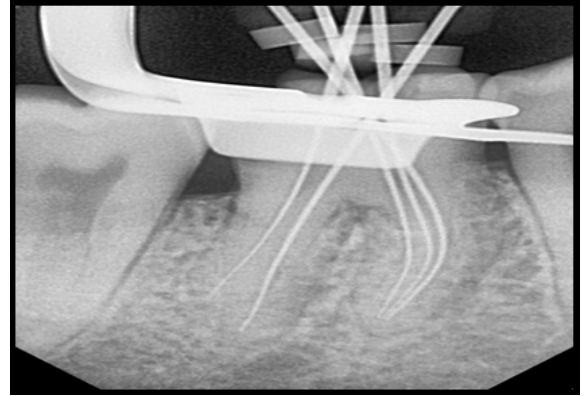


Fig. 3: Working length determination radiograph of #46

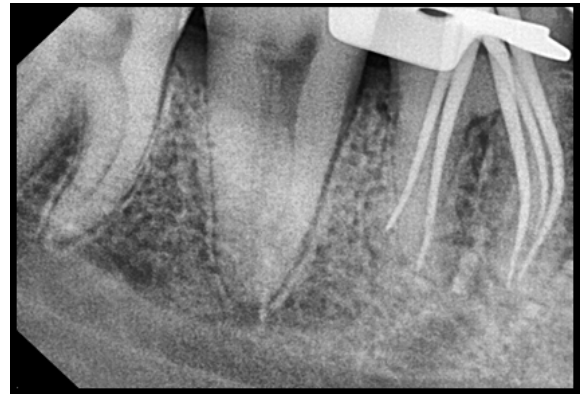

Fig. 4: Master cone radiograph

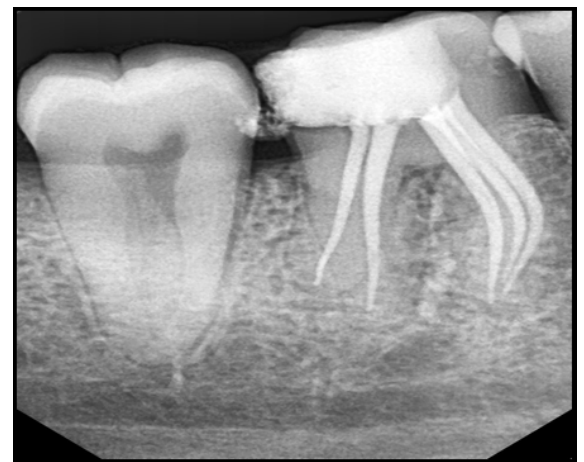

Fig. 5: Post-obturation radiographs showing radix entomolaris & the middle mesial canal

3. Discussion

This case explained the importance of tooth anatomy and morphology. Anatomical variations are an accepted features of permanent mandibular molars.⁸ Knowledge about the internal anatomy and after completely deroofting the pulp chamber for proper visualization needed for the successful root canal treatment. Careful troughing with the gate-glidden drill of the mesio-lingual groove up to 2 mm toward the mesio-lingual direction is the significant factor in detection of the MM canals. It should be performed in a way where GG drill or round bur directed against from furcational area to avoid the procedural errors.⁹ Clinicians need to check the mesial root for a third canal that may be displaced or located within the mesiobuccal and mesio-lingual canals.^{10,11} Main pulp chamber usually separated by mesial canal orifices which are connected by a developmental groove. A bur is used to remove dentinal protuberance which separates the entrance to the mesiobuccal and mesiolingual canals. An explorer is used to explore through the groove which are connecting the both mesiobuccal and mesiolingual canal to search for any depression. Then the groove can be troughed with either ultrasonic tips or GG-drill, at the expense of the mesial aspect, until a #10 K file can negotiate the canal space.⁹

Mandibular molars can have an additional root known as radix entomolaris which is located disto to mesio lingually from the main orifices.¹ Presence of an extra cusp or more prominent distolingual lobe in combination with a cervical prominence can indicate the presence of an additional root. A radiograph should be taken in multiple angular projection with different types of files inserted like K file in distobuccal canal and H file in disto-lingual canal will assure about the additional root or extra canals. A straight line access, initial root canal exploration with small files (#10 K) together with the working length of root canal and curvature determination of the root canal by the pre-curve files and the creation of a glide path before preparation are step-by-step actions that should be followed to avoid procedural errors.¹² These type of anatomical variations should be approached with an angled radiograph to an addition to periapical radiograph, digital imaging like CBCT image for the understanding of tooth morphology. In this case report, all the five canals were methodically instrumented, debrided and obturated upto the level of the apical terminus. Early diagnosis with a proper clinical approach will avoid procedural errors during endodontic treatment.

4. Conclusion

A major cause of the failure of root canal therapy is an inability to localize orifices and treat all of the canals of the root canal system. The risk of missing anatomy during root canal treatment is high because of the complexity of the root canal system.⁸ This study shows that if the chances of long-term success with root canal therapy are to be increased

more time should be spent exploring the floor of the pulp chamber of mandibular first molars to discover, instrument and fill any abnormal variables that is present.^{7,13}

5. Source of Funding

None.

6. Conflict of Interest

None.

References

1. Calberson FL, Moor RJD, Deroose CA. The Radix Entomolaris and Paramolaris: Clinical Approach in Endodontics. *J Endod.* 2007;33(1):58–63.
2. Ali N, Deschenes RJ, Tordik PA, Hicks ML, Fouad AF. Middle Mesial Canals in Mandibular Molars: Incidence and Related Factors. *J Endod.* 2015;41(1):28–32.
3. Hussein M, Abdulgani A, Slameh M. Clinical approach of a tooth with radix entomolaris and five root canals. *J Dent Med Sci.* 2015;14:67–72.
4. Weller RN, Niemczyk S, Kim S. Incidence and position of the canal isthmus. Part 1. Mesiobuccal root of the maxillary first molar. *J Endod.* 1995;21(7):380–3.
5. Pomeranz HH, Eidelman DL, Goldberg MG. Treatment considerations of the middle mesial canal of mandibular first and second molars. *J Endod.* 1981;7(12):565–8.
6. Parolia A, Kundabala M, Thomas MS, Mohan M, Joshi N. Three rooted, four canalled mandibular first molar (radix entomolaris) Kathmandu. *Univ Med J.* 2009;7:289–92.
7. Vertucci FJ, Willaimrg. Root canal anatomy of mandibular first molar. *JNJ Dent Assoc.* 1974;45:27–8.
8. Singh S, Mirdha N, Arora. A Rare Case Report Series of Radix Entomolaris With Middle Mesial Canal in Permanent Mandibular First Molar. 2018;7:9411–4.
9. Fabra-Campos H. Three canals in the mesial root of mandibular first permanent molars: a clinical study. *Int Endod J.* 1989;22(1):39–43.
10. Mortman RE, Ahn S. Mandibular first molars with three mesial canals. *Gen Dent.* 2003;51:549–51.
11. von Arx T. Frequency and type of canal isthmuses in first molars detected by endoscopic inspection during periradicular surgery. *Int Endod J.* 2005;38(3):160–8.
12. Vemuri S, Kumar PR, Ballullaya SV. Variable permanent mandibular first molar: Review of literature. *J Conserv Dent.* 2013;16(2):99–110.
13. Burns RC, Herbranson EJ. Tooth morphology and access cavity preparation. In: Cohen S, Burns RC, editors. *Pathways of the pulp.* Elsevier Mosby; 2002. p. 73–229.

Author biography

Ipsita Pathak Student

Nazia Ali Student

Praveen Singh Samant Professor

Raju Chauhan Professor

Cite this article: Pathak I, Ali N, Samant PS, Chauhan R. **Endodontic management of radix entomolaris with middle mesial canal –A case report.** *IP Indian J Conserv Endod* 2020;5(3):147-149.