



Case Report

Management of traumatic dental injury in maxillary anterior teeth - A case report

Rishu Mittal^{1,*}, Poonam Bogra¹, Saurabh Gupta¹

¹Dept. of Conservative Dentistry & Endodontics, J.N Kapoor DAV (C) Dental College, Yamunanagar, Haryana, India



ARTICLE INFO

Article history:

Received 20-01-2021

Accepted 10-02-2021

Available online 16-03-2021

Keywords:

Crown fracture

Traumatic dental injuries

Permanent tooth

Fiber Post

ABSTRACT

This case report describes the clinical procedures involved in the treatment of a complicated fracture in the maxillary left central incisor in a 35-year-old female patient, due to accidental fall. After clinical and radiograph examination Ellis class III fracture was diagnosed. Endodontic treatment was decided to restore the complicated crown fracture with fiber post and core followed by Porcelain fused to metal crown. & the tooth was satisfactory both esthetically and functionally.

© This is an open access article distributed under the terms of the Creative Commons Attribution License (<https://creativecommons.org/licenses/by/4.0/>) which permits unrestricted use, distribution, and reproduction in any medium, provided the original author and source are credited.

1. Introduction

Most common traumatic dental injury affecting permanent teeth is the uncomplicated and complicated crown fracture.¹ Most commonly affected teeth are the maxillary incisors, forming 96% of all crown fractures.² Children and adolescents usually suffer from traumatic injuries, with boys being affected more commonly than girls.³ Tooth fracture may cause emotional trauma to the children and adolescents as a result of missing tooth structure. The principal objective of the treatment in such cases is the rehabilitation of both esthetics and function.

Various treatment modalities are available for management of fractured anterior teeth. In cases where the teeth are severely fractured, endodontic treatment and placement of intracanal posts become necessary, before crown placement. In recent years, an alternative to prefabricated metal posts and cast posts for the restoration of endodontically treated teeth, have emerged with various types of fiber reinforced posts.⁴ The reinforced fiber used to construct an intracanal post offers superiorities over other systems, such as relative ease of manipulation, translucency, and resin composite crown reinforcement.⁵ The technology

evolution has enabled manufacturers today to provide fiber posts that besides offering superior aesthetics require less chair side time and have similar modulus of elasticity as that of dentin (which are the first qualities to be appreciated in comparison with metal or cast post) & are also radio opaque and available in a great variety of shapes.

This article reports such a case treated with Fiber Reinforced Post and Core for the restoration of traumatically fractured maxillary left permanent central incisor.

2. Case Report

A female patient of 35 years old reported to the Department of Conservative Dentistry and Endodontics, at J.N Kapoor DAV (C) Dental College, Yamunanagar with the complaint of fractured upper front teeth since last 1 yr after sustaining trauma due to accidental fall. On examination, there was no pain and swelling. Ellis class III fracture was diagnosed during intraoral examination & the loose fractured fragment (with the root length of 3mm) was removed. (Figure 1).

Radiolucency involving enamel, dentine, and pulp was seen on radiographic examination. Vitality test was negative. Tooth was non-vital. After examination and diagnosis, Endodontic treatment was decided to restore

* Corresponding author.

E-mail address: dr.rishumittal@gmail.com (R. Mittal).

the complicated crown fracture with fiber post and core followed by Porcelain fused to metal crown. Local Anesthesia was given. Access was gained with Tapered Fissure bur and Endo-z bur. An electronic apex locator was used to determine the working length and was confirmed with radiography. Bleeding was controlled with 3M Retraction paste. Orafill & cotton fibers were mixed and placed on the lingual side for the retraction of gingiva. Cleaning & Shaping of the root canal was done. During the biomechanical preparation Sodium hypochlorite (3%) and saline was used for irrigation. Final rinse with 2ml of 17% EDTA followed by saline and 2% Chlorhexidine. Paper points were used to dry the root canal and then obturated with Apexit sealer and laterally condensed with gutta-percha.

The post space was prepared and was extended beyond the fracture line with corresponding drills to receive the fiber reinforced post. The fiber post was checked for the fit. Size of the fiber post that was chosen was 1.5mm. Dual cure cement (RelyX U200) was used for post cementation. The catalyst and base components of material were mixed and applied following manufacturer's instruction. The post was seated and excess material removed before light curing. Core build up was done with composite (Filtek Z350 Xt). Tooth preparation was done w.r.t. 21 (Figure 2). Upper and lower elastomeric Impression was taken. PFM crown cementation was done (Figure 3).

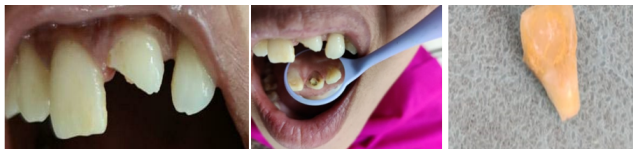


Fig. 1: Preoperative images

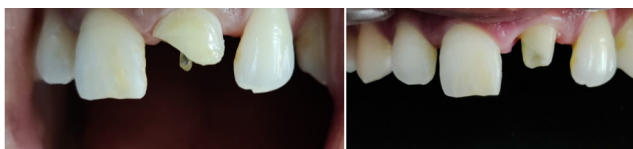

Fig. 2: Fiber post & core build up

3. Discussion

Restoration of endodontically treated teeth has always been an area of concern and the recent past has witnessed an implosion of interest in the field with regard to functional and esthetic problems. In the wake of changing treatment concepts, the material market for posts has undergone a complete makeover. Ranging from the era of wooden posts to metal posts and more recently, carbon fiber, glass fiber, and ceramic posts, the material and design options are infinite. In the last few years there has been an implosion

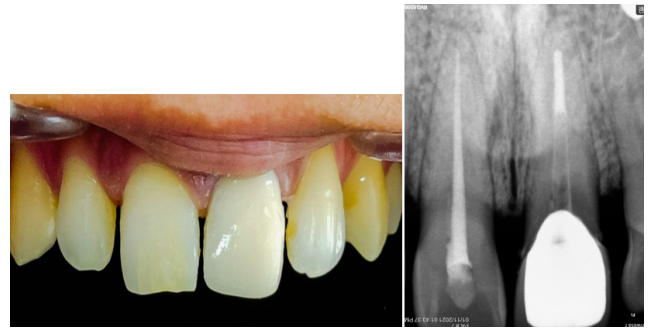

Fig. 3: Postoperative image & radiograph after crown cementation

of new materials, changing the trend toward prefabricated metal posts, resin-based composite cores, fiber reinforced resin-based composite posts and ceramic posts.

Traditionally cast posts have been used for a long time to restore complicated crown fracture. Depending on developments in adhesive dentistry resin-based fiber reinforced posts have been used in the restoration of maxillary anterior teeth.⁶ Fiber resin posts show similar hardness to dentin and exhibits greater durability than the metal posts. Having elastic modulus similar to dentin strengthens the remaining tooth structure and increases resistance to tooth fracture. Because of these advantages, fiber post was used in this case to restore the fractured teeth with composite resins.^{7,8} The potential problem regarding the original carbon fiber posts for postrestoration was the darkness of the material hampering the esthetics. More recent versions are white other types of fiber posts also are available, including quartz fiber, glass fiber, and silicon fiber posts. They are claimed to offer the same advantages as the carbon fiber posts, but with better esthetic's. Because they are newer, most fiber posts are relatively radiolucent and have different radiographic appearance than traditional posts.⁹ Fiber posts are ready to use whereas more time, extra clinic and laboratory time are required for the metal post.¹⁰ Current fiber posts are radiopaque and may also conduct the light for polymerization of resin-based luting cements. A light-transmitting post results in better polymerization of resin composites in the apical area of simulated root canals, as measured by hardness values.

It is generally accepted that bonding fiber posts to root canal dentin can improve the distribution of forces applied along the root, thereby decreasing the risk of root fracture and contributing to the reinforcement of the remaining tooth structure.

Reattachment was not done in this patient as the fractured fragment was not intact. Crown lengthening or orthodontic extrusions are more extensive and invasive procedures causing more discomfort and requiring longer healing period and were therefore not chosen.

Thus, advances in aesthetic materials have allowed dentistry to provide a cosmetic upgrade while restoring

defective teeth, treating disease and restoring comfort and function.

4. Conclusion

Excellent esthetic and functional results can be achieved with the use of a fiber-reinforced root canal post and composite material for the treatment of anterior traumatized teeth. Fiber post has better homogeneous tension distribution when loaded, than rigid metal or zirconium oxide ceramic posts. Fiber reinforced posts also possess advantageous optical properties over metal or metal oxide post systems. Therefore, a combined use of fiber posts provides satisfying esthetic results and improved mechanical properties.

5. Source of Funding

No financial support was received for the work within this manuscript.

6. Conflict of Interests

The author declares that they do not have any conflict of interests.

References

- Dietschi D, Jacoby T, Dietschi JM, Schatz JP. Treatment of traumatic injuries in the front teeth: Restorative aspects in crown fractures. *Pract Periodontics Aesthet Dent*. 2000;12:751-8.
- Goenka P, Marwah N, Dutta S. Biological approach for management of anterior tooth trauma: Triple case report. *J Indian Soc Pedod Prev Dent*. 2010;28(3):223-9. doi:10.4103/0970-4388.73791.
- Zerman N, Cavalleri G. Traumatic injuries to permanent incisors. *Endod Dent Traumatol*. 1993;9(2):61-4. doi:10.1111/j.1600-9657.1993.tb00661.x.
- Garoushi S, Vallittu PK, Lassila LV. Continuous and Short Fiber Reinforced Composite in Root Post-Core System of Severely Damaged Incisors. *Open Dent J*. 2009;3(1):36-41. doi:10.2174/1874210600903010036.
- Verma L, Passi S. Glass Fibre-Reinforced Composite Post and Core Used in Decayed Primary Anterior Teeth: A Case Report. *Case Rep Dent*. 2011;2011:864254. doi:10.1155/2011/864254.
- Kumar SC, Rao A, Sheila K, Reddy HG. Multidisciplinary Approach in Management of Fractured Central Incisor through Composite Plug Stabilization - A Case Report. *J Int Oral Health*. 2013;5:79-82.
- Cormier CJ, Burns DR, Moon P. In vitro comparison of the fracture resistance and failure mode of fiber, ceramic and conventional post systems at various stages of restoration. *J Prosthodont*. 2001;10:26-36.
- Hayashi M, Sugeta A, Takahashi Y, Imazato S, Ebisu S. Static and fatigue fracture resistances of pulpless teeth restored with post-cores. *Dent Mater*. 2008;24(9):1178-86. doi:10.1016/j.dental.2008.01.009.
- Schwartz RS, Robbins JW. Placement and Restoration of Endodontically Treated Teeth: A Literature Review journal of endodontics. *J Endod*. 2004;30(5):289-300. doi:10.1097/00004770-200405000-00001..
- Monticelli F, Grandini S, Goracci C, Ferrari M. Clinical behavior of translucent-fiber posts: A 2-year prospective study. *Int J Prosthodont*. 2003;16:593-6.

Author biography

Rishu Mittal, Post Graduate Student

Poonam Bogra, Professor and HOD

Saurabh Gupta, Professor

Cite this article: Mittal R, Bogra P, Gupta S. Management of traumatic dental injury in maxillary anterior teeth - A case report. *IP Indian J Conserv Endod* 2021;6(1):72-74.