

Content available at: <https://www.ipinnovative.com/open-access-journals>

IP Indian Journal of Conservative and Endodontics

Journal homepage: <https://www.ijce.in/>

Case Report

Root canal treatment in a maxillary first molar with seven root canals

Darla Satya Sanyasi Vinay Kumar^{1,*}, Saila Manisha², Bhargav Kambampati³,
Vijaykanth Kattamuri⁴, Sivaji Kavuri¹, Garapati Harshitha¹

¹Dept. of Conservative Dentistry & Endodontics, Anil Neerukonda institute of Dental Sciences, Visakhapatnam, Andhra Pradesh, India

²GITAM Dental College & Hospital, Visakhapatnam, Andhra Pradesh, India

³Dept. of Conservative Dentistry & Endodontics, Mamatha Dental College, Khammam, Telangan, India

⁴Dept. of Prosthodontics, Anil Neerukonda institute of Dental Sciences, Visakhapatnam, Andhra Pradesh, India



ARTICLE INFO

Article history:

Received 28-01-2022

Accepted 08-02-2022

Available online 31-03-2022

Keywords:

Seven root canals in a maxillary molar
Maxillary molar root canal
Root canal therapy
CBCT
Cone Beam Computed Tomography
Aberrant root canal morphology

ABSTRACT

Aberrations in root canal anatomy can often pose challenges during an endodontic treatment. Failure to obturate all the root canals holistically can lead to sure endodontic failure. Thorough knowledge of such root canals together with technicality can aid us surpass the hurdles posed during a root canal treatment. This case report illustrates a root canal therapy performed in a pulpally involved maxillary first molar with seven root canals.

This is an Open Access (OA) journal, and articles are distributed under the terms of the [Creative Commons Attribution-NonCommercial-ShareAlike 4.0 License](https://creativecommons.org/licenses/by-nc-sa/4.0/), which allows others to remix, tweak, and build upon the work non-commercially, as long as appropriate credit is given and the new creations are licensed under the identical terms.

For reprints contact: reprint@ipinnovative.com

1. Introduction

The discovery of additional canals in comparison to traditional canals is on a high rise and serendipitous. This should be accredited to the advances in endodontic therapy aids like magnification and thorough knowledge of the root canals' anatomy for the past few decades. Oftentimes, endodontic treatments fail due to myriad reasons such as insufficient biomechanical preparation of root canals, inadequacies in the root canal obturation post cleaning and shaping, failure to access the miniature root canal orifices. All these may lead to acute flare ups during and after root canal therapies.¹

There is a general consensus regarding the anatomy of the permanent maxillary first molar that it shows three roots and four canals in the majority of teeth.² Literature reports a variation of 2.25 – 2.4% of the occurrence of five

root canals^{3,4} and a 0.319 – 0.88% existence of six root canals.⁵ Regarding the existence of a second distobuccal canal, as low as 1.7%⁶ and 1.25%⁷ of cases have been reported in the literature.

An ex-vivo study showed one maxillary first molar out of 140 samples having three roots and seven canals. They identified three mesiobuccal canals, three distobuccal canals, and one palatal canal.⁸ Literature reports very few cases of endodontically managed maxillary first molars with seven and eight root canals.^{9–13} Contrasts in these variant root canal anatomies reported so far are listed in the Table 1.⁹ This case report presents the treatment of a pulpally involved maxillary first molar which shows atypical root canal configuration of three roots and seven root canals which is later confirmed with the help of cone beam computerized tomography (CBCT) scans.

* Corresponding author.

E-mail address: vinaydarla113@gmail.com (D. S. S. Vinay Kumar).

2. Case Report

A 28-year-old man approached us for dental treatment at our clinic with the chief complaint of a highly spontaneous toothache in his left posterior maxilla for 2 days. The upper left first molar showed tenderness to percussion and intense pain that was aggravated by thermal stimuli. History revealed that the patient had intermittent pain in the same tooth with hot and cold stimuli for the past 1 month which increased during mastication. The patient's medical history was non-contributory.

A clinical examination unveiled a carious maxillary left first molar with no tenderness to palpation of the buccal and palatal aspects of the gingiva. The tooth was firm and the gingiva was coral pink, stippled, and resilient. Vitality testing of the involved tooth showed a premature response with electronic pulp stimulation (Parkel Electronics Division, Farmingdale, NY) whereas it caused a lingering pain with heated gutta-percha (Dentsply Maillefer, Ballaigues, Switzerland) and dry ice (R C Ice; Prime Dental Products Pvt Ltd, Mumbai, India) which was intense. A preoperative radiograph showed a mesio-occlusal radiolucency, involving enamel, dentin and the pulp space with periodontal ligament space widening in relation to the mesiobuccal root (Figure 1A). A diagnosis of symptomatic irreversible pulpitis with apical periodontitis was made after thorough clinical and radiographic examination and root canal treatment was suggested to the patient.

Radiographic evaluation of the molar did not reveal any variation in the canal anatomy. An emergency access opening and a thorough biomechanical preparation was planned in the first appointment. The tooth was anesthetized with 1.8 mL (30 mg) 2% lignocaine containing 1:200,000 epinephrine (Xylocaine; AstraZeneca Pharma Ind Ltd, Bangalore, India.) followed by rubber dam isolation. An endodontic access cavity was established. Clinical examination with a DG-16 endodontic explorer (Hu-Friedy, Chicago, IL) revealed two canal openings in each of the distobuccal and palatal root and two root canals in mesio buccal root. Further champagne bubble test revealed a third mesiobuccal canal along the mesiobucco- palatal leg of the molar triangle. A 28mm corrosion-resistant hard fiber austenite stainless steel gates glidden drill (Mani GGD #1) of size #1 was used in a coronal brushing motion to shape the orifices and clean the coronal one thirds of the root canals. (Figure 1B). The working length was determined with the aid of an apex locator (Root ZX; Morita, Tokyo, Japan) and later confirmed using a radiograph. Multiple working length radiographs were taken at different angulations (Figure 1C) to best reveal the number and morphology of root canal systems. Chemico Mechanical cleaning and shaping was carried out under rubber dam isolation using ProTaper gold nickel-titanium rotary instruments (Dentsply Maillefer) with a crown down technique. Irrigation was performed using normal saline and

5% sodium hypochlorite solution in the first appointment. An intra canal calcium hydroxide was placed inside the root canals with the help of lentulo spirals in a slow speed handpiece.

During the second appointment, the patient was asymptomatic. Access cavity was reopened and root canals were irrigated with 5% sodium hypochlorite, and normal saline solutions respectively. Master cone radiograph was taken (Figure 1D) and canals were irrigated with normal saline, 17% EDTA further 2% chlorhexidine digluconate was used as the final irrigant. The canals were dried with absorbent points (Dentsply Maillefer), and obturation was performed using cold lateral compaction by using gutta-percha (Dentsply Maillefer) and AH Plus resin sealer (Maillefer, Dentsply, Konstanz, Germany). (Figure 1E) Post obturation access cavity was documented with an intraoral camera image (Figure 1F). The tooth was then restored with a posterior composite resin core (P60; 3M Dental Products, St Paul, MN). A CBCT x-ray was taken to confirm the canal morphology. (Figure 1G) The patient has been advised a full-coverage porcelain crown and was asymptomatic during the follow-up period of 3 months.

3. Discussion

Although CBCT evaluation of root canals in the preoperative stage is a sure way to assess the root canal anatomy, at times of emergency this option may not be feasible. In these scenarios- magnification with the assistance of surgical loupes and surgical microscopes, fiber optic transillumination, angled preoperative radiographs, examination of the pulp-chamber floor with a sharp explorer, troughing of the grooves with ultrasonic tips, staining the chamber floor with 1% methylene blue dye, performing the sodium hypochlorite “champagne bubble test,” and visualizing canal bleeding points are all essential aids in locating the root canal orifices.¹⁴ In this present study loupes were used as an aid for magnification along with champagne bubble test to locate the additional orifices while following the access cavity preparation laws advocated by Krasner and Rankow.

The crucial variation found in the maxillary first molars is the presence of 54 percent chances of the second mesiobuccal canal (Hess 1925). This number seems to vary in the range of 70 to 80 percent (Hartwell and Bellizzi), 56.8 percent incidence of two canals (Cleghorn et al 2006), and a 95 percent chance by (Studebaker B et al 2017). In vivo studies typically report a lower frequency of two canals in the mesiobuccal root because of the clinician's inability to manipulate the tooth in hand and inconsistency of obturating all root canals leading to high failure rates in endodontic treatment.^{6,15–17}

Root canals are formed due to the secondary dentin apposition that occurs during tooth maturation. This results in dentinal vertical partitions inside the root canal cavity. A

Table 1: Variations of roots and the canal anatomy of maxillary molars, as reported by various authors, with the numerous terms that have been used to name these aberrancies.

Root nomenclature	Root canal nomenclature	
MB, DB, MP , DP	MB, DB, MP , DP	Di Fiore, 1999(20)
MB, D , P	MB1, MB2, P1, P2, D	Johal, 2001 (16)
MB, DB, P	MB1, MB2, DB, P1 , P2 , P3	Maggiore et al., 2002 (17)
MB, DB, P	MB1, MB2 , MP , DB, P	Favieri et al., 2006 (11)
MB, DB, P	MB1, MB2, DB, P1 , P2	Aggarwal et al., 2009 (18)
MB, MP , P, DB	MB, MP , M, P, DP , DB	Adanir, 2007 (3)
MB, DB, P	MB, MP, DB, 3P	Pasternak Júnior et al., 2007 (13)
MB, DB, 1st P , 2nd P	MB, DB, P1 , P2	Ulusoy and Görgül, 2007 (19)
MB, DB, P	MB, DB, 2P	Poorni et al., 2008 (15)
MB, DB, P	MB1 , MB2 , MB3 , DB, P	Ozcan et al., 2009 (12)
MB, DB, P	2MB , 2DB , 2P	de Almeida-Gomes et al., 2009 (14)
MB1 , MB2 , DB, MP , DP	MB1, MB2 , DB, MP , DP	Kottoor et al., 2010 (4)
MB, DB, P	MB1, MB2, MB3 , DB1 , DB2 , MP , DP	Kottoor et al., 2010 (7)
MB, DB, P	MB1, MB2, DB1 , DB2 , MP , DP	Albuquerque et al., 2010 (21)
MB, DB, P	MB, SMB , SDB , DBP , MBP , DB, MP , DP	Karthikeyan and Mahalaxmi, 2010 (10)

MB: mesiobuccal, DB: distobuccal, P: Palatal, MP: mesiopalatal, DP: distopalatal, M: mesial, D: distal, SMB: second mesiobuccal, MBP: mesiobuccopalatal, SDB: second distobuccal, DBP: distobuccopalatal.

Source: Kottoor J, Albuquerque DV, and Velmurugan N. A New Anatomically Based Nomenclature for the Roots and Root Canals—Part 1:MaxillaryMolars. International Journal of Dentistry Volume 2012, Article ID 120565, 7 pages doi:10.1155/2012/120565.

Table 2: Bansal R,Hegde S and Astekar M. Classification of Root Canal Configurations: A Review and a New Proposal of Nomenclature System for Root Canal Configuration Journal of Clinical and Diagnostic Research. 2018 May, Vol-12(5): ZE01-ZE05.

Configuration	Gulabivala K et al	Sert S
3-1	Type I	Type XVIII
3-2	Type II	Type XV
2-3	Type III	Type XVI
2-1-2-1	Type IV	Type XIX
4-2	Type V	Type XIV
4-4	ype VI	Type XX
5-4	Type VII	Type XXII

third root canal may also be created inside the root canal cavity of maxillary molars by this process. Chances of a second MB, extra DB, and an additional palatal canals occurrence are very sleek yet the possibility should never be ignored and thorough negotiation of the root canal floor has to be done for the ultimate success of the endodontic therapy. Guided troughing under high magnification enables the location of these extra root canals. The diameter of such extra canals is usually smaller than that of the other two. The third mesial canal is defined as being independent when a distinct coronal orifice and apical foramen are observed¹⁸ and defined as being confluent when converging into one of the other two main canals and terminating at a common apical foramen.¹⁹ Oftentimes, due to thin dentinal structure apposed between the root canal chambers, a coalition of confluent canals into a single canal is possible during the biomechanical preparation of root canals which happened in the present case.

Over the years, numerous root canal configurations have been identified resulting in the proposal of numerous

classifications and their modifications. Depending upon the configuration, root canal may exit apically through one or more than one apical foramen. Kottoor J et al (2010) presented a case with an MB1, MB2, MB3, DB1, DB2, MP, DP canals which is similar to the present seven canal morphology of maxillary first molar. Although preoperative CBCT evaluation was not done in this case, in the post obturation CBCT presence of seven root canal orifices can be precisely appreciated. Furthermore, this case shows 3-1 configuration in the mesiobuccal root which is classified as type1 anatomy according to Gulabivala, and type XVIII anatomy according to Sert S and Bayirli GS which was an extension to Vertucci classification²⁰ (Table 2). Adding further, a Vertucci type II classification was evident in the distal and palatal canals. The pulp space separates into three and joins in its course into one. In this present case, CBCT radiograph post obturation shows three apical foramina with seven orifices.

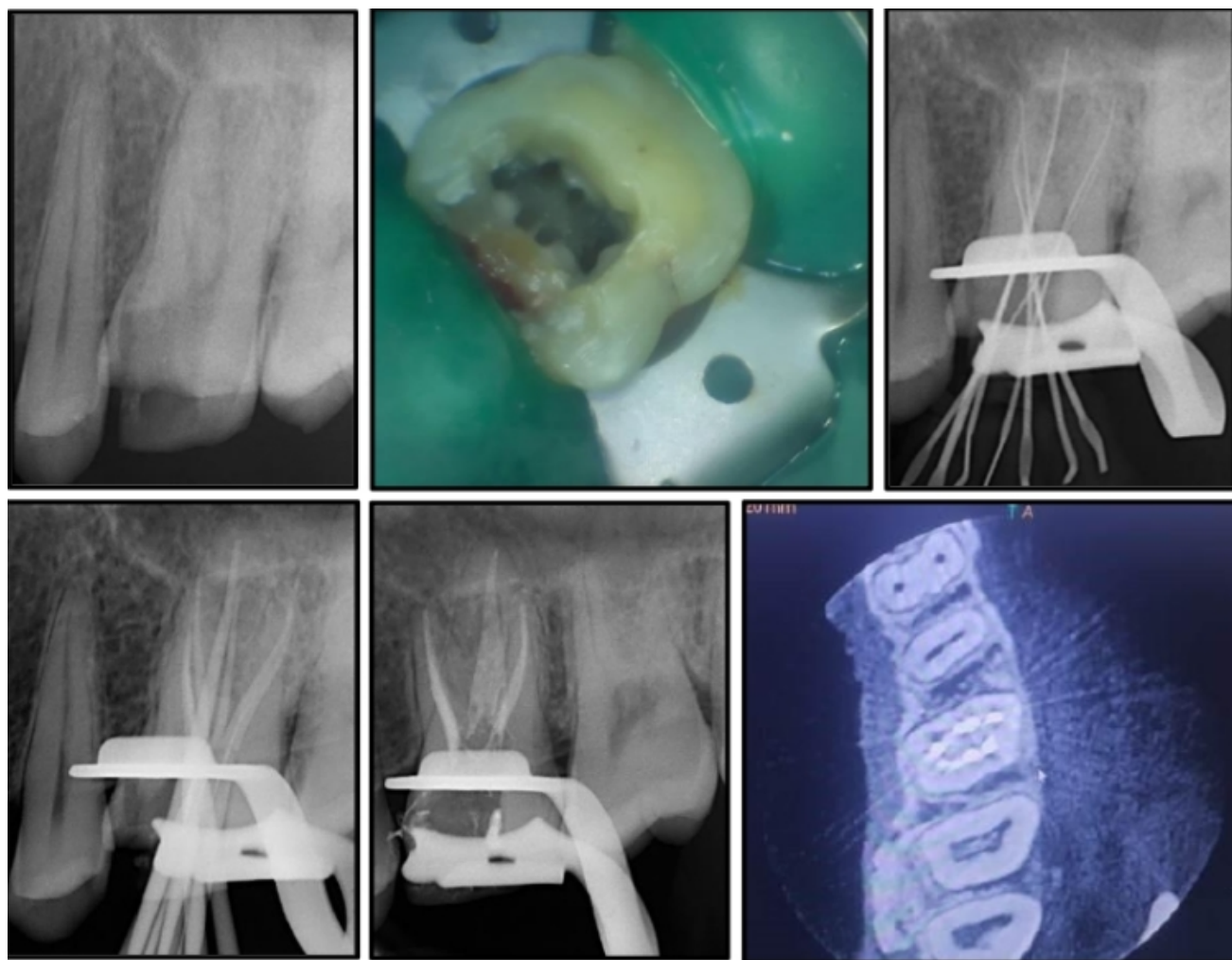


Fig. 1: A: Preoperative radiograph; B: Access opening photograph; C: Working length radiograph; D: Master cone radiograph; E: Obturation radiograph; F: Post obturation photograph; G: Post obturation CBCT image shows seven obturated root canal orifices in the maxillary first molar.

4. Conclusion

A thorough root canal floor inspection following access cavity preparation aided with a magnifying microscope or loupes can ease up the errors encountered due to aberrant canals. Chances of missing root canals can be eliminated when laws are followed meticulously in parallel with magnification. Therefore, the clinician has to consider this step with paramount importance while doing routine root canal therapy.

5. Conflict of Interest

The authors declare that there is no conflict of interest.

6. Source of Funding

None.

References

1. Weine F. . Endodontic Therapy, 6th Edn. Boston, MA, USA: Mosby; 2004. p. 366.
2. Walton R, Torabinejad M. Principles and practice of endodontics. Philadelphia: W.B. Saunders Co; 2002. p. 181-233.
3. Gray R. The maxillary first molar. In: Bjorndal A, Skidmore E, editors. Anatomy and Morphology of the Human Teeth. Iowa City: University of Iowa College of Dentistr; 1983. p. 31-40.
4. Vigouroux SA, Bosaans ST. Anatomy of the pulp chamber floor of the permanent maxillary first molar. *J Endod.* 1978;4(7):214-9. doi:10.1016/S0099-2399(78)80186-1.
5. Martinez-Berna A, Ruiz-Badanelli P. Maxillary first molars with six canals. *J Endod.* 1983;9(9):375-81. doi:10.1016/S0099-2399(83)80188-5.
6. Cleghorn BM, Christie WH, Dong CC. Root and root canal morphology of the human permanent maxillary first molar: A literature review. *J Endod.* 2006;32(9):813-21. doi:10.1016/j.joen.2006.04.014.
7. Kim Y, Lee SJ, Woo J. Morphology of maxillary first and second molars analyzed by cone-beam computed tomography in a Korean population: Variations in the number of roots and

- canals and the incidence of fusion. *J Endod.* 2012;38(8):1063–8. doi:10.1016/j.joen.2012.04.025.
8. Filho FB, Zaitter S, Haragushiku GA, De Campos E, Abuabara A, Correr GM, et al. Analysis of the internal anatomy of maxillary first molars by using different methods. *J Endod.* 2009;35(5):337–42. doi:10.1016/j.joen.2008.11.022.
 9. Kottoor J, Velmurugan N, Sudha R, Hemamalathi S. Maxillary first molar with seven root canals diagnosed with cone-beam computed tomography scanning: a case report. *J Endod.* 2010;36(5):915–21. doi:10.1016/j.joen.2009.12.015.
 10. Badole G, Waebadpande MM, Shenoi PR, Lachure C, Badole SG. A rare root canal Configuration of bilateral maxillary first molar with 7 root canals diagnosed using Cone-beam computed tomographic scanning: A case report. *J Endod.* 2014;40(2):296–301. doi:10.1016/j.joen.2013.09.004.
 11. Raghavendra SS, Hindlekar AN, Desai NN, Vyavahare NK, Napte BD. Endodontic management of maxillary first molar with seven root canals diagnosed using Cone Beam Computed Tomography scanning. *Indian J Dent.* 2014;5(3):152–6. doi:10.4103/0975-962X.140837.
 12. Pires MD, Martins JNR. Endodontic management of maxillary permanent first molar with seven root canals - Report of two cases. *Rev Port Estomatol Med Dent Cir Maxilofac.* 2019;60(4):197–204. doi:10.24873/j.rpemd.2020.01.692.
 13. Kottoor J, Velmurugan N, Surendran S. Endodontic management of a maxillary first molar with eight root canal systems evaluated using cone-beam computed tomography scanning: A case report. *J Endod.* 2011;37(5):715–9. doi:10.1016/j.joen.2011.01.008.
 14. Vertucci FJ. Root canal morphology and its relationship to endodontic procedures. *Endod Topics.* 2005;10(1):3–29. doi:10.1111/j.1601-1546.2005.00129.x.
 15. Studebaker B, Hollender L, Mancl L, Johnson JD, Paranjpe A. The Incidence of Second Mesio Buccal Canals Located in Maxillary Molars with the Aid of Cone-beam Computed Tomography. *J Endod.* 2018;44(4):565–70. doi:10.1016/j.joen.2017.08.026.
 16. Hartwell G, Bellizzi R. Clinical investigation of in vivo endodontically treated mandibular and maxillary molars. *J Endod.* 1982;8(12):555–7. doi:10.1016/S0099-2399(82)80016-2.
 17. Smadi L, Khraisat A. Detection of a second mesio buccal canal in the mesio buccal roots of maxillary first molar teeth. *Oral Surg Oral Med Oral Pathol Oral Radiol Endod.* 2007;103(3):77–81. doi:10.1016/j.tripleo.2006.10.007.
 18. La SH, Jung DH, Kim EC, Min KS. Identification of independent middle mesial canal in mandibular first molar using cone-beam computed tomography imaging. *J Endod.* 2010;36(3):542–5. doi:10.1016/j.joen.2009.11.008.
 19. Holtzmann L. Root canal treatment of a mandibular first molar with three mesial root canals. *Int Endod J.* 1997;30(6):422–3. doi:10.1046/j.1365-2591.1997.00106.x.
 20. Bansal R, Hegde S, Astekar M. Classification of Root Canal Configurations: A Review and a New Proposal of Nomenclature System for Root Canal Configuration. *J Clin Diagn Res.* 2018;12(5):ZE01–5. doi:10.7860/JCDR/2018/35023.11615.

Author biography

Darla Satya Sanyasi Vinay Kumar, Assistant Professor

Saila Manisha, Student

Bhargav Kambampati, Assistant Professor

Vijaykanth Kattamuri, Assistant Professor

Sivaji Kavuri, Assistant Professor

Garapati Harshitha, Post Graduate

Cite this article: Vinay Kumar DSS, Manisha S, Kambampati B, Kattamuri V, Kavuri S, Harshitha G. Root canal treatment in a maxillary first molar with seven root canals. *IP Indian J Conserv Endod* 2022;7(1):31-35.