



Short Communication

Incorporating modern caries management into general dental practice: An overview for clinicians in India

Indrajeet Ghosh^{1,*}, Prasanta Banerjee¹, Sugandha Prakash¹

¹Dept. of Conservative and Endodontics, Dental Zone, Kalimati Road Sakchi, Jamshedpur, Jharkhand, India



ARTICLE INFO

Article history:

Received 15-11-2022

Accepted 05-12-2022

Available online 14-01-2023

Keywords:

dental caries

Preventive

Management

Risk assessment

CAMBRA

Cariogram

ABSTRACT

The available scientific literature has established the fact that restorations do not last forever. The disease process i.e caries has to be managed as a disease if patients need to heal from it. A caries management plan must be in place for each individual patient for this purpose. The management plan needs to be risk-based and prevention-focused and has to concurrently run during and after the restorative phases of treatment. Only then over treatment in restorative dentistry can be avoided. This paper gives an overview to clinicians in India on modern caries management and how it can be implemented in general dental practice.

This is an Open Access (OA) journal, and articles are distributed under the terms of the [Creative Commons Attribution-NonCommercial-ShareAlike 4.0 License](https://creativecommons.org/licenses/by-nc-sa/4.0/), which allows others to remix, tweak, and build upon the work non-commercially, as long as appropriate credit is given and the new creations are licensed under the identical terms.

For reprints contact: reprint@ipinnovative.com

1. Introduction

Scientific evidence has previously established the fact that restorations do not last a lifetime.^{1,2} A considerable extent of a practitioner's professional life is spent on placing and replacing restorations. Often, clinicians encounter an individual patient whose reason for attendance is for replacement or repair, or refurbishment of existing defective restorations or requires restorations for newly cavitated lesions. This should be a cause for concern for the operator as it suggests that an uncontrolled carious process is functional in the patient's mouth, independent of earlier restorative work. Therein, lies the importance of a caries management plan.³

2. What is Modern Caries Management?

Modern Caries Management (MCM) has evolved from over three decades of caries research.⁴ Its goal is to arrest the dynamic caries process in the patient's oral cavity, prevent any further cavitated/ non-cavitated lesions and restore any

new or old lesions with a minimum-intervention philosophy. To explain it broadly, modern caries management operates at two levels.⁴ (Figure 1)

1. Oral Components management.
2. Tooth tissue-level management.

Success in management for both levels can only be obtained by mitigation of the degree of risk of caries exhibited by the patient.⁵ As per CAMBRA guidelines any patient with one or more cavitated lesions can be considered a high risk for caries individual.⁵ CAMBRA (CAries Management By Risk Assessment) or Cariogram⁶ are risk assessment tools developed by Western researchers for this very purpose (Figure 2).

The key points in Oral Components management are as below

1. Inadequate saliva formation/ expression: A sub-normal saliva flow and function may not be expressed by the patient in the form of any symptom. It will need to be tested and addressed.⁸

* Corresponding author.

E-mail address: indrajeetghosh465@gmail.com (I. Ghosh).

Table 1: ICCMS document 2014

Caries status in an individual tooth	Visual examination finding	Tooth tissue caries management	Oral components
Initial stage	First Visual Change in Enamel (seen only after prolonged air drying or restricted to within the confines of a pit or fissure) Distinct Visual Change in Enamel seen on a wet tooth surface	<ul style="list-style-type: none"> • Sealant application • Fluoride varnish application 3-4 Monthly 	<ul style="list-style-type: none"> • CAMBRA high-risk oral components management protocol. • Recall system for monitoring loss of sealant
Moderate stage	<ul style="list-style-type: none"> • Localized Enamel Breakdown (without clinical visual signs of dentinal involvement) • Underlying Dark Shadow from Dentine 	<ul style="list-style-type: none"> • Tissue-preserving operative care • Sealants for other teeth • Fluoride varnish application 3-Monthly 	<ul style="list-style-type: none"> • CAMBRA high-risk oral components management protocol. • Recall system for monitoring loss of sealant
Extensive stage	<ul style="list-style-type: none"> • Distinct Cavity with Visible Dentine • Extensive Distinct Cavity with Visible Dentin 	<ul style="list-style-type: none"> • Tissue preserving operative care (Step-wise excavation?) • Sealants for other teeth • Fluoride varnish 3-4m 	<ul style="list-style-type: none"> • CAMBRA high-risk oral components management protocol. • Recall system for monitoring loss of sealant + for repeat excavation (?)

Table 2: High-risk for caries protocol - phases

Comprehensive oral exam	Phase 1	Phase 2	Phase 3	Phase 4
Caries bacterial test	Oral prophylaxis	Sealants for all posterior teeth	Defer orthodontics and prosthetics till caries and periodontal	Periodic oral exam every six months including bitewing radiographs
Saliva flow and function analysis	Oral hygiene counselling		Re-evaluate caries and periodontal status at 4-6 weeks from initial therapy/phase 1	Caries bacterial test every six months to check for efficacy of the chlorhexidine rinse
Diet analysis	Dietary advice			Review compliance with chlorhexidine gluconate rinse and HCFPT and oral hygiene
Cariogram based study of relative impact of causal factors	Prescribe chlorhexidine gluconate (0.12 percent) rinse to be used once daily at night for one week each month. Repeat monthly. Use separated by one hour from high concentration fluoride toothpaste.			Fluoride varnish of all teeth
Bitewing radiographs	Prescribe HCFPT used twice daily in place of low concentration fluoride toothpaste Fluoride varnish of all teeth Complete endodontics therapy of LL6			

HCFPT = High Concentration Fluoride Prescription Toothpaste (2800ppm F for patients over 10 years of age and 5000ppm F for those over 16 years of age).

Sample treatment plan for a 'High Caries' risk patient (adapted from Jenson et al 2007).⁷ 'High Caries' risk: 17-year-old female, ongoing endodontic therapy of LL6; missing teeth UR6 and LR6; poor oral hygiene; UL4 and UL6 pit and fissures stained; Orthodontist recommendation for restorations in UL4, UL6.

Table 3: Highrisk for caries protocol

1.	Flouride based mouthrinse (200 ppm) 10ml undiluted twice daily as a regular mouthwash x 6 months.
2.	Sugar-free (with Xylitol preferably) chewing gum 2 tabs 4 times a day esp. after meals x 6 months.
3.	Chlorhexidine mouthwash 1:1 dilution with water for 1 minute once at night before sleep for 1 week ONLY every month.
4.	Flouride based toothpaste (1450 ppm) twice daily as a regular toothpaste.
5.	Flouride varnish (22,600 ppm) application every 4 months for 2 years.

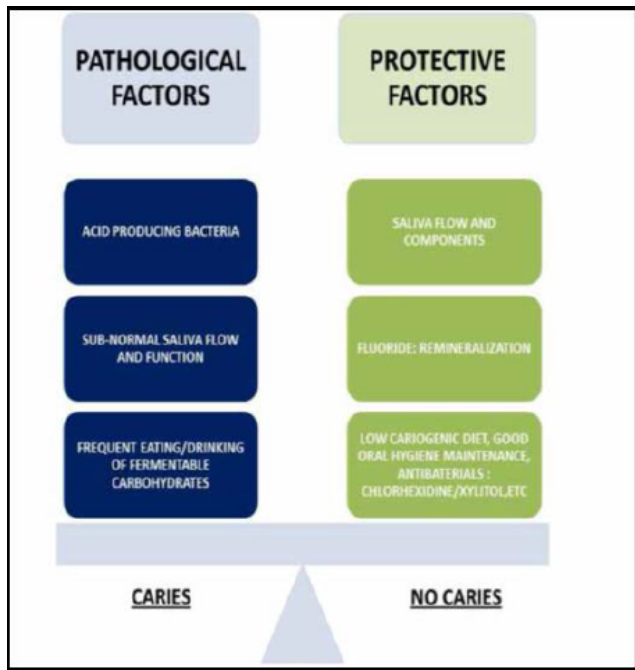


Fig. 1: Featherstonediagram (2005).

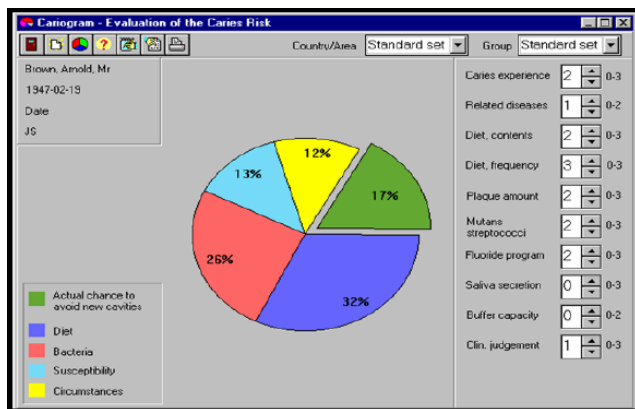


Fig. 2: Cariogram⁶

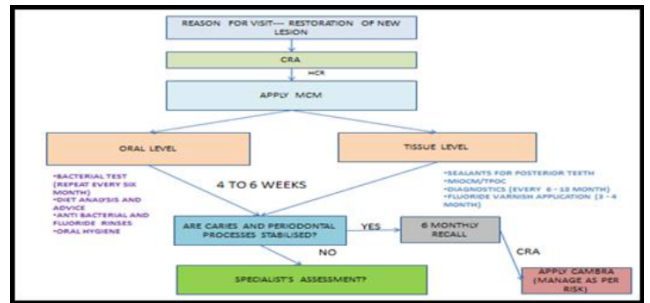


Fig. 3: Work flow for the general practitioner.

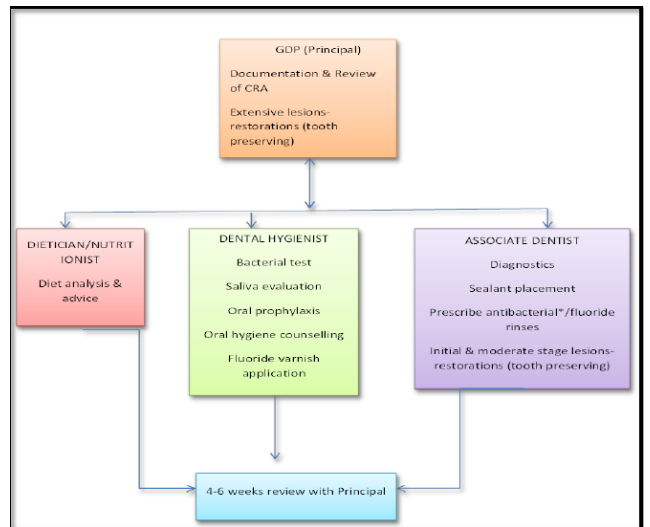


Fig. 4: Caries management team work (Suggested Model). GDP-General Dental Practitioner, CRA-Caries Risk Assessment, HCR-High Caries Risk
MIOCM- Minimally Invasive. Operative Caries Management.
TPOC-Tooth Preserving Operative Care.

2. Commercially saliva test kits are available which can be good motivational tools for the behavioral changes in the patient that are desired by the clinician.
3. Patients/ clinicians might not always recognize the cariogenic potential of certain foods in their daily diet and therefore a detailed analysis by a nutrition expert/dietician is needed for both parties to address.
4. Patients with new caries lesions or exhibiting a negative change in the size and activity of existing lesions may be regarded as having insufficient fluoride

exposure.

The key points in Tooth Tissue-Level Management are as below (Table 1)(Figures 3 and 4):

1. Involves protecting existing tooth structure affected or unaffected by cavitated or non-cavitated lesions.⁷
2. Restoring lost tooth tissue with the least invasive restorative approach.⁹
3. Detection of a carious lesion does not automatically qualify it for a restoration.¹⁰
4. A tissue-preservative approach is the first line of treatment for any clinical situation (operative or non-operative).¹¹
5. Vitality assessment is an important factor in extensive lesions and caries removal in the deepest part of the cavitated lesion is done only to remove softened and infected dentine and ensure no exposure of the vital pulp.¹²
6. Whenever there is an associated risk of exposing the pulp, a step-wise partial caries excavation is the standard operating procedure.¹²
7. Defective restoration margins need either sealant application or repair or refurbishment and not a replacement.
8. If sealants are applied then an appropriate recall system needs to be in place (based on risk assessment) to monitor for loss of sealant and subsequent maintenance/repair.

For implementing minimum intervention in restorative dentistry, early identification of caries lesions (both cavitated and non-cavitated) is important and various commercially available products are available for the preventive and restorative phases of a minimum intervention treatment plan.¹³

3. Conclusion

There has been a paradigm shift from the historic/conventional method of caries management.¹⁴ The interplay of factors causally responsible for dental caries is different for each individual and is assessed using CARIOGRAM and CAMBRA. The current-day approach (Operative/ non-operative) is Evidence-based, Risk-based & prevention focused (Table 2) and can be easily implemented with minimal damage to the tooth as well as tissue structure. Patients should be periodically assessed with regards to caries risk at intervals consistent with CAMBRA guidelines. (Table 3)

Opportunities exist for the educators to rethink the older concepts and teach the newer concepts in dental schools so that patients directly benefit from thirty years of caries research. Opportunities also exist for the researchers to set-up a Dental Practice Based Research Network (DPBRN) to monitor the effectiveness of caries management practices across the country.

4. Conflict of Interest

None.

5. Source of Funding

None.

References

1. Elderton RJ. Clinical studies concerning re-restoration of teeth. *Adv Dent Res.* 1990;4:4–9. doi:10.1177/08959374900040010701.
2. Ghosh I, Dayal P, Das S. Overtreatment in caries management? A literature review perspective and recommendations for clinicians. *Dent Update.* 2016;43(5):419–29.
3. Elderton RJ. Preventive (evidence-based) approach to quality general dental care. *Med Princ Pract.* 2003;12(1):12–21. doi:10.1159/000069841.
4. Hurlbutt M, Young DA. The best practices approach to caries management. *J Evid Based Dent Pract.* 2014;14:77–86.
5. Crall JJ, Donly KJ. Dental sealants guidelines development: 2002–2014. *Pediatr Dent.* 2015;37(2):111–5.
6. Brathall D, Petersson GH. Cariogram—a multifactorial risk assessment model for a multifactorial disease. *Community Dent Oral Epidemiol.* 2005;33(4):256–64. doi:10.1111/j.1600-0528.2005.00233.x.
7. Jenson L, Burdenz AW, Featherstone JD, Ramos-Gomez FJ, Spolsky VW, Young DA, et al. Clinical Protocols for Caries Management by Risk Assessment. *J Calif Dent Assoc.* 2007;35(10):714–23.
8. Featherstone JD, Adair SM, Anderson MH, Berkowitz RJ, Bird WF, Crall JJ, et al. Caries management by risk assessment: a consensus statement. *J California Dent Assoc.* 2002;31(3):257–69.
9. Kutsch VK, Milicich G, Domb W, Anderson M, Zinman E. How to integrate CAMBRA into private practice. *J Calif Dent Assoc.* 2007;35(11):778–85.
10. Peters MC. Strategies for noninvasive demineralized tissue repair. *Dent Clin N Am.* 2010;54(3):507–25. doi:10.1016/j.cden.2010.03.005.
11. Banerjee A, Doméjean S. The contemporary approach to tooth preservation: minimum intervention (MI) caries management in general practice. *Prim Dent J.* 2013;2(3):30–7. doi:10.1308/205016813807440119.
12. Elderton RJ. Implications of recent dental health services research on the future of operative dentistry. *J Public Health Dent.* 1985;45(2):101–5.
13. Pitts N, Ismail A, Martignon S, Ekstrand K, Douglas G, Longbottom C, et al. ICCMS™ guide for practitioners and educators. London: King's College London; 2014.
14. Ghosh I. Modern management of dental caries and how it must be approached by practitioners. *J Oral Med.* 2017;1(1):1.

Author biography

Indrajeet Ghosh, Practice Principal

Prasanta Banerjee, Practice Principal

Sugandha Prakash, Consultant Periodontist

Cite this article: Ghosh I, Banerjee P, Prakash S. Incorporating modern caries management into general dental practice: An overview for clinicians in India. *IP Indian J Conserv Endod* 2022;7(4):202–205.