

Content available at: <https://www.ipinnovative.com/open-access-journals>

IP Indian Journal of Conservative and Endodontics

Journal homepage: <https://www.ijce.in/>

Case Report

Partial endodontic procedure..boom!!

Kanike Keerthi Viswa Teja^{1,*}, Purushotham R¹, Samrat M.R¹, Sujith R¹, Kavita G¹

¹Dept. of Conservative and Endodontics, Sharavathi Dental College and Hospital, Shimoga, Karnataka, India



ARTICLE INFO

Article history:

Received 30-01-2023

Accepted 06-03-2023

Available online 04-12-2023

Keywords:

PRF

Biodentine

Endocrown

Coronal rehabilitation

ABSTRACT

Teeth which are extensively destructed coronally are usually treated with root canal therapy and reinforced by placement of post in the root canals, no matter if the tooth is still vital or not. This case report presents two cases of coronal pulpotomy using PRF and Biodentine™ in mature permanent teeth which were extensively destructed by caries. The intra oral periapical radiograph illustrated a deep carious lesion extended almost to the pulp. After caries excavation under rubber dam isolation, the exposed pulp tissue was amputated to the level of the canal orifice with a new sterile bur. PRF followed by Biodentine™ was placed as the pulp capping agent after haemostasis was obtained and temporary restoration was placed. The clinical signs and symptoms were relieved after the procedure. After 15 days, the temporary restoration was removed and a GIC restoration was placed over the Biodentine™ as an interim restoration. At 12 months follow-up, the teeth were asymptomatic. The choice of Endo-crown prosthesis was made for coronal rehabilitation of extensively destructed teeth. This kind of partial endodontic procedure in mature permanent teeth with extensively destructed coronal tooth structure can revive the teeth to their normal function by maintaining the vitality and proprioception of the teeth.

This is an Open Access (OA) journal, and articles are distributed under the terms of the [Creative Commons Attribution-NonCommercial-ShareAlike 4.0 License](https://creativecommons.org/licenses/by-nc-sa/4.0/), which allows others to remix, tweak, and build upon the work non-commercially, as long as appropriate credit is given and the new creations are licensed under the identical terms.

For reprints contact: reprint@ipinnovative.com

1. Introduction

Management of deep carious lesion is considered to be challenging clinical procedure for all dental practitioners till date. Diagnosis and identification of clinical condition is itself cumbersome. With the progress in research and development of dental materials in past decade, management of deep carious lesions with minimal invasive approach has shown progressive results and also are able to preserve the vitality of the tooth.

Certain two kind of deep caries management procedure were carried out like direct and indirect pulp capping, but outcome of treatment was never expected to be favorable, it may be because extension of infection can never be evaluated clinically. The success rate for this procedure

varies widely from 56% to 100%.¹

In order to limit the spread of infection towards radicular portion, two invasive procedures like partial and total coronal pulpotomy were carried out to maintain the vitality of radicular pulp. Since certain portion of vital and infected pulpal tissue is removed under aseptic condition, this technique have shown better results clinically. The success rate of full pulpotomy varies between 82.9% to 100%.²

Success rate of any clinical procedure in endodontics depends upon different features like virulence factor of microbes, tooth structure, age of the patient and self-cleaning area.

Retaining the grossly destructed tooth with minimal amount of occlusal height is challenging for operator. For extensively destructed tooth, indirect bonded restoration is more suitable than direct restoration.

* Corresponding author.

E-mail address: kkvteja1996@gmail.com (K. K. V. Teja).

In Present case report efforts were made to overcome the problem associated with deep carious lesion and restoration with noninvasive procedure. Novel clinical procedure like Endo crown was used to reinforce the extensively destructed tooth while maintain vitality of tooth in physiological manner by improving marginal integrity and reduced marginal microleakage. Overall, the indirect restorations have a lower annual mean failure rate than direct restorations in posterior teeth.

This case report is aimed at evaluating the outcome of the combination of full pulpotomy and placement of indirect Endo crown on teeth which are extensively destructed by carious lesions.

2. Case Report

2.1. Case 1

A 19-year-old male Patient reported to the Department of conservative dentistry and endodontics, Sharavathi dental college and hospital, complaining about pain on chewing food in the lower left back tooth region (tooth number 37). Patient presented with a history of spontaneous pain that lingers after removal of the stimulus. On clinical examination, tooth was extensively destructed with arrested caries, with no tender on percussion. On radiographic examination, the radiolucency was involving enamel, dentin and approaching coronal pulp, with no visible periapical lesion and intact PDL, confirming diagnosis to be focal irreversible pulpitis.

Treatment protocol was discussed with the patient and his parents regarding the expected outcome. Informed consent was taken and treatment was carried out under aseptic condition.

The tooth was isolated under rubber dam, deroofing of pulp chamber was made with sterile round bur (number 4, Mani), the coronal pulp tissue was removed with sterile spoon excavator, after excavation of pulp bleeding was controlled with sterile cotton pellet for 60 seconds. The radicular pulp was fixed with 3% sodium hypochlorite for 30 seconds to stop the bleeding. Later after pulpal fixation PRF was placed on the pulpal floor which was obtained from patients own blood, followed by placement of Biodentine™ upon PRF of about 2 mm. The tooth was temporized with Cavit. After 15 days patient was recalled and assessed for any signs and symptoms, tooth was asymptomatic, temporary restoration was replaced with glass ionomer cement as interim restoration and kept under observation. Patient was recalled for review at 1 month, 3 months, 6 months and 12 months after treatment to evaluate pulpal status. At each stage, a clinical and radiographic examination of treated tooth was carried out. Clinical examination was conducted to verify:

1. The lack of dental pain or pain related behavior declared by the patient.

2. The lack of clinical symptoms of infectious disease related to the therapeutic pulpotomy treatment.

Intra oral periapical radiographs were taken using RVG in paralleling technique. Radiographic evaluation was conducted to evaluate and compare the periapical status of the teeth.

Once patient was totally asymptomatic and with no periapical changes radiographically, the Endo crown was fabricated after 12 months, As the tooth treated in this case report had extreme coronal damage, the choice of Endo crown prosthesis was made to restore the tooth structure.

Fundamental of tooth preparation was carried out to fulfill the objective of full cuspal coverage. For the central anchorage of pulpotomised tooth, Endo crown was taken from within the pulp chamber, also giving additional retentive features like internal box preparation and maintaining the PRF, Biodentine™ and GIC thickness to about 3mm over the sub pulpal floor and eliminating undercuts in the access cavity. The preparation limits were equigingival to facilitate impression and bonding. Endo crown was cemented by using self-adhesive resin cement as luting agent (solocem, coltene) under rubber dam isolation.(Figure 1)

2.2. Case 2

A 25-year-old male Patient reported to the Department of conservative dentistry and endodontics, Sharavathi dental college and hospital, complaining about decayed tooth and sensitivity on drinking cold and hot substances in the lower left back tooth region (tooth number 36). Patient presented with the history of low intense, short-lasting pain while chewing food. On clinical examination, tooth was extensively destructed with caries, no tender on percussion. On radiographic examination radiolucency involving enamel and dentine, with no visible periapical lesion and intact PDL, confirming diagnosis to be reversible pulpitis.

Treatment protocol was discussed with the patient and his parents regarding the expected outcome. Informed consent was taken and treatment was carried out under aseptic condition.

The tooth was isolated under rubber dam, deroofing of pulp chamber was made with sterile round bur number 4, the coronal pulp tissue was removed with sterile spoon excavator, after excavation of pulp bleeding was controlled with sterile cotton pellet for 60 seconds. The radicular pulp was fixed with 3% sodium hypochlorite for 30 seconds to stop the bleeding. Later after pulpal fixation PRF was placed on the pulpal floor which was obtained from patients own blood, followed by placement of Biodentine™ upon PRF of about 2 mm. The tooth was temporized with Cavit. After 15 days patient was recalled and assessed for any signs and symptoms, tooth was asymptomatic, temporary

restoration was replaced with glass ionomer cement as interim restoration and kept under observation. Patient was recalled for review at 1 month, 3 months, 6 months and 12 months after treatment to evaluate pulpal status. At each stage, a clinical and radiographic examination of treated tooth was carried out. Clinical examination was conducted to verify:

1. The lack of dental pain or pain related behavior declared by the patient.
2. The lack of clinical symptoms of infectious disease related to the therapeutic pulpotomy treatment.

Intra oral periapical radiographs were taken using RVG in paralleling technique. Radiographic evaluation was conducted to evaluate and compare the periapical status of the teeth.

Once patient was totally asymptomatic and with no periapical changes, the Endo crown was fabricated after 12 months. As the tooth treated in this case report had extreme coronal damage, the choice of Endo crown prosthesis was made to restore the tooth structure.

Fundamental of tooth preparation was carried out to fulfill the objective of full cuspal coverage. For the central anchorage of pulpotomised tooth, Endo crown was taken from within the pulp chamber and maintaining the PRF, Biodentine™ and GIC thickness to about 3mm over the sub pulpal floor and eliminating undercuts in the access cavity. The preparation limits were equigingival to facilitate impression and bonding. Endo crown was cemented by using self-adhesive resin cement as luting agent (solocem, coltene) under rubber dam isolation. (Figure 2)

3. Discussion

In the past, the only treatment option for focal irreversible pulpitis has been endodontic treatment. But it is considered to be an invasive and non-biological treatment because it removes the entire inflamed, and healthy pulp, thus losing its reparative/regenerative potential, proprioceptive properties and innervation.³ Therefore, a more conservative approach with vital pulp therapy has been proposed for teeth with focal irreversible pulpitis.

In the current case report, the adult patients visited department of conservative dentistry and endodontics complaining about food lodgment, on clinical examination they had either reversible (low intense, short-lasting induced pain, positive response to vitality tests, without pain on apical palpation of the soft tissues or percussion pain, no radiologically visible apical lesion and intact PDL) or focal irreversible pulpitis (spontaneous pain that lingers after removal of the stimulus, without pain on apical palpation of the soft tissues or percussion pain, no radiologically visible apical lesion and intact PDL), absence of periodontal lesion. In both cases clinical signs and symptoms improved one month after Biodentine™ full pulpotomy.

Pulp tissue can remain vital, even in teeth with focal irreversible pulpitis, this vital tissue has the potential to recover in the presence of an adequate material.⁴

In a recent prospective study on Biodentine™ involving partial and full coronal pulpotomy in mature permanent teeth with both reversible & focal irreversible pulpitis, the authors found a high clinical success rate after one year of close to 100% and a radiographic success of up to 93.8% in focal irreversible pulpitis.⁵

Previous in vivo studies demonstrated that Biodentine™ provides an optimal environment for pulp healing, inducing the formation of a homogeneous dentin bridge at the injury site when applied directly to mechanically exposed pulp. Infact, the dentin matrix-associated growth factors can signal mesenchymal stem cells in the pulp to differentiate into odontoblast-like cells and produce a mineralized barrier in continuity with the primary dentin protecting the underlying vital pulp tissue.^{6,7}

A histological study found that the pulp tissue a few millimetres from the necrotic pulp with bacterial colonization is usually free from inflammation and bacteria. The radicular pulp is rarely inflamed. Therefore, as soon as the infected and inflamed tissue is removed and an appropriate capping agent is applied, a favourable environment for pulp wound healing is created. In addition to its good sealing properties, Biodentine™, like other cements in the tricalcium silicate family, is able to control pro-inflammatory factor secretion and decrease inflammatory cell recruitment.⁸

Long-term failure after vital pulp therapy and endodontic treatment is mainly attributed to micro-leakage at the coronal tooth-restoration interface. Massler et al. (1978) demonstrated that the most important cause of long-term failure in vital pulp therapy is the presence of leakage during the healing process.⁹ Biodentine™ presented good sealing ability, resisting micro-leakage¹⁰ and its bond strength when bonded to resin composite was improved at a maturation time of 2 weeks.¹¹ Biodentine™ has been shown to improve setting time, handling, and mechanical properties, compared with MTA.¹² This cement can be used successfully in dental clinics as a restorative material, and as a dentin substitute for posterior restoration.

In the present case report, along with Biodentine™, PRF is also used, PRF is a second-generation platelet concentrate widely used to accelerate soft and hard-tissue healing. Platelet-rich fibrin is a strictly autologous fibrin matrix containing a large quantity of platelet and leucocyte cytokines¹³ Growth factors play a pivotal role in signalling the events of tissue formation and repair in the dentine-pulp complex. They are responsible for signalling many of the key events in tooth morphogenesis and differentiation, and recapitulation of these processes after dental injury allows tissue regeneration.¹⁴

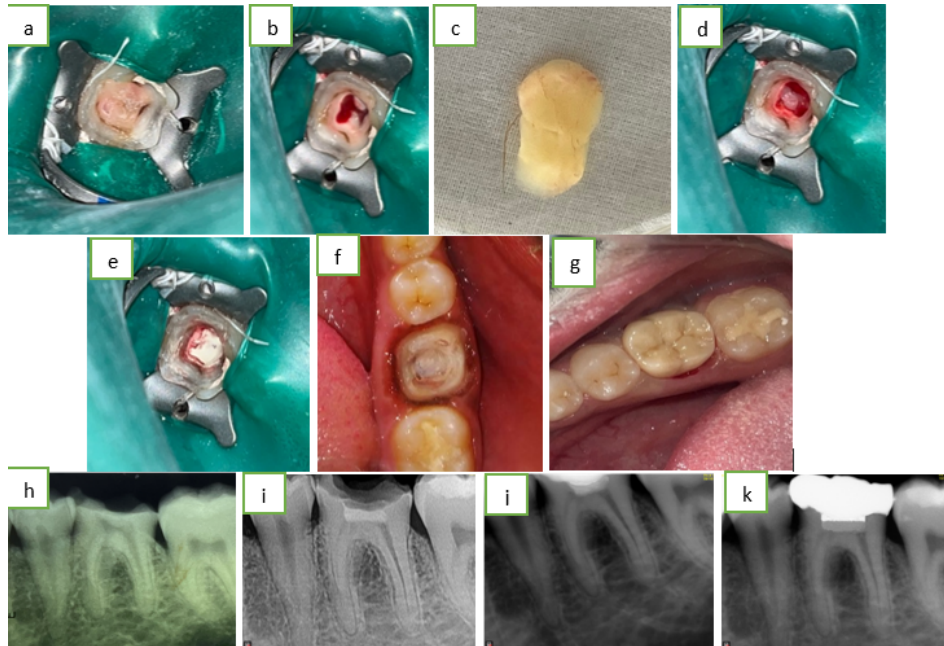


Fig. 1: a: Tooth under rubber dam isolation; b: After full coronal pulpotomy; c: PRF; d: PRF placed in canal orifice; e: Biodentine™ placed over PRF; f: Endo crown preparation retaining required amount of GIC; g: Endo crown irt 36; h: preoperative radiograph; i: radiograph after PRF and Biodentine placement; j: 12 months follow-up radiograph; k: after Endo crown placement

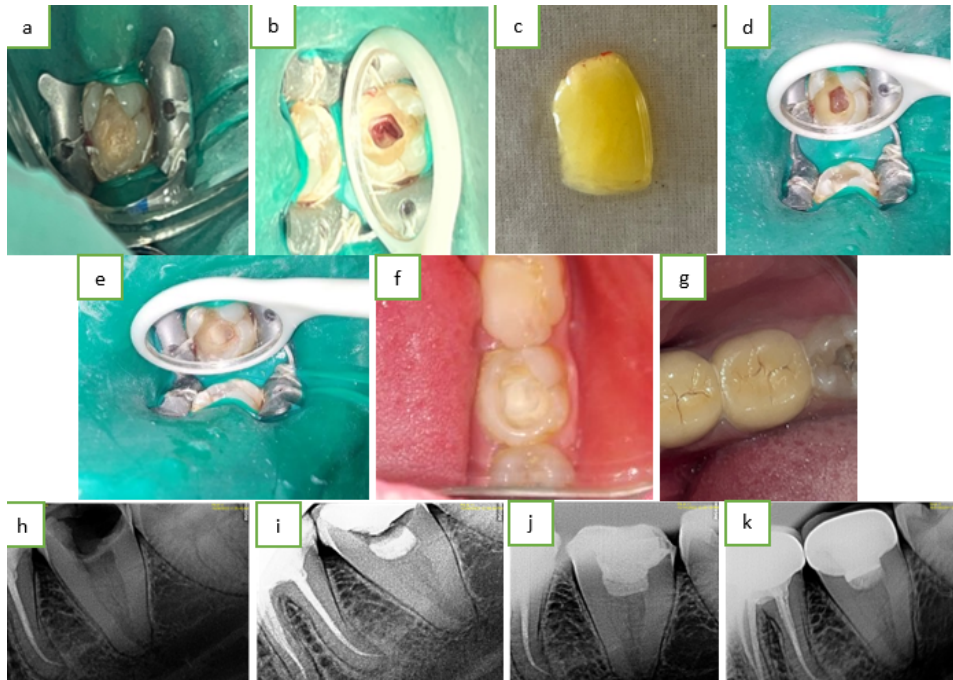


Fig. 2: a: Tooth under rubber dam isolation; b: After full coronal pulpotomy; c: PRF; d: PRF placed in canal orifice; e: Biodentine™ placed over PRF; f: Endo crown preparation retaining required amount of GIC; g: Endo crown irt 36; h: Preoperative radiograph; i: Radiograph after PRF and Biodentine placement; j: 12 months follow-up radiograph; k: after Endo crown placement

Table 1: Zanini et al criteria¹⁶

Outcome of pulpotomy	Radiographic criteria
Success, effective pulpotomy	PAI at T0 = 1 and PAI at Tx = 1 PAI at T0 = 2 and PAI at Tx ≤ 2 PAI at T0 ≥ 3 and PAI at Tx ≤ 2 and lack of radicular lacunae
Uncertain outcome	PAI at T0 = 1 and PAI at Tx = 2 PAI = 3 at both T0 and Tx and lack of radicular lacunae
Failure, infective pulpotomy	PAI at T0 = 1 or 2 and PAI at Tx ≥ 3 PAI at T0 ≥ 3 and PAI at Tx > 3 and / or presence of radicular lacunae.

Table 2: PAI (ostavik et al 1986)¹⁷

Score	Criteria
1	Normal periapical structures
2	Small changes in bone structure
3	Changes in bone structure with mineral loss
4	Periodontitis with well-defined radiolucent area
5	Severe periodontitis with exacerbating features

PAI (Periapical index); T0: date of treatment; Tx: longest follow – up times (T1, T2, T3)

In the current case, an effort was made to use such growth factors to help in repair of a tooth with pulpitis. As discussed earlier, PRF was prepared with the patient's own blood and was placed in the pulp chamber after a pulpotomy procedure. A layer of Biodentine™ was placed over PRF and the final restoration of glass-ionomer cement was placed immediately. Also a double coronal seal was created to eliminate microleakage. At 1, 3, 6 and 12 months, the patient was recalled for evaluation, tooth was asymptomatic and radiographically intact PDL & lamina dura was seen.

After full pulpotomy and coronal seal with PRF and Biodentine™, the teeth were restored with GIC and kept under observation for 12 months, later Endo crown was chosen to reinforce the extensively damaged tooth as the teeth in both cases were grossly destructed coronally. Usually for the grossly destructed teeth the conventional non-surgical endodontic treatment followed by placement of post used to be the treatment approach irrespective of pulpal involvement. This conventional procedure may lead to unnecessary removal of vitality of tooth leading to loss of proprioception to the patient and also overall life span of tooth in the arch is reduced as the root canal treated tooth becomes brittle over a period of time. So in this case report to overcome these problems an attempt was made to maintain the vitality of the teeth at the same time providing strength and reinforcement to the teeth by using Endo crown as an alternative treatment option other than placement of post in the canal. Biacchi and Basting in 2012 compared the compression forces of traditional crown with fibre post and Endo crown and found more favourable results with

endocrown.¹⁵ Several in vitro studies have proven the validity of bonded Endo crown with conventional crowns. Endo crowns are relatively new, easy and less appointments needed to finish the treatment. It has several advantages like less number of interfaces in the restorative system. Preparation design is conservative and biologic width is minimal. The Endo crown fits perfectly with the concept of bio integration and can serve as a most conservative and aesthetic option for restoration of grossly decayed posterior tooth.

Success assessment of vital pulp therapy is based on clinical and radiographic follow-up. The tooth should be asymptomatic. The tooth with full pulpotomy is expected to be unresponsive to sensibility testing. Zanini et al proposed a criteria for the evaluation of the outcome of pulpotomy (table), according to this criteria the two cases presented in this report shows successful outcome and effective pulpotomy. Success is defined as the absence of symptoms and maintenance of pulp vitality after at least 1 year.

4. Conclusion

In accordance to the favorable results of present cases, a reasonable argument supporting mature tooth pulpotomy in cases of extensively destructed teeth can be stated. Biomaterials such as, Biodentine™ with pulp healing properties and PRF may challenge the complete philosophy of our conventional endodontic procedure. Case selection including age, status of pulp and control of bleeding; however, remains an important criterion for the same.

Source of Funding

None.

5. Conflicts of interest

There are no conflicts of interest.

References

1. Taha NA, Abdelkhalder SZ. Outcome of full pulpotomy using Biodentine in adult patients with symptoms indicative of irreversible pulpitis. *Int Endod J.* 2018;51:819–28. doi:10.1111/iej.12903.
2. Bjørndal L, Reit C, Bruun G, Markvart M, Kjaeldgaard M, Näsman P, et al. Treatment of deep caries lesions in adults: Randomized clinical trials comparing stepwise vs. direct complete excavation, and direct pulp capping vs. partial pulpotomy. *Eur J Oral Sci.* 2010;118(3):290–7. doi:10.1111/j.1600-0722.2010.00731.x.
3. Wolters W, Duncan H, Tomson P, Karim I, McKenna G, Dorri M, et al. Minimally invasive endodontics: A new diagnostic system for assessing pulpitis and subsequent treatment needs. *Int Endod J.* 2017;50(9):825–9.
4. Stashenko P, Teles R, Souza R. Periapical inflammatory responses and their modulation. *Crit Rev Oral Biol Med.* 1998;9(4):498–521.
5. Taha NA, Abdelkhalder SZ. Outcome of full pulpotomy using Biodentine in adult patients with symptoms indicative of irreversible pulpitis. *Int Endod J.* 2018;51(8):819–28. doi:10.1111/iej.12903.
6. Tran XV, Salehi H, Truong MT, Sandra M, Sadoine J, Jacquot B, et al. Reparative mineralized tissue characterization after direct pulp capping with calcium-silicate-based cements. *Materials (Basel).* 2019;12(13):2102. doi:10.3390/ma12132102.

7. Tran XV, Gorin C, Willig C, Baroukh B, Pellat B, Decup F, et al. Effect of a calcium-silicate-based restorative cement on pulp repair. *J Dent Res.* 2012;91(12):1166–71. doi:10.1177/0022034512460833.
8. Giraud T, Jeanneau C, Bergmann M, Laurent P. Tricalcium Silicate Capping Materials Modulate Pulp Healing and Inflammatory Activity In Vitro. *J Endod.* 2018;44(11):1686–91. doi:10.1016/j.joen.2018.06.009.
9. Massler M. Preserving the exposed pulp: A review. *J Pedod.* 1978;2(3):217–27.
10. Atmeh A, Chong E, Richard G, Festy F, Watson T. Dentin-cement interfacial interaction: Calcium silicates and polyalkenoates. *J Dent Res.* 2012;91(5):454–9. doi:10.1177/0022034512443068.
11. Ha HT. The effect of the maturation time of calcium silicate-based cement (Biodentine™) on resin bonding: An in vitro study. *Appl Adhes Sci.* 2019;7:1–13. doi:10.1186/s40563-019-0118-7.
12. Pradelle-Plasse N, Tran XV, Colon P, Laurent P, Aubut V, About I, et al. Emerging trends in (bio) material research. In: *Biocompatibility or Cytotoxic Effects of Dental Composites.* Oxford, UK: Coxmoor Publishing Company; 2009. p. 181–203.
13. Raja S, Naidu EM. Platelet-rich fibrin: evolution of a second-generation platelet concentrate. *Indian J Dent Res.* 2008;19(1):42–6. doi:10.4103/0970-9290.38931.
14. Smith AJ. Vitality of the dentin-pulp complex in health and disease: growth factors as key mediators. *J Dent Educ.* 2003;67:678–89.
15. Biacchi GR, Basting RT. Comparison of fracture strength of endocrowns and glass fiber post-retained conventional crowns. *Oper Dent.* 2012;37(2):130–6.
16. Zanini M, Hennequin M, Cousson PY. A Review of Criteria for the Evaluation of Pulpotomy Outcomes in Mature Permanent Teeth. *J Endod.* 2016;42(8):1167–74. doi:10.1016/j.joen.2016.05.008.
17. Ørstavik D, Kerekes K, Eriksen HM. The periapical index: A scoring system for radiographic assessment of apical periodontitis. *Dent Traumatol.* 1986;2(1):20–34. doi:10.1111/j.1600-9657.1986.tb00119.x.

Author biography

Kanike Keerthi Viswa Teja, Post Graduate Student
 <https://orcid.org/0000-0002-7883-6073>

Purushotham R, Professor

Samrat M.R, Professor and HOD

Sujith R, Professor

Kavita G, Reader

Cite this article: Teja KKV, Purushotham R, Samrat M.R, Sujith R, Kavita G. Partial endodontic procedure..boom!! *IP Indian J Conserv Endod* 2023;8(1):52-57.