

Content available at: <https://www.ipinnovative.com/open-access-journals>

IP Indian Journal of Conservative and Endodontics

Journal homepage: <https://www.ijce.in/>

## Review Article

# Management of root canal curvatures and review

Suveksha Sahay<sup>1,\*</sup>, Shalya Raj<sup>1</sup>, Vineeta Nikhil<sup>1</sup>

<sup>1</sup>Dept. of Conservative and Endodontics, Subharti Dental College and Hospital, Meerut, Uttar Pradesh, India



### ARTICLE INFO

#### Article history:

Received 20-04-2023

Accepted 06-05-2023

Available online 25-05-2023

#### Keywords:

Curvatures

Precurved files

Endodontic treatment

Root canal anatomy

Dilaceration

### ABSTRACT

A successful endodontic treatment depends upon proper instrumentation and irrigation. Presence of severe curvatures along the length of the root affects the treatment outcome. Hence it is necessary to know the severity of the root canal curvature to select the instrument and instrumentation technique precisely. The different degree of curvatures can also lead to various iatrogenic errors like ledge formation, separation of instruments, perforation, and canal blockage or teardrop transportation at the apex, therefore reducing the success of the treatment. Hence managing these curvatures becomes an essential part of the treatment plan. This paper reviews determination of root canal curvatures and their management.

This is an Open Access (OA) journal, and articles are distributed under the terms of the [Creative Commons Attribution-NonCommercial-ShareAlike 4.0 License](https://creativecommons.org/licenses/by-nc-sa/4.0/), which allows others to remix, tweak, and build upon the work non-commercially, as long as appropriate credit is given and the new creations are licensed under the identical terms.

For reprints contact: [reprint@ipinnovative.com](mailto:reprint@ipinnovative.com)

## 1. Introduction

Endodontic therapy involves treating vital and necrotic dental pulp enabling patients to retain their natural tooth in function and esthetics.<sup>1</sup> It consists of different stages including access cavity preparation, instrumentation, irrigation and obturation of root canal system which can all be influenced by root canal curvature.<sup>2</sup> Although successful therapy depends on many factors, one of the most important steps in any root canal treatment still remains canal preparation since it affects proper debridement, creation of space and also maintains the desired the geometry of the canal for adequate obturation.<sup>1</sup>

The probability of encountering a tooth with a straight root or canal is very minimal. It is an exception rather than being normal. The straight roots are also found to have severely curved canals or multiple planes of curvature throughout their length. Tomes, in 1848, called such curvatures as “dilacerations.” It refers to an angulation or a sharp bend in the root or crown of formed tooth or a deviation in the linear relationship of a crown of a

tooth to its root.<sup>3</sup> The abrupt change caused in the axial inclination between crown and root due to any reason can ultimately result in a form of developmental anomaly known as dilaceration.<sup>4</sup> It might present in various ways including non-eruption of the affected tooth, prolonged retention of the primary predecessor tooth and apical fenestration of the labial cortical plate or it can be asymptomatic.<sup>5</sup> A wide range of variability in root anatomy is found in certain roots or teeth. A literature review by Hartmann *et al* reported that 84% of teeth exhibit a noticeable degree of dilacerations.<sup>6</sup> This is seen in both permanent and deciduous dentitions having more prediction for maxillary arch and in posterior region. In particular, certain roots seem to have a propensity for an S-shape configuration with one of the most prominent and challenging anatomies being found in maxillary second premolars.<sup>7</sup>

The various procedural errors occurring while any endodontic include ledge formation, fractured instruments, blockage of the canal, zipping or elbow creation. The controlled regularly tapered preparation of the curved canals is the ultimate challenge in endodontics.<sup>8</sup> Therefore, several instrumentation techniques have been introduced to deal

\* Corresponding author.

E-mail address: [sssuvksha545@gmail.com](mailto:sssuvksha545@gmail.com) (S. Sahay).

with it. In order to effectively manage these bends, it is essential to have a complete understanding of the internal anatomy of the tooth along with assessing the preoperative radiographs in detail. In addition to this, considering the hand files for negotiating the bends first and then using rotary files is essential. Appropriate instrumentation techniques and customized treatment planning will help manage it, prevent complications and enhance the quality of the treatment.<sup>9</sup>

The core objective of any endodontic treatment is to thoroughly clean the root canals and shape them properly thereby reducing the microbial load and disinfecting it.<sup>10</sup> The success of the procedure greatly depends on the presence of root canal curvatures and calcifications. Several authors have even listed this as a risk factor affecting the outcome of a successful endodontic treatment. The level of the complexity of the case, the risk of procedural accidents and hence the need of specialized management can be determined as per guidelines issued by American Association of Endodontics in the year 2010. Before initiation of the treatment, thorough knowledge about the anatomy of the root and degree of curvature of canals is must.<sup>11</sup>

### 1.1. Classification of root canal curvatures<sup>12</sup>

The root canal curvature can be classified in different manner:

#### 1.1.1. According to anatomic location

1. Apical third curvature
2. Middle third curvature
3. Coronal third curvature

#### 1.1.2. Schneider's classification

1. Straight (if angle <5°)
2. Moderately curve (if the angle is 10-20°)
3. Severely curve (if the angle is > 20°)

#### 1.1.3. Dobo-Nagy classification

1. Shape (straight)
2. J-shape (apical curve)
3. C-shape (entirely curve)
4. S-shape (multi-curve)

#### 1.1.4. Radius based curvature

1. Severely curved (r >4mm)
2. Moderately curved (r= 4mm-8mm)
3. Curvature (r= 8mm)

#### 1.1.5. Shape-based curvature

1. Apical gradual curve
2. Sickle shape curve
3. Bayonet curve

### 4. Dilacerated curve

Methods to identify root canal curvatures

The commonly used methods to identify these curvatures are:

#### 1.2. Periapical radiograph

Periapical radiographs are most commonly used during root canal therapy worldwide because of being convenient and inexpensive. However, analysing a 3-D object in 2-D plane is difficult hence the buccolingual curvatures are sometimes not assessed properly. Therefore, pre-treatment diagnosis cannot solely depend on these radiographs.<sup>8</sup>

#### 1.3. Cone beam computed tomography

CBCT is a new advancement in the field of radiology and is used for detailed 3D imaging of oral and maxillofacial structure. The radius of root curvature can be determined by CBCT by measuring it with Planimp software (CDT Informatics, Cuiaba, MT, Brazil, 3D imaging system) based on the 3 mathematical points. CBCT provides a better view of the morphology of the root canal than a radiograph.<sup>2</sup> (Figure 1)

#### 1.4. Schneider's method

In this method, a centre point is marked on the file at the level of the canal orifice. A straight line is drawn parallel to the image labelling it as point A. Point B is marked where the flare starts to deviate and point C lies at the apical foramen. The intersection of these lines results in formation of an angle which is measured. Straight canal is determined by having angle less than 5°, moderately curved is classified when the angle is 5-20° and lastly for angle greater than 20°, the canal is termed as a severely curved.<sup>12</sup> (Figure 2)

#### 1.5. Lutein method

Lutein method is the modification of the Schneider's method. Here four geometric points are taken and two lines are drawn by identifying these points. First point A is marked at the center of the canal orifices and then at 2mm below the orifice, point B is marked. Joining of point A and point B forms the first primary line and then point C lies at 1 mm coronal to the apical foramen. At the apical foramen point D is marked, then a second primary line is drawn joining these two lines. The angle formed by intersection of the two lines is measured as in the Schneider method.<sup>8</sup> (Figure 3)

#### 1.6. Weine's method

Weine provided a different approach for calculating the curvatures. Although comparable to Schneider's approach, this method revealed various variations in angles depending

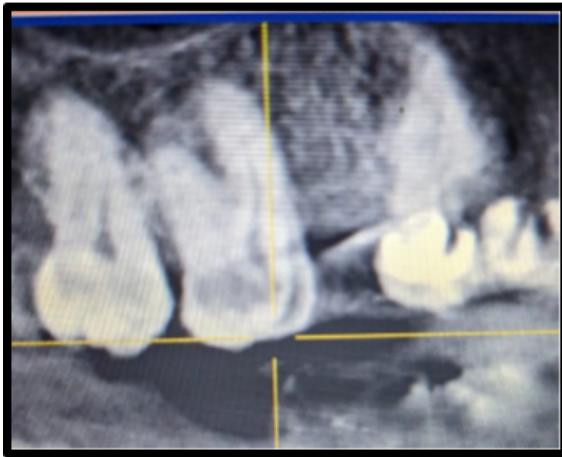


Fig. 1: CBCT for determination of root canal curvature.

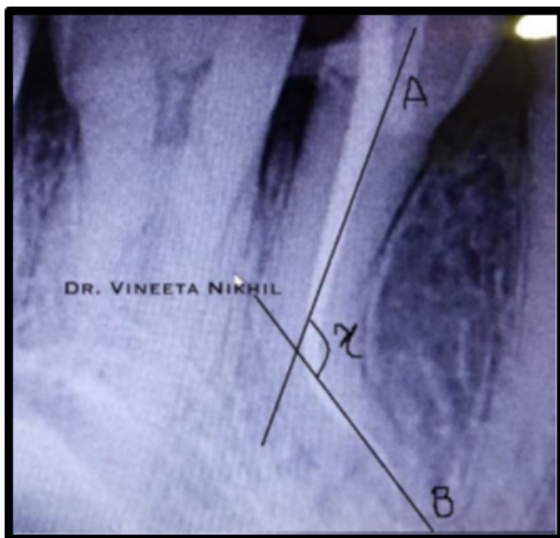


Fig. 2: Diagrammatic representation of Schneider's method.

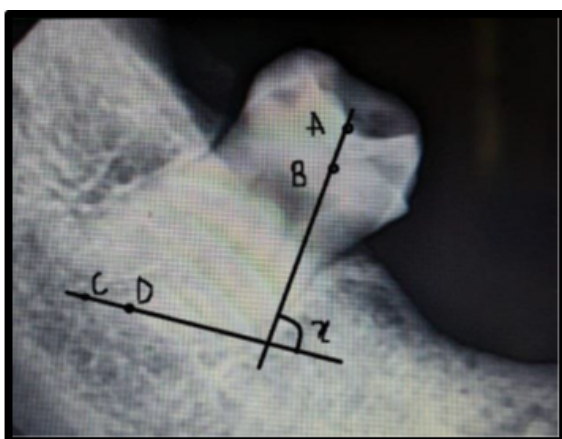


Fig. 3: Diagrammatic representation of Lutein method.

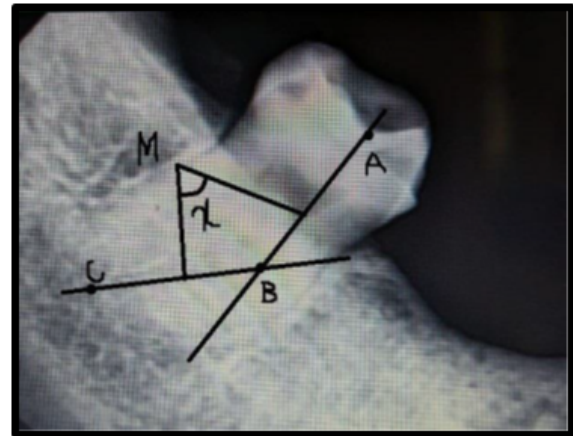


Fig. 4: Diagrammatic representation of Weine's method.

on the canal's curvature. This approach involves drawing a straight line from the canal orifices to the point of curvature, another line from the apex for the apical curvature, and measuring the angle at the junction of the two lines.<sup>8</sup> (Figure 4)

## 2. Management of Root Curvatures

There are two ways by which the curved curvatures can be managed:

1. Decreasing the restoring force that causes bending of the file which can be done by the following:
  - (a) Precurving the file: Either by placing a gradual curve or a sharp bend of nearly 45° at the apical end of the instrument.
  - (b) Extravagant use of smaller number files as they can follow canal curvature: Smaller files are more flexible enabling them to negotiate the canal without force.
  - (c) Use of intermediate size of files: The use of intermediate files ensures a smooth transition while preparing the canals enabling smoother cutting in cases of curved canals.
  - (d) Use of flexible files: They maintain the shape of the curve and avoid errors.
2. Decreasing the length of the file which is actively cutting that can be achieved by the following ways:
  - (a) Anti-curvature filing: The controlled and directed preparation into safety zones and away from the thinner portions or danger zones of the root structure where perforation or stripping of the canal walls can occur is known as anti-curvature filing. Hence this method maintains the integrity of canal walls at their thin portion and reduces the possibility of root perforation or stripping.

- (b) Modifying cutting edges of the instrument by dulling the flute on outer surface of apical third and inner portion of middle third which can be done by diamond file.
- (c) Modifying the crown-down approach for canal preparation. As a result, a narrow canal shape is formed, enabling adequate irrigant access and lowering the possibility of debris extrusion at the apex.<sup>3</sup>

### 2.1. Managing apical curvatures

The apical part of the tooth is mostly curved and it is important to state that an attempt to straighten it should not be made or else treatment failure in form of errors like direct perforation, ledge formation and creation of teardrop foramen or foraminal rip can occur. Gaining a straight-line access to the canals is the best method recommended to avoid the occurrence of all these misfortunes.<sup>13</sup> After an access cavity is prepared, the root canal preparation should be started with stainless steel files of smaller diameter with light passive movement. The diameter of the glide path is then increased with nickel-titanium (NiTi) hand files. The files can be precurved in the direction of apical curvature by placing an extremely sharp curve near the tip of instrument. This is used when the preoperative radiograph discloses a sharp apical dilacerations or when an obstruction is encountered. Alternatively, a gradual bend can also be given for entire length of the flutes.<sup>2</sup> Also, a chelating agent such as ethylenediaminetetraacetic acid (EDTA) must be used, along with copious irrigation of the canals with sodium hypochlorite allowing easy removal of the debris. Once a file is withdrawn from the canal, it must be cleaned and recurved before reintroducing it.<sup>8</sup>

### 2.2. Managing middle curvatures

Management of middle curvatures are found to be difficult. This becomes more challenging if the coronal third is straight that increases the chances of iatrogenic errors. Two steps should be followed for better management of mid-root curvature. Adequate access and good coronal third preparation. This ensures greater volume of irrigants reaching the mid-portion of the canal, facilitates proper instrumentation thus creating an ideal platform for preparation. After preparing the coronal third portion, the mid-portion is prepared using pre-curved files providing the required glide path. The bend given on the file should be gentle as sharp acute bends increase the probability of file fracture.<sup>14</sup>

### 2.3. Management of s-shaped canals

In general, there are two sets of instruments used in curved and constricted canals. Instruments that are manipulated by hand (manual instruments) and instruments that are

mounted in an engine-driven motor (engine-driven).<sup>11</sup>

## 3. Traditional Technique

While using the traditional approach of cleaning and shaping of S-shaped root canals with hand stainless steel instruments following guidelines should be followed:

Visualise mentally the 3-D nature of the canal with the help of radiographs.

Anticipate the presence of multiple concavities or invaginations along the external surface of the roots to prevent strip perforations.

Develop an unrestricted approach to the first or coronal curve with an Endo Z bur by skewing the access preparation to mesial or distal if necessary.

Shape the coronal portion passively that facilitates proper cleaning and shaping of any other curvatures present with simultaneous irrigation and recapitulation.

Overcurve the apical 2 to 3mm stainless steel file to maintain the curvature of the apical curvature of the canal. In this process the master apical file should be smaller size range and smaller file size are used in this middle-to apical region with short amplitude strokes to manage these anatomical challenges effectively and to prevent stripping, zipping and ledging in the root curvatures.<sup>7</sup>

## 4. Contemporary Technique

When using NiTi rotary files for managing severe curvature, both the angle and radius of the root curvature are extremely important. Once penetration and shaping are done around the first curve, additional penetration can occur to the second curve or slightly beyond that anatomical challenge. This can be done with small K files, small variably tapered NiTi instruments or instruments specifically designed for this purpose. After this there is usually sufficient space to enhance the use of irrigants for tissue dissolution and disinfection, although the irrigant may not always fully penetrate until larger apical files are used or there is sufficient coronal flaring. Instruments such as variable tapered S1, SX and S2 of the ProTaper universal series are exceptionally effective at creating a tapered path with minimal to no deviation in the curves of these canals due to the location of the cutting on the instrument with no cutting apical portion serving as the pathfinder. Some of the newer rotary NiTi files, such as Sequence file, the Twisted file, the GTX file and Vortex file and LightSpeed may be used effectively in small sizes (15-20).<sup>7</sup>

## 5. Conclusion

The presence of canal curvatures and constrictions have shown to increase the difficulties during root canal preparation thus decreasing the success rate of any endodontic treatment. The factors determining the success in negotiating these canals depends on the size and

construction of the canal, degree of curvature, size and flexibility of the instrument, along with the skills of the operator.<sup>8</sup> Therefore, a thorough knowledge of the tooth's internal anatomy, appropriate instrumentation techniques and individual treatment planning depending on the degree of curvature are helpful to treat curved canals, avoid complications thus improving the quality of the treatment.<sup>15</sup>

## 6. Conflicts of Interests

The authors have no financial interests or conflicts of interests.


## 7. Source of Funding


None.

## References

- Peters OA. Current challenges and concepts in the preparation of root canal systems: A review. *J Endod.* 2004;30(8):559–67. doi:10.1097/01.don.0000129039.59003.9d.
- Hema BS, Saxena R, Agrawal KD. Methods to determine root canal curvatures and its managements. *J Res Adv Dent.* 2020;10(2):126–32.
- Ansari I, Maria R. Managing curved canals. *Contemp Clin Dent.* 2012;3(2):237–41.
- Jafarzadeh H, Abbott PV. Dilaceration: review of an endodontic challenge. *J Endod.* 2007;33(9):1025–30.
- Kilpatrick NM, Hardman PJ, Welbury RR. Dilaceration of a primary tooth. *Int J Paediatr Dent.* 1991;1(3):151–3.
- Nasher R, Hilgers RD, Gutknecht N. Debris and smear layer removal in curved root canals using the dual wavelength Er, Cr: YSGG/diode 940 nm laser and the XP-endoshaper and finisher technique. *Photobiomodul Photomed Laser Surg.* 2020;38(3):174–80.
- López-Ampudia N, Gutmann JL. Management of „S-shaped“ root canals technique and case report. *ENDO.* 2011;5(1):7–15.
- Balani P, Niazi F, Rashid H. A brief review of the methods used to determine the curvature of root canals. *J Res Dent.* 2015;3(3):57–63.
- Hegde MN, Lagiseti AK, Honap MN. Negotiating the bends: an endodontic management of curved canals-A case series. *J Endod.* 2017;29(2):160–75.
- Nagy CD, Bartha K, Bernath M, Verdes E, Szabo J. The effect of root canal morphology on canal shape following instrumentation using different techniques. *Int Endod J.* 1997;30(2):133–40.
- Chanotis A, Ordinola-Zapata R. Present status and future directions: management of curved and calcified root canals. *Int Endod J.* 2022;55(9):656–84.
- Patil BS, Ali A, Ts IS, Kamatagi L. Methods used to determine the curvature of root canals: A review. *Int J Pure Med Res.* 2020;5(4):1–5.
- Segal M. Managing curved canals: The straightaway and super glide path technique. *Inside Dent.* 2008;4(4):78–83.
- Bogle J. Endodontic treatment of curved root canal systems. *Oral Health.* 2013;89(8):103–10.
- Chowdhury D, Bhaumik T, Desai P, Das UK. Endodontic management of maxillary first premolar with S-shaped canals. *Imp J Interdiscip Res.* 2017;3(2):1538–40.

## Author biography

**Suveksha Sahay**, Post Graduate Student  <https://orcid.org/0009-0005-4693-5586>

**Shalya Raj**, Professor  <https://orcid.org/0000-0003-0811-2536>

**Vineeta Nikhil**, Professor and Head  <https://orcid.org/0000-0003-3954-5676>

**Cite this article:** Sahay S, Raj S, Nikhil V. Management of root canal curvatures and review. *IP Indian J Conserv Endod* 2023;8(2):69-73.