

Content available at: <https://www.ipinnovative.com/open-access-journals>

IP Indian Journal of Conservative and Endodontics

Journal homepage: <https://www.ijce.in/>

Case Report

Endodontic management of six canalled maxillary first molar: A case report

Roma Kotia^{1,*}, Sanjay Chhabra¹, Peeyush Pathak¹, Seema Chaudhary¹,
Shubham Goyal¹

¹Dept. of Conservative Dentistry and Endodontics, Army Dental Centre (R&R), Delhi Cantt, New Delhi, India



ARTICLE INFO

Article history:

Received 03-02-2023

Accepted 10-04-2023

Available online 25-05-2023

Keywords:

Maxillary molar

Anatomic variation

Endodontic management

ABSTRACT

The clinical management of a maxillary first molar with six root canals is described in this case report having two canals in the mesiobuccal root (MB), two canals in the distobuccal root (DB), and two canals in the palatal root (P). The prevalence of such a complex internal anatomy of teeth is a rare variation. The endodontic management of such deviant canal morphology can be challenging to diagnose and treat. For proper management of such unusual cases, it is essential to have sound knowledge of the intricacies of the anatomy and additional canals. Hence, it is imperative to record such cases in dental literature.

This is an Open Access (OA) journal, and articles are distributed under the terms of the [Creative Commons Attribution-NonCommercial-ShareAlike 4.0 License](https://creativecommons.org/licenses/by-nc-sa/4.0/), which allows others to remix, tweak, and build upon the work non-commercially, as long as appropriate credit is given and the new creations are licensed under the identical terms.

For reprints contact: reprint@ipinnovative.com

1. Introduction

In-depth knowledge of the structure of the root canal and its anatomic variations is an indispensable prerequisite to achieving successful clinical outcomes of NSRCT.¹ Failure to detect or treat additional canals than normally encountered is the major reason for failed root canal treatment.² Amongst all the permanent teeth, maxillary permanent molars have the maximum rate of NSRCT failure due to the associated complex structure and variations in the anatomy.^{3,4}

The first maxillary molar consists of three roots and three root canals having a fourth canal (MB2) in 50.4–91.1% of cases^{5–7} although the presence of additional distal and palatal canals is an uncommon finding.^{8,9} It is imperative that such aberrations are documented to enhance the knowledge base and empower clinicians to be aware of the existence of such variations and the possibility to encounter them.

* Corresponding author.

E-mail address: romakotia@gmail.com (R. Kotia).

2. Case Report

A 17-year-old male patient reported to the Department of Conservative Dentistry and Endodontics at Army Dental Centre R & R, New Delhi, with severe pain in his right upper back tooth region for one week. The pain was spontaneous, throbbing, radiating to the right ear, and aggravated by a change of posture. Taking analgesics initially relieved it, but its efficacy was reduced gradually. The patient was mentally disabled and was undergoing speech therapy at R & R Hospital. On clinically examining the patient, it was ascertained that the patient had deep proximal caries in the right maxillary first molar. The tooth was moderately tender to palpation and percussion, mobility was within physiological limits with a healthy periodontium. Cold test (Endo Frost, Roeko, Langenau, Germany) and the electric pulp test (Parkel electronics division, Farmingdale, NY, USA) produced an early painful response. Diagnosis of Acute Irreversible Pulpitis with Apical Periodontitis was made and endodontic therapy of the tooth was planned. (Figure 1)

Root canal treatment was initiated on the same sitting by anesthetizing the offending tooth using 1.8 ml of 2%

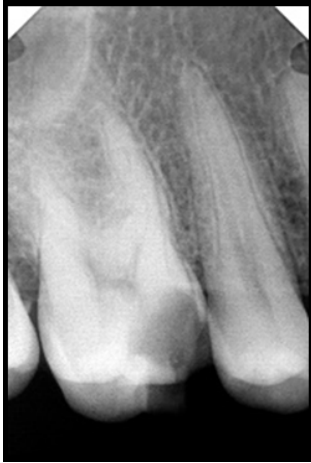

Fig. 1: Pre-operative radiograph

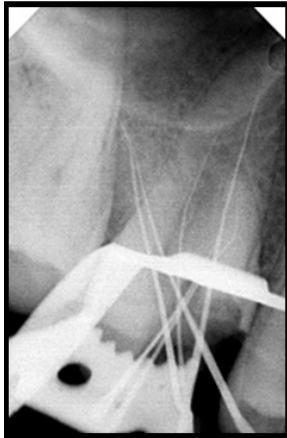


Fig. 2: Working length radiograph

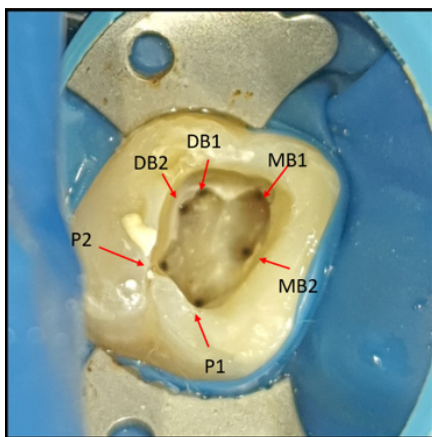


Fig. 3: Modified access preparation and orifice location

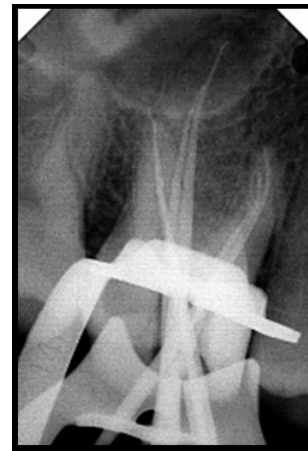

Fig. 4: Master cone radiograph

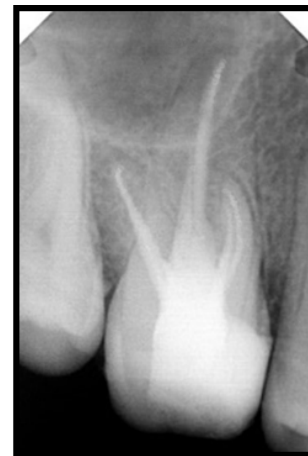

Fig. 5: Post-obturation radiograph

lignocaine comprising 1:200,000 epinephrine (Xylocaine; Astra Zeneca, Bangalore, India) under rubber dam isolation. Caries was excavated using a number 2 round bur in a slow-speed handpiece, following which the pulp chamber was deroofed.

After access preparation, the orifices of the mesiobuccal (MB), distobuccal (DB), and palatal (P) canals were located and negotiated. Ultrasonic tips (sonic scaler tip #1 universal, American Distance Education Consortium (ADEC), USA) were used for troughing after which MB2 and DB2 were also located and the straight line access was established. Moreover, another canal in the palatal direction was noticed and therefore the access preparation was further modified and the second palatal canal was effectively negotiated. The orifices were located under magnification using DG-16 explorer (Hu-Friedy, Chicago, USA), and with the help of gates-glidden drills no. 2 and 3, coronal flaring was done to improve the accessibility. (Figure 3) Using K-flex files patency was maintained and working length was determined with help of an electronic apex locator (Root ZX; Morita,

Tokyo, Japan). After which the initial hand filing till #20 was done in all the root canals. The working length in each root canal was confirmed radiographically.(Figure 2)

The root canals were then completely filled with calcium hydroxide (Calcipulp, Specialites Septodont, Saint-Maur, France) and an intermediate restoration was placed (Cavit, ESPE, Seefeld, Germany). The patient was recalled for further treatment after a week. The root canals were then prepared with ProTaper Gold nickel-titanium rotary instruments (Dentsply-Maillefer, Ballaigues, Switzerland) with the master apical file size of F2 for MB1, MB2, DB1, DB2, and F3 for P1, P2. Copious irrigation with sodium hypochlorite (Prime Dental Products, Thane) was done during the shaping and cleaning procedure of the canals followed by final irrigation with 17% EDTA (Premier Dental Products) after which the root canals with the help of paper points (Dentsply Maillefer) were completely dried followed by master cone radiograph (\$) followed by lateral compaction technique of obturation with gutta-percha (Dentsply Maillefer). Post-obturation radiograph is shown in Figure 5. The patient could not report for follow-ups as his family got shifted to his paternal village after the completion of the treatment.

3. Discussion

Anatomical anomalies are commonly detected in the maxillary first molar ranging from one to seven canals.¹⁰ In literature, several cases have been reported with varying root canal configurations from one to eight roots as well.¹¹ Hence, the detection of additional canals, using various diagnostic aids which must be considered when planning for endodontic treatment.¹²

Studies done on maxillary first molars have reported the highest incidence of the second mesiobuccal canal (18.6%–96.1%), followed by mesiopalatal (56.8%), then second distobuccal (1.6%–9.5%), and the least distopalatal (1.7%) canals.¹³ Locating and then disinfecting these extra canals are challenging and depend on many factors. The various methods employed to explore extra canal orifices, such as magnifying loupes and surgical operating microscopes with illumination have been used for this purpose. The chamber floor is to be thoroughly examined using a DG16 explorer, ultrasonic tips for troughing, dyes such as 1% methylene blue for staining the floor, and sodium hypochlorite for champagne bubble test, are the routinely advocated methods for finding extra canal orifices.¹⁴ The eccentric placement of a file on a radiograph also indicates the possibility of an extra canal. In the present case.¹⁵

For a successful identification and negotiation of the rare anatomy of root canals, proper access opening with various modifications in the shape of the access preparation to discover all the root canal orifices. Similarly in the present case report, the traditional triangular shape of access was modified to a trapezoidal shape to expand access to the

additional root canals. The configuration of the root canal found in the palatal root can be classified as Vertucci Type IV, in which two canals in a single root have discrete apical foramen. The existing literature reports mainly document either Vertucci Type IV or Type V root canal configuration where two separate orifices exist in the maxillary palatal root.¹⁰ As per the literature, this case also showed the presence of an MB2 canal, the incidence of which ranges from 56.8% to as high as 90%. The tooth had a Vertucci Type II morphology in its mesial root, the most common configuration in that particular root of the maxillary first molars.

The concurrent incidence of dual canal systems in all three roots of maxillary first molars is an uncommon finding. Hence, a thorough familiarity with root and root canal morphology and a good anticipation of their likely morphological disparities is crucial and will help in reducing endodontic failures caused by inadequate root canal preparation and obturation. Thus, it is imperative to be aware of the occurrences of variations, and various armamentaria, discussed above can be successfully employed to identify and manage such variations.

4. Conflicts of Interests

The authors have no financial interests or conflicts of interests.

5. Source of Funding


None.

References


- Zhang ZH, Yao HL, Zhang Y, Wang X. Endodontic management of the maxillary first molar with special root canals: A case report and review of the literature. *World J Clin Cases*. 2020;8(12):2590–6.
- Vertucci FJ. Root canal morphology and its relationship to endodontic procedures. *Endod Topics*. 2005;10(1):3–29.
- Lee KW, Kim Y, Perinpanayagam H, Lee JK, Yoo YJ. Comparison of alternative image reformatting techniques in micro-computed tomography and tooth clearing for detailed canal morphology. *J Endod*. 2014;40(3):417–22.
- Karobari MI, Arshad S, Noorani TY, Ahmed N, Basheer SN, Peeran SW, et al. Root and Root Canal Configuration Characterization Using Microcomputed Tomography: A Systematic Review. *J Clin Med*. 2022;11(9):2287. doi:10.3390/jcm11092287.
- Maggiore F, Jou YT, Kim S. A six-canal maxillary first molar: case report. *Int Endod J*. 2002;35(5):486–91.
- Ahmad IA, and AAJ. Three root canals in the mesiobuccal root of maxillary molars: case reports and literature review. *J Endod*. 2014;40(12):2087–94.
- Buhrley LJ, Barrows MJ, Begole EA, Wenckus CS. Effect of magnification on locating the MB2 canal in maxillary molars. *J Endod*. 2002;28(4):324–7.
- Kaushik M, Mehra N. Maxillary first molars with six canals diagnosed with the aid of cone beam computed tomography: a report of two cases. *Case Rep Dent*. 2013;20(13):406923. doi:10.1155/2013/406923.
- Filho FB, Zaitter S, Haragushiku GA, De Campos E, Abuabara A, Correr GM, et al. Analysis of the internal anatomy of maxillary first molars by using different methods. *J Endod*. 2009;35(3):337–42.


10. Madhumar M, Radhakrishnan NK, Geetha P. Endodontic Treatment of Maxillary First Molar with Six Canals Using Dental Operating Microscope and Cone-beam Computed Tomography: A Case Report. *Cons Dent Endod J.* 2020;5(1):15–8. doi:10.5005/jp-journals-10048-0055.
11. Almeida G, Machado R, Cunha RS, Vansan LP, Neelakantan P. Maxillary first molar with 8 root canals detected by CBCT scanning: a case report. *Gen Dent.* 2015;63(2):68–70.
12. Zurawski AL, Lambert P, Solda C, Zanesco C, Reston EG, Barletta FB, et al. Mesiolingual Canal Prevalence in Maxillary First Molars assessed through Different Methods. *J Contemp Dent Pract.* 2018;19(8):959–63.
13. Jorge NR, Duarte M, Emmanuel JN, Caramês J, Mata A, Versiani M, et al. Second Mesio Buccal Root Canal in Maxillary Molars: A Systematic Review and Meta-Analysis of Prevalence Studies using Cone Beam Computed Tomography. *Arch Oral.* 2020;13:104589. doi:10.1016/j.archoralbio.2019.104589.
14. Verma P, Love RM. A Micro CT study of the mesio buccal root canal morphology of the maxillary first molar tooth. *Int Endod J.* 2011;44(3):210–7.
15. Garg AK, Tewari RK, Kumar A, Agrawal N. Endodontic treatment of a maxillary first molar having three mesio buccal canals with the aid of spiral computed tomography: a case report. *J Oral Sci.* 2010;52(3):495–9.

Author biography

Roma Kotia, Resident  <https://orcid.org/0009-0005-0482-4853>

Sanjay Chhabra, Senior Specialist  <https://orcid.org/0009-0002-4353-8049>

Peeyush Pathak, Classified Specialist  <https://orcid.org/0009-0003-3151-918X>

Seema Chaudhary, Graded Specialist  <https://orcid.org/0000-0001-5846-122X>

Shubham Goyal, Resident  <https://orcid.org/0009-0003-6616-2539>

Cite this article: Kotia R, Chhabra S, Pathak P, Chaudhary S, Goyal S. Endodontic management of six canalled maxillary first molar: A case report. *IP Indian J Conserv Endod* 2023;8(2):111-114.