

Content available at: <https://www.ipinnovative.com/open-access-journals>

IP Indian Journal of Conservative and Endodontics

Journal homepage: <https://www.ijce.in/>

## Case Report

# Unlocking Biodentine's potential: A case report on successful furcation repair with a six-month follow-up

Priya Subramaniam<sup>1</sup>, Madhusudhan KS<sup>1\*</sup>, Sadiya Naz<sup>1</sup>

<sup>1</sup>Dept. of Pediatric & Preventive Dentistry, The Oxford Dental College, Bengaluru, Karnataka, India



### ARTICLE INFO

#### Article history:

Received 12-10-2023

Accepted 21-11-2023

Available online 16-12-2023

#### Keywords:

Biodentine  
Biomaterial  
Endodontics  
Furcation  
Perforation  
Repair

### ABSTRACT

In this case report, we highlight the effectiveness of Biodentine in endodontic treatments, specifically in repairing furcation involvement. A 12-year-old patient had pain in the right lower back tooth, which indicated that a previous endodontic treatment had failed, and there was perforation in tooth 46. We successfully used Biodentine for nonsurgical repair, and a thorough follow-up showed that the radiolucency had resolved, and the patient was asymptomatic.

This is an Open Access (OA) journal, and articles are distributed under the terms of the [Creative Commons Attribution-NonCommercial-ShareAlike 4.0 License](https://creativecommons.org/licenses/by-nc-sa/4.0/), which allows others to remix, tweak, and build upon the work non-commercially, as long as appropriate credit is given and the new creations are licensed under the identical terms.

For reprints contact: [reprint@ipinnovative.com](mailto:reprint@ipinnovative.com)

## 1. Introduction

Endodontic procedures focus on preventing and addressing issues related to the pulp and surrounding tissues to preserve natural teeth and ensure their proper function. The goal is to intercept and treat pulpal or periradicular pathologies, promoting overall oral health and maintaining the integrity of the dentition.<sup>1</sup> The aim of root canal treatment in teeth, is to remove all bacteria; necrotic and vital pulp remnants; and infected dentin and to fill the root canal system hermetically.<sup>2</sup> Perforations in endodontic cases, if not handled appropriately, can result in serious complications. Effectively managing perforations is crucial, with the primary objective being the creation of a seal to prevent contamination of the surrounding periodontal structures.<sup>3</sup>

Historically, restorative materials such as amalgam, SuperEBA, Cavit, glass ionomer (GI), and composite have been used with different degrees of success.<sup>4</sup> MTA, a biocompatible material, excels in endodontic applications.

It's ideal for perforation repair, offering superior results over amalgam, especially when applied promptly. In treating iatrogenic perforations, Mineral trioxide aggregate (MTA) and platelet-rich fibrin (PRF) contribute to successful repair and furcation regeneration, ensuring long-term clinical benefits. Resorption and caries pose major complications in endodontic and restorative procedures.<sup>5,6</sup> The focus in recent calcium silicate-based products has been on "Biodentine," commercially launched in 2009 by Septodont (<http://www.septodontusa.com/>). Specifically designed as a "dentine replacement" material, Biodentine has garnered attention and undergone various investigations. Its applications span endodontic repair (root perforations, apexification, resorptive lesions, and retrograde filling in surgery) and pulp capping. Moreover, it serves as a dentine replacement material in restorative dentistry, showcasing its versatility in dental applications.<sup>7,8</sup> In this case, Biodentine was utilized to address pathologic furcation involvement, with a follow-up period of six months.

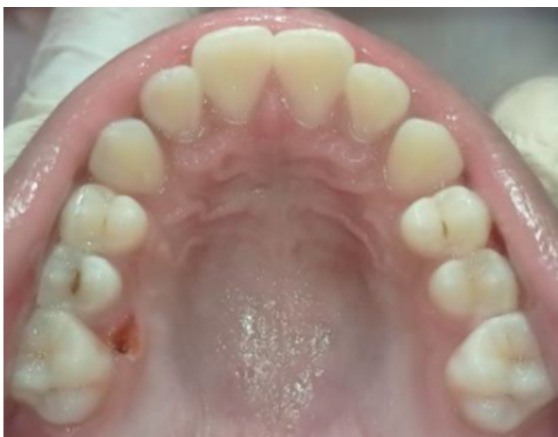\* Corresponding author.

E-mail address: [sudhannks@gmail.com](mailto:sudhannks@gmail.com) (Madhusudhan KS).

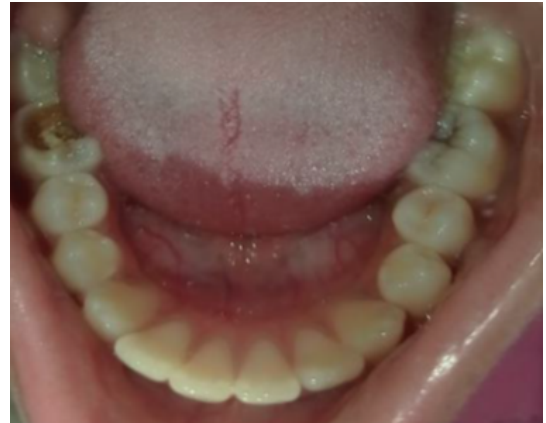## 2. Case Report

A 12 year old female presented to the Department of Pediatric and Preventive Dentistry with a chief complaint of pain persisting in the right lower back tooth region for the past 5 days. The patient reported undergoing endodontic treatment one year ago for tooth 46 at a private clinic. Intraoral examination revealed a fractured restoration on tooth 46, which was sensitive to percussion and painful on palpation (Figures 1 and 2). Intraoral periapical radiograph (IOPAR) displayed a failed endodontic treatment with perforation involving the furcation area of tooth 46. Radiolucency was observed in the furcal region, along with periapical radiolucency in relation to the mesial root (Figure 3). The recommended treatment plan involved the removal of guttapercha from the mesial canals, biomechanical preparation of mesial canals, and nonsurgical repair of the perforation using Biodentine, followed by permanent restoration (Figures 4, 5, 6 and 7). This comprehensive approach aims to address the failed endodontic treatment and restore the tooth to optimal health. The planned treatment was completed and one month follow up intraoral radiographs showed resolution of periapical and furcation radiolucency. After six months there was radiographic evidence of complete resolution reported of radiolucency and patient was asymptomatic (Figure 8).

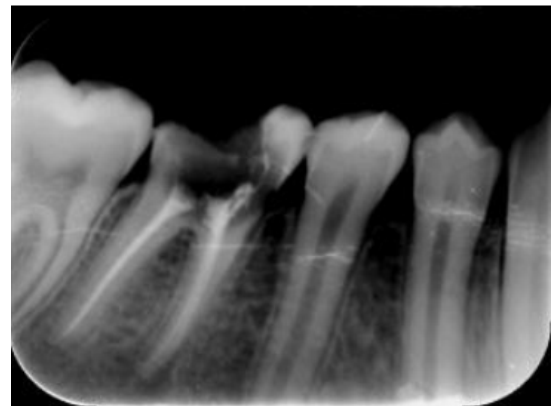
Pre-operative intraoral photographs (Figures 1 and 2)



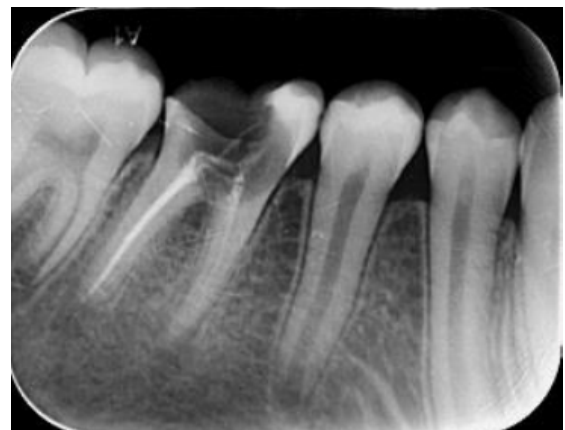**Figure 1:** Maxillary arch



**Figure 2:** Mandibular arch



**Figure 3:** IOPAR wrt 46 (root canal treated teeth with furcal involvement)

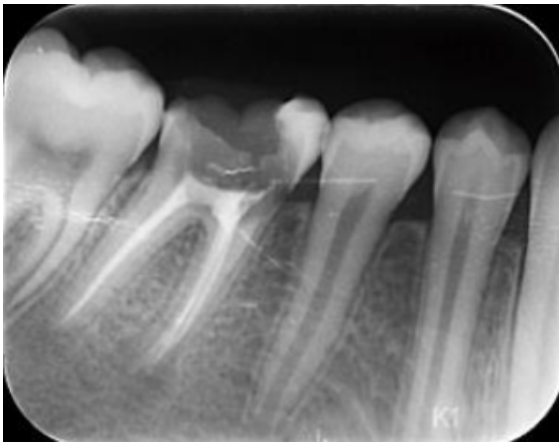


**Figure 4:** IOPA after removal of guttapercha from mesio-buccal and mesio-lingual canals wrt 46

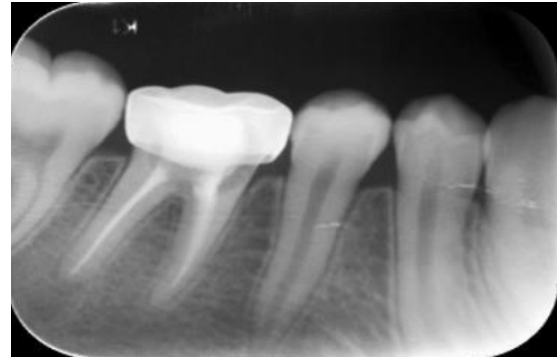
Pre-operative radiograph (Figure 3)  
During treatment (Figures 4, 5, 6, 8 and 7)  
Six months follow up (Figure 8)  
Post-operative intraoral photographs (Figures 9, 10 and 11)

## 3. Discussion

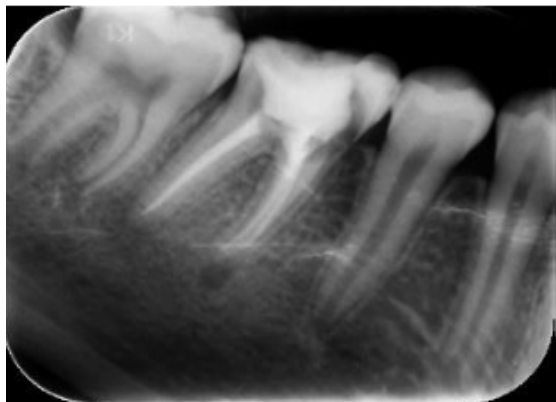
A successful root canal filling should exhibit proper filling without significant overextension or underfilling, ensuring a patent canal. Post-treatment, there should be an absence of



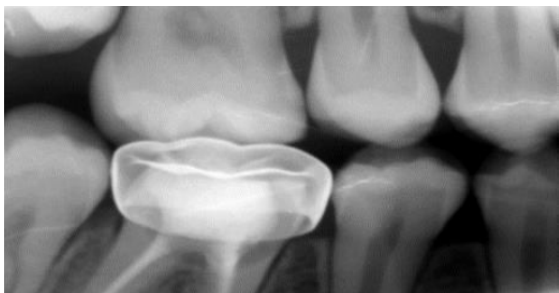**Figure 5:** Biodentin placement at fucation area and obturated mesiobuccal and mesiolingual canals



**Figure 8:** IOPAwrt 46 with absence of furcal and periapical radiolucency

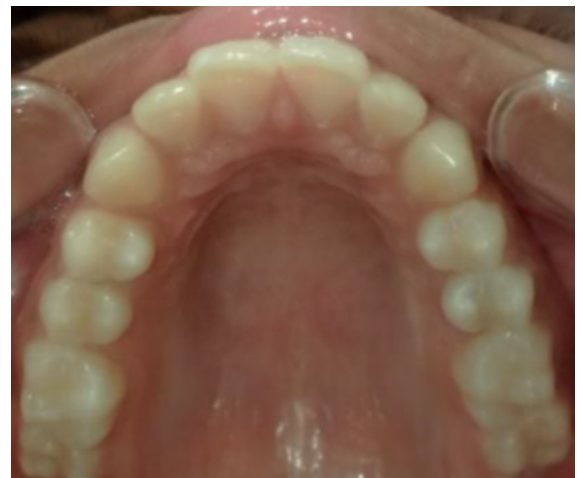

**Figure 6:** Afterobturation and furcal repair wrt 46

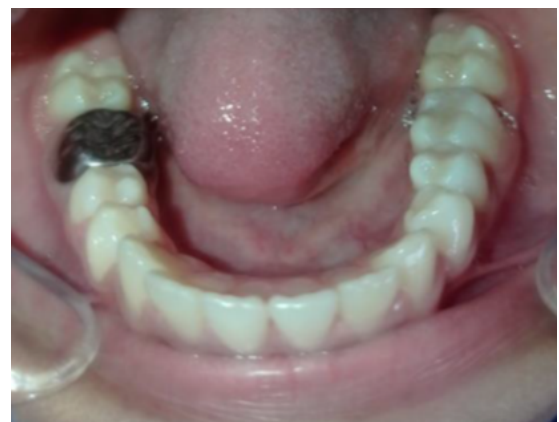

**Figure 7:** Stainless steel crown placedwrt 46

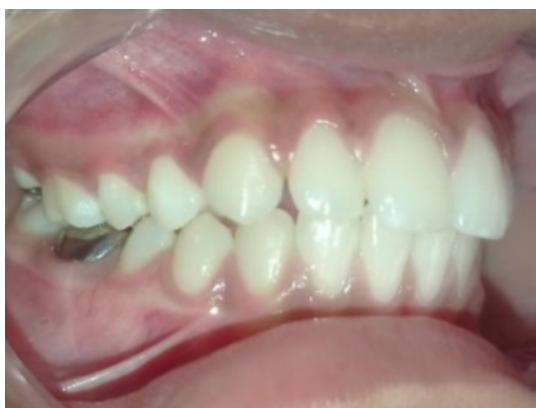adverse signs or symptoms such as prolonged sensitivity, pain, or swelling. Additionally, evidence of resolution of pretreatment pathology and no further breakdown of periradicular supporting tissues should be observed both clinically and radiographically.<sup>1</sup> Following furcation perforations, a series of events unfold: the perforation induces harm to periradicular tissues in the furcation, triggering inflammation, granulomatous tissue formation, bone resorption, destruction of periodontal fibers, epithelial



**Figure 9:** Maxillary arch



**Figure 10:** Mandibular arch



**Figure 11:** Lateral view

proliferation, and ultimately, the emergence of a periodontal pocket.

The Biodentine product consists of two components: powder and liquid. The powder is composed of tricalcium silicate, dicalcium silicate, calcium carbonate, oxide filler, iron oxide shade, and zirconium oxide. Tricalcium silicate and dicalcium silicate are the primary and secondary materials, respectively, while zirconium oxide acts as a radiopacifier. The liquid component includes calcium chloride as an accelerator and a hydrosoluble polymer that functions as a water-reducing agent. Notably, the product's unique characteristic is its fast-setting time, achieved by adjusting particle size, incorporating calcium chloride, and reducing liquid content. This results in a setting time as short as 9–12 minutes, an improvement compared to other calcium silicate materials.<sup>8,9</sup>

During the procedure we observed an initial setting time between 8–12 minutes which was satisfactory to complete the procedure. According to the research conducted by Grech et al Biodentine exhibited the highest compressive strength among the tested materials. This notable strength was due to low water/cement ratio employed in the formulation of Biodentine.<sup>10</sup> The ratio significantly enhances Biodentine's performance and contributes to its superior compressive strength. The study highlights the importance of this ratio in the performance of Biodentine. During the six-month follow-up, we observed that the filling withstood masticatory forces, and there was no fracture or distortion in the furcation area.

A perforation repair material needs to exhibit adequate push-out bond strength with dentinal walls to prevent dislodgement. In a study by Aggarwal et al. the push-out bond strengths of Biodentine, ProRoot MTA, and MTA Plus were investigated in the context of furcal perforation repairs. This research contributes valuable insights into the comparative performance of these materials in maintaining effective bonding and stability in perforation repair situations. Biodentine finds application in endodontics, particularly in the repair of perforations, a common

occurrence in clinical practice.<sup>11</sup>

During the treatment of the present case we found out that Biodentine did not dislodge from the dentinal walls. Radiopacity is a crucial property for repair materials, especially given their application in thin layers. The ease of differentiation from surrounding tissues is essential for effective use in dental procedures.<sup>7</sup> In our six-month follow-up, we observed that Biodentine exhibits sufficient radiopacity, allowing clear differentiation from surrounding structures.

#### 4. Conclusion

Biodentine proves its efficacy in endodontics, excelling in perforation repair and root canal treatments. With fast-setting time, superior compressive strength, and adequate radiopacity, it ensures stability and durability. The six-month follow-up affirms its reliability, establishing Biodentine as a valuable choice in dental procedures.

#### 5. Declaration of Patient Consent

The authors have obtained appropriate consent forms from the patients' parents to report clinical information and images in the journal, with the understanding that anonymity cannot be guaranteed.

#### 6. Conflict of Interest

None.

#### 7. Source of Funding

None.


#### References


1. American Academy of Pediatric Dentistry. Pulp therapy for primary and immature permanent teeth. The Reference Manual of Pediatric Dentistry. vol. 2023. Chicago, Ill: American Academy of Pediatric Dentistry; p. 457–65.
2. Camp JH. Pediatric endodontics, endodontic treatment for the primary and young permanent dentition. *Pathways Pulp*. 2002;p. 833–9.
3. Saunders WP, Saunders EM. Conventional endodontics and the operating microscope. *Dent Clin North Am*. 1997;41(3):415–28.
4. Ibarrola JL, Biggs SG, Beeson TJ. Repair of a large furcation perforation: A four-year follow-up. *J Endod*. 2008;34(5):617–9.
5. Roberts HW, Toth JM, Berzins DW, Charlton DG. Mineral trioxide aggregate material use in endodontic treatment: a review of the literature. *Dent Mater*. 2008;24(2):149–64.
6. Bains R, Bains VK, Loomba K, Verma K, Nasir A. Management of pulpal floor perforation and grade II Furcation involvement using mineral trioxide aggregate and platelet rich fibrin: A clinical report. *Contemp Clin Dent*. 2012;3(Suppl 2):223–7.
7. Malkondu Ö, Kazandağ MK, Kazazoğlu E. A review on biodentine, a contemporary dentine replacement and repair material. *Biomed Res Int*. 2014;p. 160951. doi:10.1155/2014/160951.
8. Septodont SF. Biodentine active biosilicate technology: scientific file. Saint-Maur-Des-Fosses Cedex. France: R and D Department, Septodont; 2010.
9. Arens DE, Torabinejad M. Repair of furcal perforations with mineral trioxide aggregate: two case reports. *Oral Surg Oral Med Oral Pathol*

*Oral Radiol Endod.* 1996;82(1):84–8.

10. Grech L, Mallia B, Camilleri J. Investigation of the physical properties of tricalcium silicate cement-based root-end filling materials. *Dent Mater.* 2013;29(2):20–8.
11. Aggarwal V, Singla M, Miglani S, Kohli S. Comparative evaluation of push-out bond strength of ProRoot MTA, Biodentine, and MTA Plus in furcation perforation repair. *J Conserv Dent.* 2013;16(5):462–5.

### Author biography

**Priya Subramaniam**, Professor and HOD  <https://orcid.org/0000-0002-2935-6524>

**Madhusudhan KS**, Associate Professor  <https://orcid.org/0000-0002-0658-7581>

**Sadiya Naz**, Post Graduate Student  <https://orcid.org/0009-0008-1867-5192>

**Cite this article:** Subramaniam P, Madhusudhan KS, Naz S. Unlocking Biodentine's potential: A case report on successful furcation repair with a six-month follow-up. *IP Indian J Conserv Endod* 2023;8(4):236-240.