

Content available at: <https://www.ipinnovative.com/open-access-journals>

IP Indian Journal of Conservative and Endodontics

Journal homepage: <https://www.ijce.in/>

Case Report

Root to recovery: Successfully healing a large periapical lesion in the mandibular first molar: A case report

Suyash Pratap Singh^{1*}, Nirma Bharati¹, Manoj Kumar Hans¹, Rahul Pandey¹, Anish Kr Maity¹

¹Dept. of Endodontics, Institute Of Dental Sciences, Bareilly, Uttar Pradesh, India



ARTICLE INFO

Article history:

Received 12-12-2023

Accepted 13-01-2024

Available online 20-03-2024

Keywords:

Periapical lesion
mandibular first molar
root canal therapy
healing
bioceramic

ABSTRACT

This case report presents the diagnosis, successful management, and healing of a large periapical lesion associated with the mandibular first molar teeth. The patient's chief complaint was severe, intermittent pain in the lower right posterior region of the mouth, and radiographic examination revealed a substantial periapical radiolucency around the apices of the mandibular first molar. The treatment involved root canal therapy along with adjunctive procedures to promote healing of the periapical lesion. Follow-up radiographs demonstrated a significant reduction of the periapical lesion with complete resolution of symptoms.

This is an Open Access (OA) journal, and articles are distributed under the terms of the [Creative Commons Attribution-NonCommercial-ShareAlike 4.0 License](https://creativecommons.org/licenses/by-nc-sa/4.0/), which allows others to remix, tweak, and build upon the work non-commercially, as long as appropriate credit is given and the new creations are licensed under the identical terms.

For reprints contact: reprint@ipinnovative.com

1. Introduction

Inflammatory changes in the periapical tissues may be acute, chronic, or chronic exacerbated processes. Although such inflammation can occur in different forms, all derive from pulp necrosis. If the pulp dies and proper root canal treatment is not performed in a timely manner, the tissues surrounding the tooth root may become inflamed.¹ The patients may remain asymptomatic for many years or may manifest itself as pain, swelling, or a fistula. When these symptoms develop, the patient will typically seek treatment before large inflammatory changes and extensive bone destruction occur. However, in other situations, alterations in the periapical tissues can only be seen during periodic intraoral radiograph, and these are frequently substantial and have a poor prognosis. Even extensive bone destruction in the form of granulomas or cysts may result in no clinical symptoms for many years.^{1,2} It is estimated that the incidence of periapical granulomas ranges from 9.3–87.1%,

and cysts (within periapical lesions) –6–55%.^{2,3} As the size of the periapical lesions increases, the proportion of root cysts increases. However, it should be remembered that not all extensive inflammatory changes in the periapical tissues are cysts.⁴ The final, decisive differential diagnosis should be preceded by a histopathological diagnosis. However, this is not frequently performed. The indications that the lesion is a cyst rather than a granuloma are as follows in a clinical trial, during treatment: straw amber fluid leaking through the canal and/or during aspiration from the lesion in the radiological examination: lesion larger than 200 mm², with an osteosclerotic rim.^{3,4}

The following case reports describe the management of a particularly large mandibular periapical lesion involving the posterior teeth by nonsurgical endodontic treatment using radiovisiography.

2. Case Presentation

A 21-year-old male presented to the Department of conservative dentistry and Endodontics with a chief

* Corresponding author.

E-mail address: suyash421@gmail.com (S. P. Singh).

complaint of pain and food lodgement in the left lower back tooth region for 2 months. Clinical and intraoral periapical radiograph revealed a deep carious lesion in the mandibular first molar, and a periapical radiolucency was observed around the apices of both roots with furcation bone loss and sinus tract associated with mesial and distal root on the radiograph. The patient reported tenderness to percussion and palpation in the region of the mandibular first molar. Two sinus openings were observed, one from the lingual side and the other from the buccal side, involving both roots separately. Based on clinical and radiographic findings, a diagnosis of pulp necrosis with chronic peri apical abscess was established.

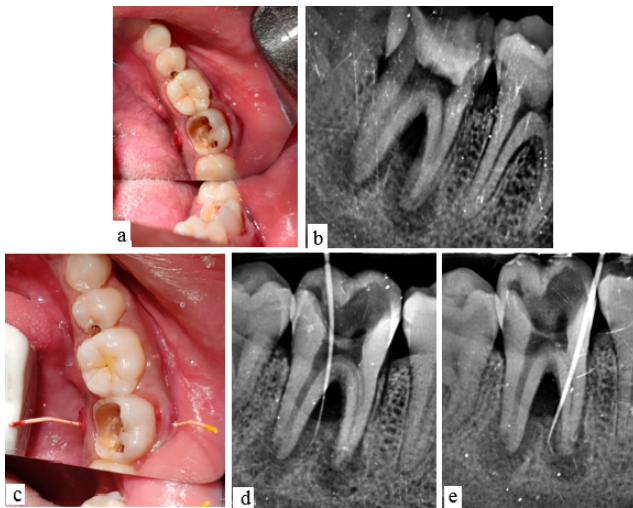


Figure 1: **a:** Showing Preoperative clinical picture of involved tooth; **b:** Preoperative radiograph showing large peri apical lesion involving both roots; **c:** Clinical image of sinus tracing with guttapercha; **d-e:** Radiographs of sinus tracing in both root.

Treatment

The treatment plan involved root canal therapy of the mandibular first molar. Following administration of local anesthesia (1:80000) and rubber dam placement, access cavity preparation was performed, and a K-file ISO No -10 was used to explore the root canals; the working length was determined on the apex locator and confirmed on radiographs. The cleaning and shaping was done using a combination of stainless steel K files till size #20 for glidepath and Pro Taper gold rotary files (Dentsply, Switzerland) in all the canals with intermittent irrigation using 5% sodium hypochlorite (Deepak Dental Products, Delhi, India), normal saline, and 17% EDTA (Dental Avenue Pvt Limited, Mumbai, India) solution with sonic activation by Endoactivator (Dentsply Tulsa Dental specialites, OK, USA). Calcium hydroxide used as intracanal medicament was placed, and the access cavity was temporized.

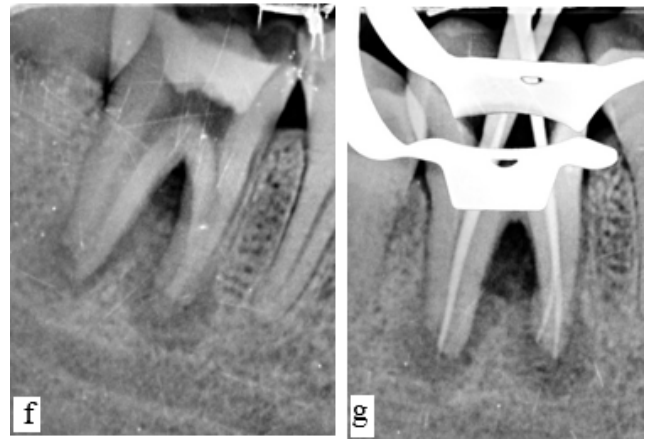


Figure 2: **f:** Intraoral radiograph of placement Calcium hydroxide intracanal medicament; **g:** Intraoral radiograph of showing mastercone selection

At the subsequent visit, the calcium hydroxide medicament was removed, and the canals were obturated using gutta-percha and a bio-ceramic sealer. In addition to root canal therapy, the patient was prescribed non-steroidal anti-inflammatory drugs to manage the periapical inflammation.

2.1. Follow-Up

The patient was followed up at regular intervals, and a radiographic examination at 6 months revealed a significant reduction in the size of the periapical lesion. The patient reported complete resolution of pain and tenderness in the treated tooth. One year post-treatment, a radiograph demonstrated complete healing of the periapical lesion, with evidence of bone regeneration in the furcal region.

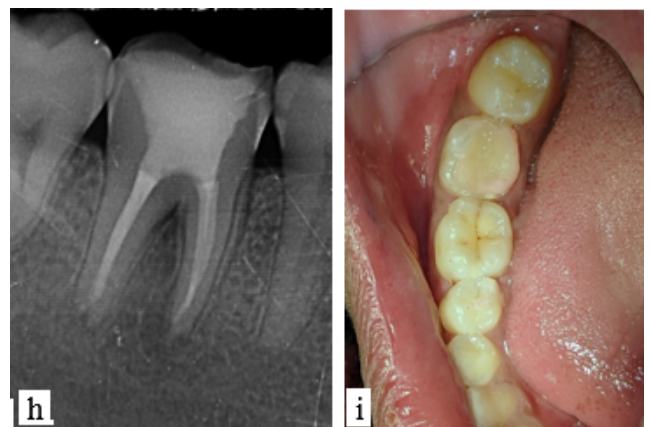


Figure 3: **h:** Radiograph showing postendodontic restoration & complete healing of healing of the periapical lesion, with evidence of bone regeneration in the furcal region; **i:** Intraoral clinical image showing complete elimination of sinuses

3. Discussion

Inflammatory periapical lesions induced by endodontic conditions are commonly 5 - 8 mm in size.^{5,6} Historically, periapical lesions up to 10 mm in size have been defined as periapical granulomas, whereas greater lesions have been designated as periapical cysts.^{7,8} Epithelial cell remains of Malassez in the periodontal membrane are responsible for creating the epithelial lining of cysts. Radicular cysts may form by a number of processes, including the proliferation of epithelial cells as well as osmotic enhancement⁹. According to the above-mentioned criteria, the present instance had a substantial periapical lesion that was most likely a periapical cyst. The presence of straw-coloured exudate, the magnitude of the lesion in conjunction with one non-vital tooth, the radiopaque border, and the divergence of adjacent dental roots^{10,11} all clearly suggested a radicular cyst. However, only histopathologic examinations can provide a definite diagnosis. Various therapeutic options provided for big periapical lesions may range from root canal treatments to other surgical techniques.^{12,13} Sufficient chemomechanical cleaning of the root canal system and proper microbiological elimination are the most crucial criteria for getting a favorable outcome. Previous research has shown that nonsurgical RCT should be done at first;¹⁴ documents have shown that 42% to 74% of such lesions are healed with RCT.^{15–17} However, there is debate concerning the differences between the outcomes of traditional RCT of large and smaller lesions.^{15,18}

An antibacterial calcium hydroxide-based compound dressing was applied in this instance. The entire mechanism of action of this drug is currently unclear. It is shown that calcium hydroxide paste may improve periapical healing and eradicate residual infections by controlling inflammation, encouragement of calcification, eliminating alkaline products of osteoclasts, & endotoxin suppression.^{19–22} In addition, it has been demonstrated that calcium hydroxide dressing greatly enhances periapical healing, specifically in young people.^{23,24} By previous research, periapical bone healing commenced 3 months after endodontic treatment in this case and persisted for the next 6 months. Radiographic evaluations indicated bone regeneration according to increasing density, trabecular repair, and lamina dura formation.

In this situation, bioceramics were utilized as a sealer, which exhibits excellent biocompatibility features due to their similarities to the biological process of hydroxyapatite production and the capacity to promote a regeneration response. They show osteoinductive capacity as they absorb osteoinductive compounds when in contact with the bone healing process.²⁵

The advantages of less intrusive nonsurgical treatment for massive periapical lesions include less psychological impact and are more suitable for patients. It appears that the periapical lesion was totally healed owing to a sufficient

blood supply, abundant undifferentiated cells, and drainage via the lymphatic system. Thus, the lesion was cured to remove the causative causes by endodontic treatment and the regenerating capability of peri apical tissues.

The effective healing of a significant periapical lesion linked with the mandibular first molar teeth was obtained with diligent root canal therapy and adjuvant procedures. The use of an intraoral periapical radiograph allowed for a better assessment of the periapical lesion and the quality of the root canal treatment. This example shows the necessity of comprehensive cleanliness of the root canal system, proper obturation, and suitable treatment to aid the healing of periapical lesions.

4. Conclusion

This case report highlights the successful management and healing of a large periapical lesion in the mandibular first molar through root canal therapy and adjunctive procedures. Clinicians should consider thorough disinfection of the root canal system and appropriate follow-up to assess the healing of periapical lesions.

5. Source of Funding

None.

6. Conflict of Interest

None.

Acknowledgments


The authors would like to thank the patient for providing consent for the publication of this case report.


References

1. Nair PR, Pajarola G, Schroeder HE. Types and incidence of human periapical lesions obtained with extracted teeth. *Oral Surg Oral Med Oral Pathol Oral Radiol Endod.* 1996;81(1):93–102.
2. Schulz M, Arx TV, Altermatt HJ, Bosshardt D. Histology of periapical lesions obtained during apical surgery. *J Endod.* 2009;35(5):634–42.
3. Natkin E, Oswald RJ, Carnes LI. The relationship of lesion size to diagnosis, incidence, and treatment of periapical cysts and granulomas. *Oral Surg Oral Med Oral Pathol.* 1984;57(1):82–94.
4. Sood N, Maheshwari N, Gothi R, Sood N. Treatment of large periapical cyst-like lesion: a noninvasive approach: a report of two cases. *Int J Clin Pediatr Dent.* 2015;8(2):133–7.
5. Murphy WK, Kaugars GE, Collett WK, Dodds RN. Healing of periapical radiolucencies after nonsurgical endodontic therapy. *Oral Surg Oral Med Oral Pathol.* 1991;71(5):620–4.
6. Sjögren U, Figdor D, Persson S, Sundqvist G. Influence of infection at the time of root filling on the outcome of endodontic treatment of teeth with apical periodontitis. *Int Endod J.* 1997;30(5):297–306.
7. Morse DR, Patnik JW, Schacterle GR. Electrophoretic differentiation of radicular cysts and granulomas. *Oral Surg Oral Med Oral Pathol.* 1973;35(5):249–64.
8. Lalonde ER. A new rationale for the management of periapical granulomas and cysts: an evaluation of histopathological and radiographic findings. *J Am Dent Assoc.* 1970;80(5):1056–9.

9. Nair P, Sjögren U, Sundqvist G. Cholesterol crystals as an etiological factor in non-resolving chronic inflammation, an experimental study in guinea pigs. *Eur J Oral Sci.* 1998;106(2p1):644–50.
10. White SC, Pharoah MJ. The evolution and application of dental maxillofacial imaging modalities. *Dent Clin North Am.* 2008;52(4):689–705.
11. Wood NK, Goaz PW, Jacobs MC. Periapical radiolucencies. 5th Edn. Wood N, Goaz P, editors. St Louis: CV Mosby; 1996. p. 257.
12. Moshari A, Vatanpour M, Esnaashari E, Zakershahak M, Arab AJ. Nonsurgical Management of an Extensive Endodontic Periapical Lesion: A Case Report. *Iran Endod J.* 2017;12(1):116–9.
13. Mejia JL, Donado JE, Basrani B. Active nonsurgical decompression of large periapical lesions—3 case reports. *J Can Dent Assoc.* 2004;70(10):691–4.
14. Broom NJ, Bortoluzzi EA, Bramante CM. Repair of large periapical radiolucent lesions of endodontic origin without surgical treatment. *Aust Endod J.* 2007;33(1):36–41.
15. Çalışkan M. Prognosis of large cyst-like periapical lesions following nonsurgical root canal treatment: a clinical review. *Int Endod J.* 2004;37(6):408–16.
16. Asgary S, Ehsani S. Endodontic treatment of a large periradicular lesion: A case report. *Iran Endod J.* 2008;3(4):134–6.
17. Sood N, Maheshwari N, Gothi R, Sood N. Treatment of Large Periapical Cyst Like Lesion: A Noninvasive Approach: A Report of Two Cases. *Int J Clin Pediatr Dent.* 2015;8(2):133–7.
18. Sc W, Pharaoh M. Oral Radiology, Principle, principle and interpretation. Mosby: Inc; 2000. p. 385.
19. Farhad A, Mohammadi Z. Calcium hydroxide: a review. *Int Dent J.* 2005;55(5):293–301.
20. Tronstad L, Andreasen J, Hasselgren G, Kristerson L, Riis I. pH changes in dental tissues after root canal filling with calcium hydroxide. *J Endod.* 1981;7(1):17–21.
21. Safavi KE, Nichols FC. Effect of calcium hydroxide on bacterial lipopolysaccharide. *J Endod.* 1993;19(2):76–8.
22. Seux D, Couble M, Hartmann D, Gauthier J, Magloire H. Odontoblast-like cytodifferentiation of human dental pulp cells in vitro in the presence of a calcium hydroxide-containing cement. *Arch Oral Biol.* 1991;36(2):117–28.
23. Çalışkan MK, Türkün M. Periapical repair and apical closure of a pulpless tooth using calcium hydroxide. *Oral Surg Oral Med Oral Pathol Oral Radiol Endod.* 1997;84(6):683–7.
24. Saatchi M. Healing of large periapical lesion: A nonsurgical endodontic treatment approach. *Aust Endod J.* 2007;33(3):136–40.
25. Cheng L, Ye F, Yang R, Lu X, Shi Y, Li L. Osteoinduction of hydroxyapatite/beta-tricalcium phosphate bioceramics in mice with a fractured fibula. *Acta Biomaterialia.* 2010;6(4):1569–74.


Author biography

Suyash Pratap Singh, Post Graduate Student  <https://orcid.org/0000-0003-3381-728X>

Nirma Bharati, Post Graduate Student  <https://orcid.org/0009-0000-3732-2204>

Manoj Kumar Hans, HOD

Rahul Pandey, Associate Professor

Anish Kr Maity, Post Graduate Student  <https://orcid.org/0009-0006-9365-045X>

Cite this article: Singh SP, Bharati N, Hans MK, Pandey R, Maity AK. Root to recovery: Successfully healing a large periapical lesion in the mandibular first molar: A case report. *IP Indian J Conserv Endod* 2024;9(1):49-52.