

Content available at: <https://www.ipinnovative.com/open-access-journals>

IP Indian Journal of Conservative and Endodontics

Journal homepage: <https://www.ijce.in/>

## Case Report

# Laser doppler flowmetry microcirculation assessment of a periapical cyst

Bogdan Petrov Krastev<sup>1\*</sup>, Ivan Atanasov Filipov<sup>1</sup>

<sup>1</sup>Faculty of dental medicine, Medical University Plovdiv, Dept. of Operative Dentistry and Endodontics, Bulgaria



### ARTICLE INFO

#### Article history:

Received 11-02-2024

Accepted 06-03-2024

Available online 03-06-2024

#### Keywords:

Apical periodontitis

Cyst

Laser Doppler flowmetry

Microcirculation

### ABSTRACT

**Introduction:** The radicular cyst develops by necrosis in the center of a granulation lesion and expands by applying pressure to the surrounding tissues thus decreasing microcirculation in bone. Laser doppler flowmetry is a non-invasive method of measuring microcirculatory blood flow in tissue. Using laser doppler flowmetry Moor VMS-LDF1-HP and CPIT-HP probe combined with Moor VMS-PC software the microcirculation of the periapical lesion (cyst) was evaluated before surgical endodontic treatment. It was compared to a healthy endodontically treated tooth of the same type with no periapical lesions. Measurements were done with the help of a VMSLDF1-HP probe. Later the bony crypt of the cyst was evaluated for blood perfusions with the VP7BS-HP bone probe

**Objective:** Evaluate tissue microcirculation of a periapical lesion before, after and during surgical endodontic treatment

**Results:** Laser Doppler flowmetry shows that the cystic tooth has a decreased blood flow, decreased concentration, direct current, speed, and lower temperature compared to another endodontically treated lesion-free tooth of the same type. During periapical surgery, the direct laser blood flow evaluation of the surgical crypt shows different values of flux, speed, direct current, and concentration before and after cyst removal which could be attributed to the mechanical trauma (osmotic pressure), adrenaline in the local anaesthetic or laser irradiation of tissues.

**Conclusion:** Laser Doppler flowmetry is a valuable method to perform tissue evaluation before, during and after treatment. It allows us to follow up on the healing and pathological dynamics of microcirculatory tissue changes as well as evaluate and compare different methods and materials for the treatment of apical periodontitis.

This is an Open Access (OA) journal, and articles are distributed under the terms of the [Creative Commons Attribution-NonCommercial-ShareAlike 4.0 License](https://creativecommons.org/licenses/by-nc-sa/4.0/), which allows others to remix, tweak, and build upon the work non-commercially, as long as appropriate credit is given and the new creations are licensed under the identical terms.

For reprints contact: [reprint@ipinnovative.com](mailto:reprint@ipinnovative.com)

## 1. Introduction

Apical periodontitis can be caused by a variety of reasons, but infection after caries complications is the most common cause. Most periapical cysts are the result of apical periodontitis (granuloma) and there are different theories for their development but the central necrosis theory is one of the best recognized.<sup>1</sup> A radicular cyst is usually formed by inflammatory proliferation of the epithelial cell rests of Malassez. Cysts depending on their relation to the root

canal can be categorized as either pocket cysts or true cysts. Radicular cysts cannot be diagnosed clinically using conventional radiographic or even cone beam computed tomographic (CBCT) images. However, the bigger a lesion is more likely it could be a cyst. Definitive diagnosis can be achieved only by histological examination of biopsy specimens after lesion removal.<sup>2</sup> Cyst have a sclerotic border and their growth in size is exerting pressure over the surrounding bone thus resorbing it, which might decrease surrounding tissue microcirculation. Microcirculation can be assessed by various methods. Laser doppler flowmetry is

\* Corresponding author.

E-mail address: [drbkrastev@gmail.com](mailto:drbkrastev@gmail.com) (B. P. Krastev).

one of them. LDF monitors or imaging devices can represent graphically or visually bone perfusion.<sup>3</sup> Because radicular cysts are caused by root canal infection, it is believed that they can be treated by conventional root canal therapy. This is only applicable if they are connected with the root canal system. Not all authors agree that cyst can be treated nonsurgically, and some recommend radical treatment e.g., endodontic surgery, because of the affected bone perfusion around them. The healing of large cyst usually takes more time and not all resorbed tissue will be replaced by bone but rather by scar connective tissue 66% which is more friable and prone to future infections.<sup>4</sup>

**Aim:** Evaluate tissue perfusion of a periapical lesion before nonsurgical treatment and during surgical endodontic treatment with piezotome with the help of laser doppler flowmeter.

## 2. Case Report

### 2.1. Nonsurgical treatment

A 36-year-old male, an office worker was referred for endodontic treatment. He was diagnosed with a periapical lesion on tooth 12,13 via periapical X-rays. He had a buccal fistula between the apices of teeth 12 and 13. Both teeth had previously unsatisfactory orthograde root canal treatment. Patients still had symptoms which were pain and swelling after root canal obturation. Medical history was unremarkable. Valid informed consent for treatment was obtained. Initially non-surgical root canal treatment was performed on tooth 12, 13 with a rubber dam. The working length was 28 mm for tooth 13 and 22mm for tooth 12. The final master apical file for both teeth was Pro Taper Universal F3 ISO 30, taper 0.9. Irrigation protocol was NaOCl 5.25% (PPH Cerkamed Wojciech Pawłowski, Stalowa Wola, Poland) throughout the procedure. Final irrigation was EDTA 17% (PPH Cerkamed Wojciech Pawłowski, Stalowa Wola, Poland)) for 1 minute, 3 minutes 5,25% NaOCl with ultrasonic activation. The final irrigation solution was NaCl 0.9% 1cc. The root canals were dried with paper points and obturated with Well Root ST™ (calcium silicate, Vericom Co Ltd, Republic of Korea) bioceramic sealer and gutta-percha with continuous wave condensation technique performed with Elements Free™ obturation system (Kerr Corporation, CA, USA), 200 degrees C° setting and Buchanan Hand pluggers.

### 2.2. Endodontic surgery and nonsurgical ROI

After the nonsurgical root canal treatment, a cone beam computed (CBCT) three-dimensional image (Figure 1) was done to evaluate the 3D root canal obturation and lesion dimensions. The lesion was 7mm×8mm (height×width) and 7 mm buccolingually. The lesion had resorbed the buccal and palatal cortical bones and displaced the roots of teeth 12, 13. Decision was made to perform endodontic surgery based

on the size of the lesion, proximity to the maxillary sinus and continuous pus draining from a buccal fistula tract even after the orthograde endodontic treatment. A decision was made to assess the microcirculation of the periapical lesion. Valid informed consent was obtained from the patient for investigation. The first two nonsurgical microcirculation measurements were done prior to the surgery and before application of anesthesia, with laser doppler flowmeter (LDF) monitor Moor VMS LDF1-HP (Moor Instruments Ltd, Axminster UK). The laser doppler flowmeter monitor has a maximum power of 20 mW max which is equal to 20 mJ. The high power gives a better signal-to-noise ratio in human subjects which is unsatisfactory with lower energy systems. Wavelength is 785 nm ± 10 nm; Angular spread of laser light from probe tip is 26°. It measures Flux (perfusion): Range: 0-1000 PU. CONC (concentration of erythrocytes): Range: 0-1000 Arbitrary Units (AU). Direct current velocity DC: Range: 0-1000AU and Speed. Temperature measurement: Range 5-50°C. It can be used with different tissue or bone probes. Tooth 22 was nonvital with a previous satisfactory root canal treatment, and no periapical lesion healed with fibrous scar tissue and it served as a control. The skin probe CP1T-HP (Moor Instruments Ltd, Axminster, UK) was placed for 1 minute over the mucosa in the apical tip area of teeth 12 -Region of interest (ROI-1), 22(ROI-2) (buccal fold) over the free mucosa, touching it, over the apices of the teeth. The probe area is 5 cm<sup>2</sup> which delivers maximum power density of 0.03 W/cm<sup>2</sup>. It was used at a 0.5 s pulse and 15 Hz which delivers 0.00 W or peak power of 0.01 W/cm<sup>2</sup>. The graphical and numerical representation of the readings is shown in Table 1. The lip was not retracted to avoid twitching. Special goggles provided by the manufacturer filter the wavelength of the laser due to a possible injury of the retina (cataract) and cornea (burn, blurring). The laser effect on the skin is a thermal burn if used for long time. The CP1T-HP skin probe used for the nonsurgical microcirculation measurement has a fiber separation of 2 mm. It is a high-power laser doppler, tissue oxygenation and temperature measurement probe that delivers light at a right angle to the probe cable. The probe has a height of 12.5 mm and outside diameter of 8 mm at the probe tip. The test setting was set to 15 Hz which is equal to 0.3 W/cm<sup>2</sup>. Max. Energy density for the CP1T-HP probe is 0.00265 J/cm<sup>2</sup>. The laser fluence/radiant exposure is 26.5 Jm<sup>2</sup>, spectral exposure is 26.5 Jm<sup>2</sup>×15Hz = 397.5 Jm<sup>2</sup>-2-Hz-1 or spectral exposure in wavelength is 26.5 Jm<sup>2</sup>×785 nm=20.803 Jm<sup>3</sup>.

Five minutes after the anaesthesia was placed another nonsurgical measurement was taken from tooth 12 in the same mucosal target area (ROI 3) over the root apex.

### 2.3. Endodontic surgery and surgical ROI

The endodontic surgical treatment protocol was performed in the following order. Local block anesthesia of n.

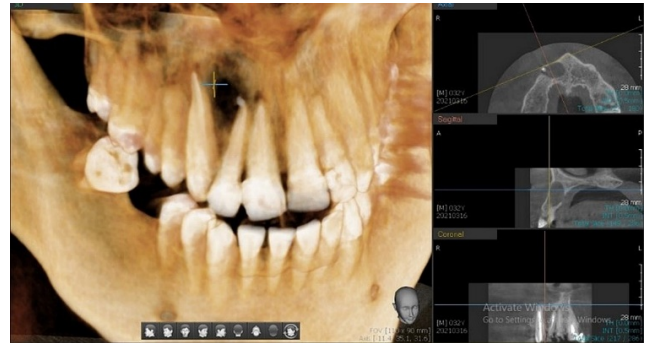incisus and n. infraorbitalis accompanied by infiltration anesthesia in the area above the periapical lesion with Ubestesin forte® (Articaine 4%/1:100000, 3M ESPE, USA), 1.7ml vasoconstrictor adrenaline. Two cartridges were used initially. Incision was horizontal type (scalpel size 15), starting from mesial of tooth 12 to distal to the root of tooth 13 on the level of the mucogingival junction. Flap reflection was performed with a periosteal elevator. Bone widening was performed with a piezosurgical tip from the bone surgery kit of Implant Centre 2™ (Acteon, France) to find the root tips of teeth 12, 13. Before cyst removal and curettage of the lesion a fourth measurement was performed with the VP7BS-HP (Moor Instruments Ltd, Aminster, UK) bone probe (ROI 4). The probe was placed over the lesion wall for one minute. VP7BS-HP probe has a size of 3.3 mm. Max Power Density 0.23 W/cm<sup>2</sup>, Max Energy Density 0.02 J/cm<sup>2</sup>. Max Power Density is 0.00 W/cm<sup>2</sup> or a peak power density of 0.03 W/cm<sup>2</sup> at 0.5 s and 15 Hz. We had to give two additional cartridges of anesthetic injected directly in the cyst itself before being able to remove it completely as it was very sensitive during detachment and curettage from the bone cavity walls. Hand curettage was performed after that with a surgical curette. After the hand curettage the fifth one-minute measurement was performed with the VP7BS-HP bone probe inside the lesion cavity The probe was placed directly inside the bone cavity touching bone (ROI 5). Piezo apicectomy was performed at three mm from the root tip for tooth 12 and 13. Ultrasonic retrograde preparation was done with tip E30RD-S (NSK, Japan). The retrograde cavity was obturated with Theracal LC® (calcium silicate, Bisco Dental, USA) and photopolymerized with Bluedent Express (BGLight, Plovdiv, Bulgaria) light curing lamp in hyper mode, 410-490 nm wavelength range, 3500 mW/cm<sup>2</sup> for three seconds. After surgery, a graft was placed inside the bony cavity Novabone® (calcium phosphosilicate Novabone Products, LLC. A Halma Company Alachua) to act as an osteoconductive and scaffold material. Flap adaptation and suturing were done with nonresorbable monofilament sutures EvoMat Polypropylene, 5/0, 20 cm<sup>1</sup>/<sub>2</sub> (Dr Mayer®, China). The graphical and numerical representation of the all-microcirculation measurements are visible in Table 1.

### 3. Results

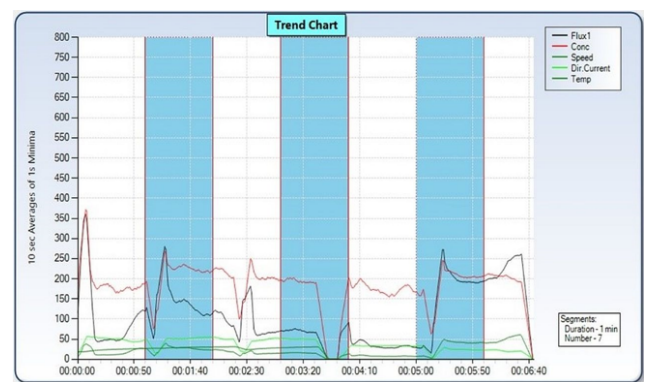
Table 1 shows ROI (regions of interest). The nonsurgical ones are the measurements taken from tooth 12, 22 before surgery (ROI 1,2,3), Surgical ROI 4 and 5 are before and after the lesion removal. ROI 1- Measurement of periapical perfusion of tooth 12 before LA application. ROI 2-Measurement of periapical tissue perfusion of tooth 22, ROI 3 -Measurement five minutes after the LA application. ROI 4. Measurement of the lesion perfusion before its removal. ROI 5 Measurement of the bone perfusion after lesions removal. Flux(AU) Perfusion Units,

Conc Concentration(Arbitrary Units), DC(direct current) Arbitrary Units, Speed( mm/s), Temperature – degrees Celsius.

The lesion was confirmed histologically to be a radicular cyst. It healed uneventfully and is under a follow-up period.



**Figure 1:** Cystic appearance in CBCT. Sagittal, axial, and coronal view



**Figure 2:** Graphical representation of all regions of interest (ROI) measured with laser doppler flowmetry

### 4. Discussion

A laser doppler flowmeter is a minimally invasive way of reading the frequency of the oscillation produced by the Doppler frequency shift of the red blood cells in peripheral tissue and it translates the frequency to an intensity oscillation. The perfusion/flux output is equal to the concentration (number) of the red blood cells times their velocity in each time which determines circulation. The setting of 15 Hz detects erythrocytes which move at a maximum speed of 6 mm/s.<sup>5</sup> It is a one-point measurement method which records the integrated perfusion in a sampling volume in real-time. The measurement depth and sampling volume depend on the wavelength and the fiber separation used.<sup>6,7</sup> Infrared light, a wavelength of 785 nm has been found to penetrate deeper into the tissues

**Table 1: ROI** (Regions of interest). **ROI 1** (Nonsurgical measurement of microcirculation before LA tooth 12), **ROI 2** (Nonsurgical measurement of microcirculation, no LA tooth 22, control), **ROI 3** (Nonsurgical measurement of microcirculation, Tooth 12, 5 minutes after LA application), **ROI 4** (Measurement of the cyst microcirculation before its removal), **ROI 5** (Measurement of the microcirculation of the bony cavity after cyst removal).

ROI No	Param	Mean	S. Dev	S. Err	Median	Min	Max	T of Min	T of Max	Sum	Area	Offset
1	Flux	89,7	73,1	1,49	71,1	0,0	874,2	00:01:10	00:01:05	215289,5	5382,2	49,5
	Conc	226,4	95,5	1,95	231,8	0,0	981,9	00:01:10	00:01:06	543354,9	13583,9	257,8
	Speed	18,9	9,9	0,20	15,8	0,0	50,4	00:01:10	00:01:05	45402,9	1135,1	12,9
	Dir.Current	46,7	14,3	0,29	51,0	0,4	66,3	00:01:10	00:00:11	112046,6	2801,2	61,5
	Temp	25,2	1,7	0,03	25,5	21,0	27,4	00:00:11	00:01:07	60494,5	1512,4	22,4
2	Flux1	173,9	60,7	1,24	165,7	79,6	670,0	00:02:13	00:01:18	417468,2	10436,7	234,8
	Conc	260,0	34,0	0,69	256,0	191,2	666,3	00:02:14	00:01:18	624043,0	15601,1	271,5
	Speed	33,5	9,2	0,19	32,5	16,2	92,8	00:02:16	00:01:20	80417,8	2010,4	43,4
	Dir.Current	52,5	2,2	0,04	52,4	49,0	56,4	00:02:09	00:01:59	125968,8	3149,2	52,0
	Temp	29,9	0,9	0,02	30,1	27,7	31,1	00:01:16	00:02:16	71791,8	1794,8	28,4
3	Flux	89,9	20,8	0,42	86,5	53,6	255,6	00:02:37	00:02:32	215842,3	5396,1	94,4
	Conc	251,9	32,7	0,67	250,4	161,2	386,5	00:03:26	00:02:32	604618,3	15115,5	261,2
	Speed	18,3	2,9	0,06	18,0	12,3	36,0	00:02:42	00:02:32	43996,7	1099,9	18,0
	Dir.Current	49,9	2,4	0,05	50,0	42,6	54,2	00:02:31	00:02:52	119641,2	2991,0	48,1
	Temp	28,4	1,8	0,04	28,8	23,7	30,8	00:02:31	00:03:31	68272,1	1706,8	25,4
4	Flux	50,4	16,9	0,34	47,2	25,3	170,6	00:04:32	00:03:57	120867,5	3021,7	61,2
	Conc	233,1	38,0	0,78	231,9	126,5	389,3	00:04:32	00:04:51	559472,6	13986,8	239,0
	Speed	11,3	2,7	0,06	10,9	6,6	29,4	00:04:56	00:03:57	27182,5	679,6	13,3
	Dir.Current	33,8	0,8	0,02	33,9	30,1	35,3	00:03:57	00:04:03	81094,0	2027,3	34,2
	Temp	0,0	0,0	0,00	0,0	0,0	0,0	00:03:57	00:03:57	0,0	0,0	0,0
5	Flux	228,7	27,9	0,57	221,8	177,2	402,8	00:05:40	00:05:20	549034,8	13725,9	238,3
	Conc	241,0	19,7	0,40	240,2	191,8	349,1	00:05:44	00:06:15	578730,9	14468,3	242,9
	Speed	48,3	5,0	0,10	47,4	36,2	69,7	00:05:48	00:05:20	115989,4	2899,7	49,6
	Dir.Current	24,8	3,4	0,07	24,1	18,2	37,3	00:06:16	00:05:22	59480,3	1487,0	28,8
	Temp	0,0	0,0	0,00	0,0	0,0	0,0	00:05:20	00:05:20	0,0	0,0	0,0

than smaller wavelengths like green or red spectrums. The apparatus can allegedly penetrate 1-13 mm of non-pigmented tissue,<sup>8,9</sup> The vertical axis in (Table 1) represents the values of Flux (perfusion units), CONC (arbitrary units), Speed (of erythrocytes), DC (direct current), Temp (°C) and the horizontal axis represents the exact time of the measurement. The LDF monitor is calibrated against a standard reference of polystyrene micro-spheres, as provided by the manufacturer. The perfusion chart should look like an electrocardiogram and be consistent with heart pulsations and pulse.

The readings on tooth, 22(ROI 2;Flux 173.9 PU) before surgical treatment over the gum show very high values of Flux which may be attributed to either artifacts due to hand movement, patient movement, improper placement too much pressure or blood stasis due to the chronic fibrous periodontitis. Hand-held probes may not affect results so much compared to stents<sup>10</sup> but others find opposing results and higher reproducibility with stents. Hand movement or detachment of the probe at any given moment during the measurement may give peaks in values. The higher values for tooth 22 could also be due to the higher power of the laser doppler flowmeter compared to other

machines with lower power. The peaks in Figure 2 are artefacts of Flux (perfusion) and CONC (concentration of erythrocytes) which are represented by the black and light red lines and correspond to the min and max values in Table 1. Tooth 12 shows lower (ROI 1; Flux 89.7 PU) values which could be attributed to the detrimental effect of the cyst exerting pressure on the surrounding tissues thus decreasing blood supply. Even after LA administration which shrinks blood vessels due to the adrenaline in it those values do not change drastically (ROI 3; Flux 89.9 PU). More than 1 minute measurement raises the tissue temperature but does not significantly affect the other variables measured (Table 1- ROI 1, 2, 3). Yet tooth 12 even after the first measurement (ROI 1; Temp 25.2 C<sup>0</sup>) and local anesthetic injection, trauma from it continues to have a lower temperature (ROI 3; Temp 28.4 C<sup>0</sup>) than tooth 22(ROI 2; Temp 29.9 C<sup>0</sup>) which could be due to the adrenaline in the LA it or the effect of the cyst. Perfusion values, signals may come from neighboring areas as well like the lip. Higher perfusion values may be a results of muscle twitching after retraction or come from the free and attached gingiva due to inflammation (gingivitis, chronic marginal periodontitis).<sup>9</sup> It has been proven that gingivitis, chronic

marginal periodontitis increases perfusion values due to blood stasis in the tissues.<sup>3</sup> The surgical test measurement from the cystic cavity wall shows very low values of flux (ROI -4, Flux 50.4 PU) which may be due to the detrimental effect of the lesion over bone microcirculation or the four cartridges of local anesthesia with adrenaline.<sup>6,7</sup> Those low values may provide evidence for the central necrosis theory of cyst development. However straight after the cyst removal perfusion increased significantly (ROI 5; Flux 228.7 PU), speed of erythrocytes increased significantly but direct current slightly decreased. Cysts are lined with epithelium and grow over time due to increased osmotic pressure over bone walls which decreases perfusion<sup>11</sup> but after their removal there is a rebound in circulation. Granulomas, on the other hand, should show increased perfusion due to the increased stasis and abundance of differentiated blood vessels.<sup>3</sup> The low values for perfusion before cyst removal may show that the bone, gum is affected by the periapical lesions. Those tissues may have a constant level of perfusion influenced by the lesion which is not affected much after the administration of local anesthetic. Tissue perfusion values before, after and during treatment will show the effect of large or small lesions. They could serve as a good predictive factor for future prognosis and development. LDF could evaluate the effect of different treatment methods. It could be used to differentiate lesion type based on the microcirculation of the surrounding tissues (bone and gum) similar to ultrasound doppler flowmetry.<sup>12</sup> However, there are a lot of factors which can affect results.<sup>9</sup> As far as we know this is the first time a high-power laser Doppler flowmeter has been used to evaluate the perfusion of a periapical lesion before, after anesthetic administration and before and after cyst removal.

## 5. Conclusion

So far, Laser Doppler Flowmetry has been used for soft tissue evaluation in periodontology, orthopedic surgery, endodontics, oral surgery. This method can be used to evaluate tissue perfusion after different treatment protocols. It can be used to measure bone microcirculation, thus predicting future healing and prognosis after lesion removal. It can be used for diagnosis of periapical lesions and their activity, but more data is needed to make sound conclusions about bone microcirculation and how it is affected by different types of lesions.

## 6. Source of Funding

None.

## 7. Conflict of Interest

None.

## Acknowledgements

None.

## References

1. Nair PNR. On the causes of persistent apical periodontitis: a review. *Int Endod J.* 2006;39(4):249–81.
2. Lin LM, Ricucci D, Kahler B. Central Bringing Excellence in Open Access Radicular Cysts Review. *Radicular Cysts Review . JSM Dent Surg.* 2017;2(2):1017.
3. Firkova E, Bouka M. Laser doppler flowmetry in the evaluation of periodontal health and disease. *J IMAB - Ann Proce (Scientific Papers).* 2019;25(3):2599–602.
4. Wang LL, Olmo H. Odontogenic Cysts. StatPearls [Internet]; 2022. [cited 2024 Feb 11]. Available from: <https://www.ncbi.nlm.nih.gov/books/NBK574529/>.
5. Dremin V, Kozlov I, Volkov M, Margaryants N, Potemkin A, Zherebtsov E, et al. Dynamic evaluation of blood flow microcirculation by combined use of the laser Doppler flowmetry and high-speed videocapillaroscopy methods. *Journal of biophotonics.* 2019;12(6):e201800317. doi:10.1002/jbio.201800317.
6. Bøgehøj M, Emmeluth C, Overgaard S. Blood flow and microdialysis in the human femoral head. *Acta Orthop.* 2007;78(1):56–62.
7. Nötzli HP, Siebenrock KA, Hempfing A, Ramseier LE, Ganz R. Perfusion of the femoral head during surgical dislocation of the hip. Monitoring by laser Doppler flowmetry. *J Bone Joint Surg Br.* 2002;84(2):300–4.
8. Jafarzadeh H. Laser Doppler flowmetry in endodontics: a review. *Int Endod J.* 2009;42(6):476–90.
9. Orekhova LY, Barmasheva AA. Doppler flowmetry as a tool of predictive, preventive and personalised dentistry. *EPMA J.* 2013;4(1):21. doi:10.1186/1878-5085-4-21.
10. Hoke JA, Burkes EJ, White JT, Duffy MB, Klitzman B. Blood-flow mapping of oral tissues by laser Doppler flowmetry. *Int J Oral Maxillofac Surg.* 1994;23(5):312–5.
11. Kouadio AA, Jordana F, Koffi NJ, Bars P, Soueidan A. The use of laser Doppler flowmetry to evaluate oral soft tissue blood flow in humans: A review. *Arch Oral Biol.* 2018;86:58–71. doi:10.1016/j.archoralbio.2017.11.009.
12. Khambete N, Kumar R. Ultrasound in differential diagnosis of periapical radiolucencies: A radiohistopathological study. *J Conserv Dent.* 2015;18(1):39–43.

## Author biography

**Bogdan Petrov Krastev**, PhD  <https://orcid.org/0000-0002-1793-0277>

**Ivan Atanasov Filipov**, Professor  <https://orcid.org/0000-0001-9402-2881>

**Cite this article:** Krastev BP, Filipov IA. Laser doppler flowmetry microcirculation assessment of a periapical cyst. *IP Indian J Conserv Endod* 2024;9(2):79-83.