



## Case Report

# Unusual occlusal morphology of permanent maxillary second molar and mandibular first molar: A case report

Harpuneet Kaur<sup>1\*</sup>

<sup>1</sup>National Dental College & Hospital, Dera Bassi, Punjab, India



## ARTICLE INFO

### Article history:

Received 15-07-2024

Accepted 08-08-2024

Available online 05-09-2024

### Keywords:

Occlusal surface

Permanent maxillary second molar

Permanent mandibular first molar

Morphology

## ABSTRACT

Typically, maxillary second molars have a different number, size, and arrangement of cusps than molar teeth, which have four cusps and a square occlusal surface. Mandibular molars are considerably less likely to have an oblique ridge, and buccal accessory cusps are very rare. This case study aimed to describe a unique case of a permanent maxillary second molar and a permanent mandibular first molar with an oblique that resembled the maxillary molar crown.

This is an Open Access (OA) journal, and articles are distributed under the terms of the [Creative Commons Attribution-NonCommercial-ShareAlike 4.0 License](#), which allows others to remix, tweak, and build upon the work non-commercially, as long as appropriate credit is given and the new creations are licensed under the identical terms.

For reprints contact: [reprint@ipinnovative.com](mailto:reprint@ipinnovative.com)

## 1. Introduction

When it comes to the natural function of grinding, the maxillary second molar teeth help the first molars whereas other developmental defects, such as accessory cusps or talon cusps that protrude from the cingulum, may cause interference.<sup>1,2</sup> Molar teeth typically feature four cusps, most likely with a square occlusal surface; however, the number, size, and arrangement of cusps on maxillary second molars might vary. Shape and pattern variations in the cusp are either inherited or generated as a result of gene, lifestyle, culture, and adaptive processes. First molar departure from normal morphology occurs 5–6% of the time;<sup>2,3</sup> maxillary second molar morphology is poorly understood. The second molar's occlusal characteristics are rhomboidal in shape and include an acute angle protrusion, whereas obtuse angles have a bigger buccolingual size and a smaller mesiodistal diameter. Nonetheless, there is documented morphological variance in dentitions both internationally and domestically.<sup>2,4</sup> most of these variations in form have an impact on the tooth's crown.<sup>5,6</sup> There is significant variation in the patterns of grooves and fissures on the occlusal

surface of maxillary molars compared to mandibular molars. According to reports, an oblique ridge is even less common in mandibular molars, and buccal accessory cusps are extremely uncommon.<sup>5,7,8</sup> The goal of the current case report was to describe an unusual Permanent Maxillary second molar and Permanent mandibular first molar with an oblique resembling the crown of the maxillary molar.

## 2. Case Report

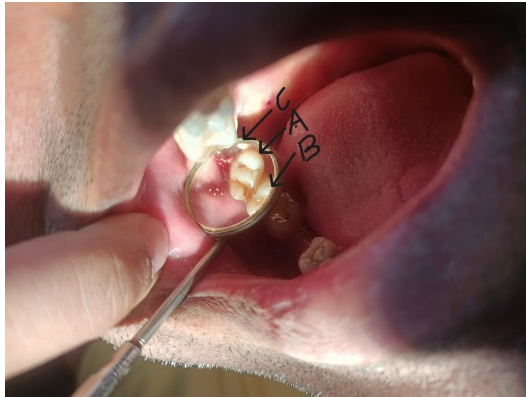
Two patients, one, a male aged 45 years (Case 1) and the other, a female aged 35 years (Case 2) reported separately on different days to the Dental Department for routine checkup. The two patients were not related to one another in any way. Both patients were healthy with no relevant medical history. In both patients, routine oral examinations were carried out. Ethical clearance was taken. Written informed consent was obtained from patients for publication of this case report and the pictures.

In case 1, on intra oral examination, it was interested to find the presence of rather unusual occlusal morphology in the maxillary second permanent right molar. From occlusal view, the crown was of oval shaped. The occlusal surface shows the presence of two grooves, and three cusps as

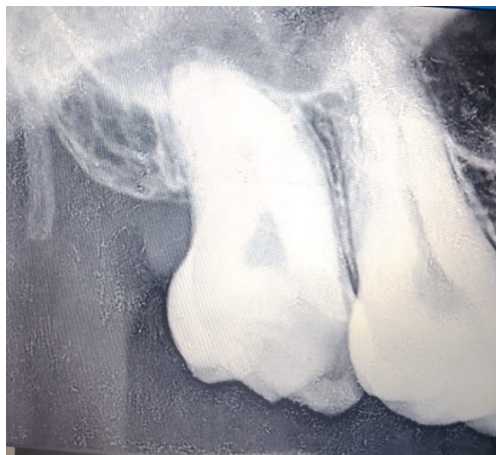\* Corresponding author.

E-mail address: [drkaur071993@gmail.com](mailto:drkaur071993@gmail.com) (H. Kaur).

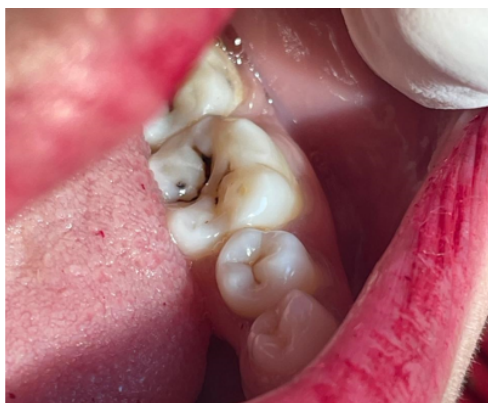shown in the Figure 1.



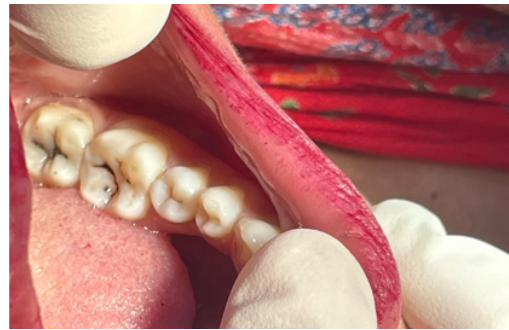**Figure 1:** Indirect view showing unusual morphology of maxillary second molar; **A:** Normal morphology of maxillary first molar; **B:** Carious maxillary third molar; **C:** In the oral cavity



**Figure 2:** Intraoral radiograph showing permanent maxillary second molar and maxillary third molar



**Figure 3:** Intraoral photograph of mandibular first left molar showing mimicking maxillary first molar.



**Figure 4:** Intraoral photograph of mandibular first left molar showing mimicking maxillary first molar.

In case 2, on intraoral examination, the occlusal surface of tooth 36 had unusual groove pattern. A well-developed oblique ridge was seen extending between Mesiolingual cusp and Distobuccal cusp, giving the tooth occlusal morphology appearance of a maxillary permanent first molar (\$).

### 3. Discussion

The forms of primate teeth reflect ecological and developmental factors. Development may both promote and impede the emergence of new tooth forms. The same genes are used by many different organs, such as teeth, and limbs, as part of the genetic machinery involved in development. Moreover, a "developmental module" is formed within a tooth when a single cusp develops using the same set of developing genes again. The cumulative diversity in later-developing cusps can be explained by the recurrent activation of the developmental module. As a result, short later-developing cusps might be more homoplastic but also evolvable. The variability of dental characters and character states associated with cusp commencement can be explained by the patterning cascade paradigm of cusp development.<sup>9,10</sup>

Less is now known about the developmental basis and variational features of the cusp configuration, cusp form, and crown termination characters. For dental features, a straightforward "gene to phenotype" map is unlikely to exist. Instead, the activation of the developmental modules is the result of a dynamic developmental program, which is what gives rise to the entire cusp pattern.<sup>9,10</sup>

The morphologist, clinical dentist, and anthropologist are all quite interested in the morphology of the human tooth, particularly the variance in cusp numbers and patterns. Seldom may an additional cusp, referred to as Cusp 6, be observed in the permanent or primary mandibular molars, especially the first molars. Supernumerary cusp 6 is located lingually to the distobuccal cusp at the distal edge of the crown. According to the material currently in publication, Cusp 6 is also referred to by other names,

such as "Tuberculum Sextum" or "Entoconulid," which are anthropological word.<sup>11</sup> However, the patient in the present case report showed the permanent first mandibular molar occlusal cusp morphology resembling permanent maxillary first molar.

There have long been morphological differences between the root and crown components of human teeth. The changes in corono-morphology may manifest as additional cusp absent or present. The maxillary permanent first molars are the largest and most highly anchorage-valued teeth in the maxillary arch and are distinguished by their five and four cusp patterns, if current with the Carebelli cusp. There are in fact three cusped permanent maxillary first molars. They ought to be meticulously documented and documented in scholarly works. Three cusped permanent maxillary first molars were identified in four occurrences, all of which were in females. This could suggest that women predominate in these kinds of events. Three cusped permanent maxillary first molars were found unilaterally in all four cases. This could point to a modification in the morphologic behaviour of the growing molar that is site-specific. Clinical therapy should take into account the broad single palatal cusp. Using IOPAs and/or CBCT, more research may be done on patients with three cusps on the permanent maxillary first molar to assess the quantity and size of roots, canal morphology, etc.<sup>12</sup> Maxillary second molars can occasionally exhibit incredibly unusual variations in size and shape. This article's goal is to provide an example of a maxillary second molar that mimics a maxillary premolar. Reduced size and quantity of cusps are quite interesting to anthropologists because they indicate changes in the evolutionary process.<sup>13</sup> The present case report showed the presence of three cusps in the permanent maxillary second molar.

#### 4. Conclusion

The second molar's occlusal shape is rhomboidal, with an acute angle protrusion, whereas obtuse angles have a larger buccolingual size and a smaller mesiodistal diameter. Mandibular molars are much less likely to have an oblique ridge. However, this reported the case of maxillary molar with unusual occlusal morphology and mandibular molar with an oblique ridge, which is uncommon to find. Cusp shape and pattern variations are either inherited or generated by gene, lifestyle, culture, and adaptive mechanisms.

#### 5. Source of Funding

None.

#### 6. Conflict of Interest

None.

#### References

1. Guven Y, Kasimoglu Y, Tuna EB, Gencay K, Aktoren O. Prevalence, and characteristics of talon cusps in the Turkish population. *Dent Res J (Isfahan)*. 2016;13(2):145-50.
2. Shafiq N, Khan D, Aleem S, Dil F, Nausheen N, Kifayat J, et al. Morphological characteristics of cusps..... Morphological characteristics of cusps and occlusal features of maxillary second molars; cross-sectional study in khyber college of dentistry. *JKCD*. 2019;9(3):69-73.
3. Arisu HD, Alacam T. Diagnosis and Treatment of Three-Rooted Maxillary Premolars. *Eur J Dent*. 2009;3(1):62-6.
4. Sarpangala M, Devasya A. Occurrence of Cusp of Carabelli in Primary Second Molar Series of three Cases. *J Clin Diagn Res*. 2017;11(3):1-2.
5. Sakamuri S, Mallineni SK. An Unusual Mandibular Second Molar Mimicking Maxillary First Molar - A Rare Occurrence. *Periodontics Prosthodontics*. 2018;4(1). doi:10.21767/2471-3082.100037.
6. Curzon ME, Curzon JA, Poyton HG. Evaginated odontomesin the Keewan Eskimo. *Br Dent J*. 1970;129(7):324-8.
7. Ling JKY, Wong RKW. Incisal Morphology of Southern Chinese. *Open Anthropol J*. 2010;1:19-25. doi:10.2174/1874912700801010019.
8. King NM, Tongkoom S, Itthagarun A, Wong HM, Lee CK. A catalogue of anomalies and traits of the primary dentition of southern Chinese. *J Clin Pediatr Dent*. 2008;32(2):139-46.
9. Jernvall J, Jung HS. Genotype, phenotype and developmental biology of molar tooth characters. *Am J Phys Anthropol*. 2000;31:171-90. doi:10.1002/1096-8644(2000)43:31+<171::aid-ajpa6>3.0.co;2-3..
10. Hegde S, Nayak UA. Unusual occlusal morphology of mandibular first permanent molar: A case report. *Int Chin J Dent*. 2003;3:1-6.
11. Nagaveni N. Rare Occurrence of 'Tuberculum Sextum' (Cusp 6 or Entoconulid) in the Permanent Mandibular First Molar-A Case Report. *Open Access J Dent Sci*. 2024;9(1):1-4. doi:10.23880/oajds-16000393.
12. Jain S. Variation in Cuspal Morphology in Maxillary First Permanent Molar with Report of 3 Cusp Molar- A Prevalence Study. *J Clin Diagn Res*. 2016;10(9):34-6.
13. Nagaveni NB. Premolarization of the Permanent Maxillary Second Molars- Report of A Rare Case. *J Dent Oral Health*. 2023;10:1-8.

#### Author biography

**Harpuneet Kaur**, Former BDS Graduate

**Cite this article:** Kaur H. Unusual occlusal morphology of permanent maxillary second molar and mandibular first molar: A case report. *IP Indian J Conserv Endod* 2024;9(3):139-141.