

Mineral Trioxide Aggregate-A Review

Sarita Singh^{1*}, Jyoti Mandlik², Kalpana kanyal³, Rajendra Danle⁴, Abhijit Jadhav⁵

^{1,2}Associate Professor, ^{3,4,5}Assistant Professor, Dept. of Cons & Endo, BUP Dental College & Hospital, Pune, Maharashtra

***Corresponding Author:**

Email: drsaritavsingh@gmail.com

Abstract

Mineral Trioxide Aggregate (MTA) is a new material with numerous exciting clinical applications. MTA promises to be one of the most versatile materials of this century in the field of dentistry. Some of the appreciable properties of MTA include its good physical properties and its ability to stimulate tissue regeneration as well as good pulp response. In this article the availability, composition, manipulation, setting reaction, properties and clinical applications of MTA in dentistry has been reviewed.

Keywords: Mineral Trioxide Aggregate, Root end Filling material, Grey and White MTA.

Introduction

MTA was developed in Loma Linda University in 1990's by Torabinejad as a root end filling material. It received acceptance by the US Federal Drug Administration in 1998. Since its approval MTA became commercially available as Pro Root MTA until two commercial forms of MTA have been available namely the Grey and white MTA with similar chemical and physical properties.

Since its first description in the dental literature by Lee & colleagues in 1993, MTA has been used in both surgical and non surgical applications including root end filling, direct pulp capping, pulpotomy, perforation repair, furcation repair, apexification and obturation. This material holds promise because of its sealing capabilities, ability to set up in the presence of blood, biocompatibility and its capability to induce hard tissue formation.

What is MTA?

MTA is a powder consisting of fine hydrophilic particles of tricalcium silicate, tricalcium aluminate, tricalcium oxide and silicate oxide. It also contains small amounts of other mineral oxides, which modify its chemical and physical properties.⁽¹⁾ Hydration of the powder results in formation of colloidal gel with a pH value equal to 12.5 that solidifies to form a strong impermeable hard solid barrier in approximately three to four hours.⁽²⁾ The material has a low solubility and a radio-opacity slightly greater than that of dentin. Because it has low compressive strength,⁽²⁾ it should not be placed in functional areas.

Availability: Some of the commercially available MTA are ProRoot MTA (Dentsply) (Fig.1), White ProRoot MTA (Dentsply), MTA- Angelus (Solucoes Odontologicas), MTA- Angelus Blanco (Solucoes Odontologicas) (Fig.2), MTA Bio (Solucoes Odontologicas).⁽³⁾ The important barriers to the widespread use of MTA are its cost and difficulty in storage. The cost of MTA (single use) is approximately 60-75 USD.⁽³⁾



Fig. 1

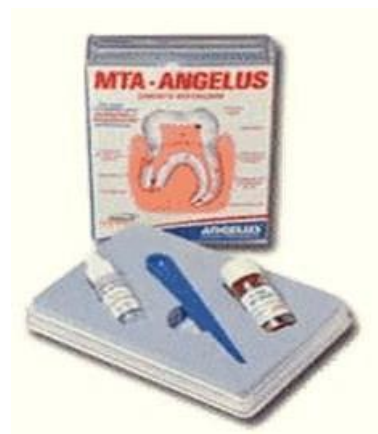

Fig. 2

Composition

MTA consists of tricalcium silicate, tricalcium aluminate, tricalcium oxide, silicate oxide and bismuth oxide.⁽⁴⁾ Its composition is said to be similar to Portland cement except for the absence of bismuth oxide. Bismuth oxide is added (17-18 wt %) to improve the properties and the radioopacity.⁽⁴⁾ The MTA particles are smaller and uniform in size,⁽⁵⁾ whereas the particle size of Portland cement varies in size. Though Bismuth oxide is said to improve the radio opacity, MTA-Angelus that contain less bismuth oxide compared to ProRoot MTA, is more radio opaque than

Pro-Root MTA.⁽⁶⁾ MTA are of two types- grey and white. The white and grey MTA differs mainly in their content of iron, aluminium and magnesium oxides. Asgary et al claim that these oxides are present in less quantity in white MTA⁽⁷⁾ while others^(6,8) claim total absence of these oxides in white MTA. White MTA contains smaller particles with a narrower range of size distribution than grey MTA.⁽⁹⁾ The chemical analysis and X-ray diffraction have demonstrated that 18.8% of the material is insoluble in water and its crystallinity is close to 80%.⁽¹⁰⁾

Manipulation and Setting Reaction: The MTA paste is obtained by mixing 3 parts of powder with 1 part of water to obtain putty like consistency. Mixing can be done on paper or on a glass slab using a plastic or metal spatula. This mix is then placed in the desired location and condensed lightly with a moistened cotton pellet.⁽¹¹⁻

¹³⁾ MTA has a pH of 10.2 immediately after mixing and increases to 12.5 after 3 hours of setting which is almost similar to calcium hydroxide.⁽⁴⁾ MTA takes longer time to set compared to any other material. According to Torabinejad and colleagues the setting time of grey MTA is about 2 hours and 45 minutes (+5minutes),⁽⁴⁾ whereas Islam et al reported 2 hours and 55 minutes for grey MTA and 2 hours and 20 minutes for white MTA.⁽¹⁴⁾ Extended setting period of MTA is one of its main drawbacks. It is suggested by many investigators that the incorporation of accelerators such as sodium phosphate dibasic (Na₂HPO₄) and calcium chloride (CaCl₂) may reduce the setting time.⁽¹⁴⁻¹⁵⁾ After mixing, the mix should not be left open on the slab as it undergoes dehydration and dries into a sandy mixture.⁽¹³⁾ It should be used immediately after it is prepared.

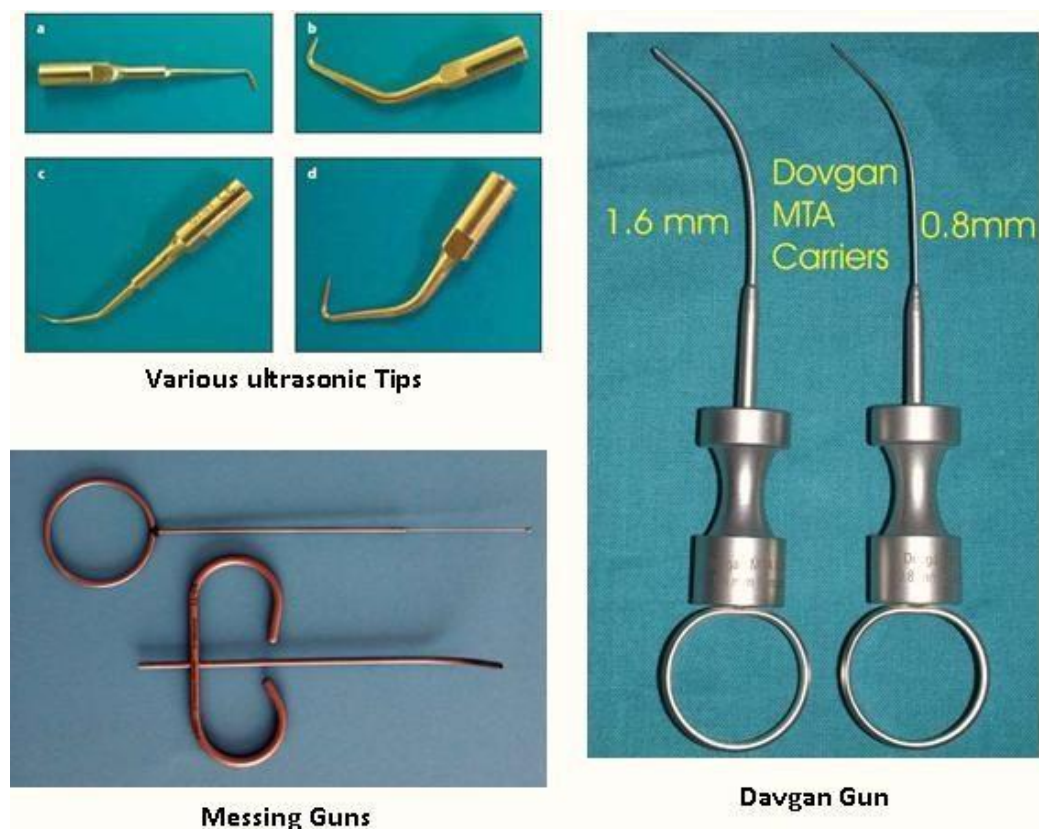


Fig. 3

MTA may be placed into the desired location using hand instruments or ultrasonic condensation. Hand condensation is done with the help of a plugger, paper point or messing gun⁽¹³⁾ (Fig.3). Ultrasonic condensation is done by first placing a hand instrument such as a condenser in direct contact with the MTA. Then an ultrasonic instrument is placed touching the shaft of the hand instrument and activated for several seconds.⁽¹⁶⁾

Properties of Mineral Trioxide Aggregate:

- 1. Compressive strength:** It takes an average of three to four hours for the MTA material to completely solidify. Compressive strength of MTA within 24 hours of mixing was about 40.0 MPa and increases to 67.3 MPa after 21 days.⁽⁴⁾ In comparison grey MTA exhibited greater compressive strength than white MTA.⁽¹⁷⁾
- 2. Radio-opacity:** MTA is less radio opaque than IRM, Super EBA, amalgam or gutta-percha and

- has similar radio density as Zinc Oxide Eugenol.⁽¹⁸⁻¹⁹⁾ The mean radio opacity of MTA is 7.17 mm of equivalent thickness of aluminium, which is sufficient to make it easy to visualize radiographically.⁽⁴⁾
3. **Solubility:** Although the set MTA shows no signs of solubility, the solubility might increase if more water is used during mixing. The set MTA when exposed to water releases calcium hydroxide which might be responsible for its cementogenesis inducing property.⁽²⁰⁾
 4. **Marginal adaptation and sealing ability:** This property is most vital for any restorative material especially when used for root end filling, repair of perforations, Pulp capping or pulpotomy procedures. MTA expands during setting which may be the reason for its excellent sealing ability.⁽²¹⁾ According to Torabinejad et al MTA seals very superiorly and no gaps were found in any of the experimental specimen.⁽¹⁷⁾ However, amalgam, Super EBA and IRM exhibited gaps ranging from 3.8 to 14.9 microns. MTA has also proved itself to be superior in the bacterial leakage test by not allowing the entry of bacteria at the interface.⁽²²⁾ MTA thickness of about 4 mm is sufficient to provide a good seal.⁽²³⁾
 5. **Antibacterial and antifungal property:** By virtue of providing a good seal and preventing micro leakage, it can be proclaimed as an antibacterial agent especially against *Enterococcus faecalis* and *Streptococcus sanguis* in vitro.⁽²⁴⁾ But Torabinejad et al reported that MTA shows no antimicrobial activity against any of the anaerobes but did have some effect on five (*S.mitis*, *S.mutans*, *S.salivarius*, *Lactobacillus* and *S.epidermidis*) of the nine facultative bacteria.⁽²⁵⁾ Since most of the flora in the root canal are strict anaerobic bacteria with few facultative anaerobes, MTA may not be beneficial as a direct antibacterial in endodontic practice.
 6. **Reaction with other dental materials:** MTA does not react or interfere with any other restorative material. Glass Ionomer cements or composite resins, used as permanent filling material do not affect the setting of MTA when placed over it.⁽²⁶⁾
 7. **Biocompatibility:** Any material that is identified to be used in humans or animals should be biocompatible without having toxic or injurious effects on biologic tissues and its function. Kettering and Torabinejad studied MTA in detail and found that it is not mutagenic and is much less cytotoxic compared to Super EBA and IRM.⁽²⁷⁾ This supports the superiority of MTA over formocresol as a pulpotomy medicament. Genotoxicity tests of cells after treatment of peripheral lymphocytes with MTA showed no DNA damage.⁽²⁸⁾ On direct contact they produce minimal or no inflammatory reaction in soft tissues and in fact are capable of inducing tissue regeneration.⁽²⁹⁾ In animal studies, MTA produced cementum growth which was very unique compared to other root-end filling materials.⁽³⁰⁾ Arens and Torabinejad reported osseous repair of furcation perforations treated with MTA.⁽³¹⁾ MTA showed good interaction with bone-forming cells: cells remained viable and released collagen even after 72 hours with good adherence.⁽³²⁾
 8. **Tissue regeneration:** MTA is capable of activation of cementoblasts and production of cementum.⁽³⁰⁾ It consistently allows for the overgrowth of cementum and also facilitates regeneration of the periodontal ligament.
 9. **Mineralization:** MTA, just like calcium hydroxide, induces dentin bridge formation.⁽³³⁾ Many investigators believe that the hard tissue bridge deposited next to MTA is because of the sealing property, biocompatibility, alkalinity and other properties associated with this material.⁽¹³⁾

Clinical applications for ProRoot® MTA

Because of its unique features and benefits, ProRoot® MTA offers distinct advantages over other materials for these root canal repair procedures:

• Repair of root perforations during root canal therapy

Perforations are the result of procedural error in which a communication between the pulp canal and the periradicular tissue occurs. ProRoot® MTA can be used to seal perforations.

• Repair of root resorption

Internal root resorption is an idiopathic condition resulting in the breakdown or destruction of root structure. ProRoot® MTA can seal the resorptive defect.

• Root-end filling

Root-end filling is required when an endodontic case can best be treated or retreated with a surgical (extra-radicular) rather than an intra-radicular approach. ProRoot® MTA has excellent sealing ability and allows periradicular healing when used as a root-end filling material during periradicular surgery.

• Apexification

ProRoot® MTA is an excellent material for apexification because ProRoot® MTA creates a permanent apical plug at the outset of treatment.

• Pulp capping

Vital pulp therapy may be indicated in certain clinical situations.

Placing ProRoot® MTA over the exposed area often allows healing and preservation of the vital pulp without further treatment.

Because of its unique features and benefits, ProRoot® MTA offers distinct advantages over other materials for these root canal repair procedures.

• Repair of root perforations during root canal therapy

Perforations are the result of procedural error in which a communication between the pulp canal and the periradicular tissue occurs. ProRoot® MTA can be used to seal perforations.

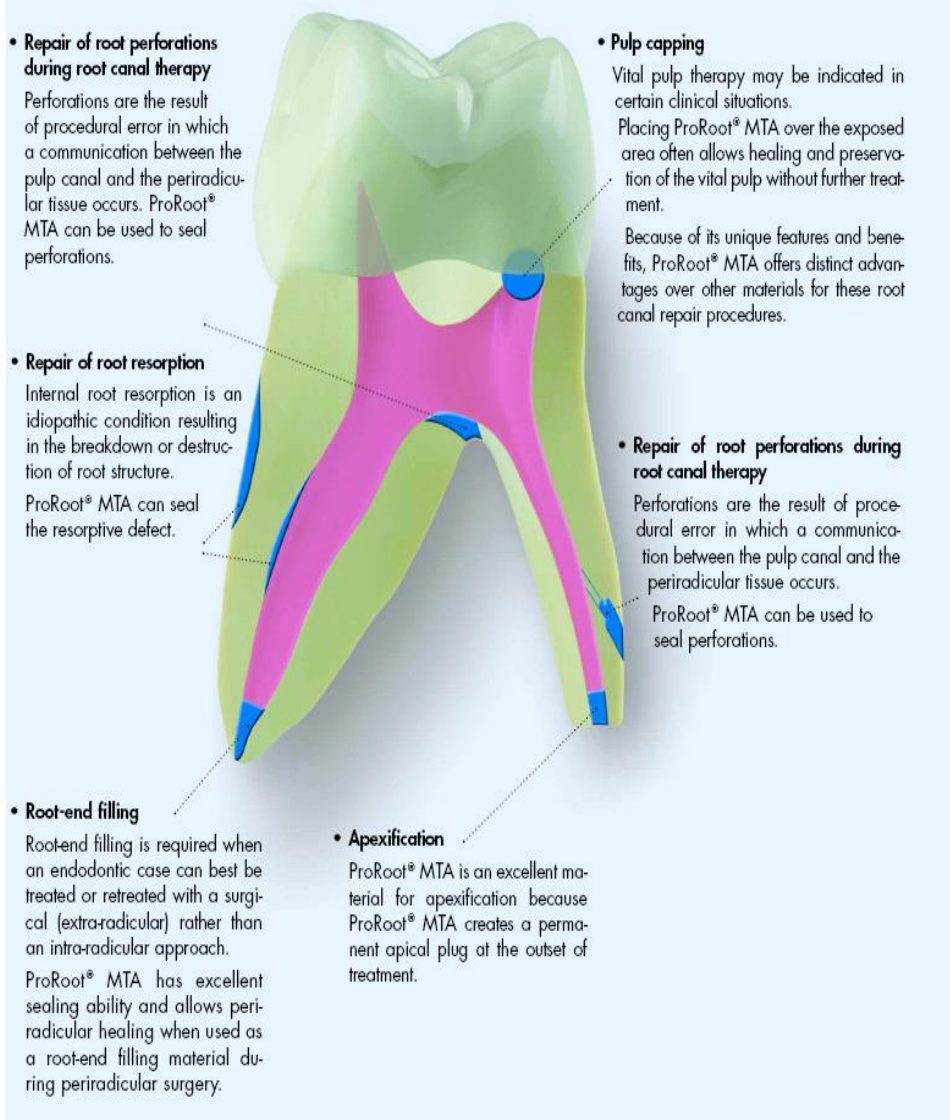


Fig. 4: Clinical Applications

- 1. Root-End Filling of Immature Permanent Teeth:** Endodontic surgery followed by root-end filling may at times be necessary for certain teeth where routine endodontic treatment is not possible. This procedure involves surgical exposure of the root apex, root resection and plugging the apical foramen with a suitable material that provides complete apical seal, is non toxic, non resorbable, dimensionally stable and radio opaque.⁽²⁵⁾ MTA treated teeth exhibited significantly less inflammation, more cementum formation and regeneration of periradicular tissues.⁽³⁰⁾
- 2. Pulp Capping:** MTA has been proposed as a potential medicament for capping of pulps with reversible pulpitis because of its excellent tissue compatibility.⁽³³⁾ It is much superior to the routinely used calcium hydroxide based on the tissue reaction and the amount and type of dentin bridge formed.⁽³⁴⁾
- 3. Pulpotomy:** Formacresol has been routinely used as a pulpotomy agent for deciduous teeth. But this material has been criticized for its tissue irritating, cytotoxic and mutagenic effects. MTA was tested and found to be an ideal material with low toxic

effects, increased tissue regenerating properties and good clinical results.⁽³⁵⁾

4. **Apical Plug:** Conventional management of an immature non vital permanent tooth is apexification with calcium hydroxide. The purpose of apexification is to obtain an apical barrier so as to prevent the extrusion of the obturating material. But the disadvantage of using calcium hydroxide is the extended time taken for the completion of the procedure which may range anywhere between 3 to 54 months. Other disadvantage of calcium hydroxide as noted by Andreasen et al is that the tooth with calcium hydroxide placed for more than 100 days showed a significant reduction in fracture resistance.⁽³⁶⁾ This problem is solved with the use of MTA. An MTA plug of 4mm thickness placed at the apical region is adequate to form a barrier, sealing the canal from the periapical area.
5. **Obturation of the Canal:** Mineral Trioxide Aggregate can be used to obturate the root canal of a retained primary tooth where the succedaneous permanent tooth is absent. One such application on a retained primary mandibular second molar was reported by O'Sullivan and Hartwell.⁽³⁷⁾ This technique is not recommended for obturation of primary teeth that are expected to exfoliate since it is anticipated that Mineral Trioxide Aggregate would be absorbed slowly, if at all.
6. **Repair of Perforation:** Root perforation can be iatrogenic or due to severe extension of internal resorption leading to a communication between the root canal and the periodontium. There may be severe inflammation and granulation tissue formation with extensive hemorrhage. Repairing such a communication requires a material that should be biocompatible, should withstand moisture without dissolving and should have good sealing ability. Lee and associates found that MTA had significantly less leakage and less tendency for overfilling or underfilling, when compared with amalgam and IRM.⁽³⁸⁾
7. **Repair of fracture:**
 - a) **Horizontal Root Fracture:** Schwartz et al described a case of upper central incisor with CI- III mobility and horizontal root fracture.⁽³⁹⁾ The apical portion in which the pulp was vital was left intact. The pulp from the coronal fragment was removed, calcium hydroxide placed in the canal and the tooth splinted. After six weeks, calcium hydroxide was removed from the canal. The canals were dried and MTA was placed at the fracture site as a barrier. The canals were then obturated with gutta percha. At the six month recall, the tooth was asymptomatic.
 - b) **Vertical Root Fracture:** Torabinejad and Chivian have suggested the use of MTA for sealing vertical root fractures. The tooth canal

is first filled with composite resin.⁽¹³⁾ The fracture line is assessed by reflecting a flap. A groove is then made with a small bur along the fracture line using continuous water spray. MTA is placed in the prepared groove, covered with a resorbable membrane and the flap sutured back into place.

8. **To Obtain Coronal Seal before Bleaching:** MTA can be used to provide coronal seal in a tooth that requires internal bleaching. A thickness of 3-4 mm of MTA placed over the condensed gutta percha in the access cavity prevents the ingress of bleaching agents. Wet cotton is placed over the MTA and the remaining cavity filled with temporary restoration.

Conclusion

MTA is an excellent material with innumerable qualities required of an ideal material. Apexification with calcium hydroxide is comparatively unpredictable and also makes the tooth less resistant to fracture. Single visit MTA apical plug placement has proved to be a successful alternative in such cases. MTA is also successful in the formation of a dent in bridge that is thicker with lesser defects and side effects. MTA need to be explored by clinicians so that its beneficial properties can be extracted.

References

1. Torabinejad M, Hong CU, McDonald F, Pitt Ford TR. Physical and chemical properties of a new root-end filling material. *J Endod* 1995 Jul;21(7):349-53.
2. Torabinejad M, Hong CU, Pitt Ford TR, Kettering JD. Antibacterial effects of some root end filling materials. *J Endod* 1995 Aug; 21(8):403-6.
3. Srinivasan V, Waterhouse P, Whitworth J. Mineral trioxide aggregate in paediatric dentistry. *Int J Paediatr Dent*, 2009;19: 34-47.
4. Torabinejad M, Hong CU, McDonald F, Pitt Ford TR. Physical and chemical properties of a new root-end filling materials. *J Endod*, 1995; 21: 349-53.
5. Dammaschke T, Gerth HUV, Zuchner H, Schafer E. Chemical and physical surface and bulk material characterization of white ProRoot MTA and two Portland cements. *Dent Mater*, 2005; 21: 731-738.
6. Song J, Mante FK, Romanow WJ, Kim S. Chemical analysis of powder and set forms of Portland cement, gray ProRoot MTA, Shite ProRoot MTA and Gray MTA-Angelus. *Oral Surg Oral Med Oral Pathol Oral Radiol Endod*, 2006;102: 809-815.
7. Asgary S, Parirokh M, Egbbal MJ, Brink F. Chemical differences between white and gray mineral trioxide aggregate. *J Endod*, 2005; 31: 101-103.
8. Diamaniti E, Kerezoudis NP, Gakis NB, Tsatsas V. Chemical composition and surface characteristics of grey and new white ProRoot MTA. *J Endod*, 2003;36: 946-947.
9. Komabayashi T, Spångberg LSW. Comparative Analysis of the particle size and shape of commercially available mineral trioxide aggregates

- and portland cement: A study with a flow particle image analyzer. *J Endod*, 2008; 34: 94–98.
10. Silva H D, Andrade VLM, Méndez GV, Medellín RFJ et al. Physical chemical analysis of mineral trioxide aggregate (MTA) by X-rays diffraction, colorimetry and electronic microscopy *Rev ADM*, 2000;17: 125–131.
 11. Sluyk SR, Moon PC, Hartwell GR. Evaluation of setting properties and retention characteristics of Mineral Trioxide Aggregate when used as a furcation perforation repair material. *J Endod*, 1998;24: 768–771.
 12. Schmitt D, Lee J, Bogen G. Multifaceted use of ProRoot MTA root canal repair material. *Pediatr Dent*, 2001 23: 326–330.
 13. Torabinejad M, Chivian N. Clinical applications of mineral trioxide aggregate. *J Endod*, 1999; 25: 197–205.
 14. Islam I, Chang HK, YapAUJ. X-Ray diffraction analysis of mineral trioxide aggregate and Portland cement. *Int Endod J*, 2006; 39: 220–225.
 15. Kogan P, He J, Glickman GN, Watanabe I. The effects of various additives on setting properties of MTA. *J Endod*, 2006; 32: 569–572.
 16. Holden DT, Schwartz SA, Timothy CK, Schindler WG. Clinical outcomes of artificial root-end barriers with mineral trioxide aggregate in teeth with immature apices. *J Endod*, 2008;34: 812–817.
 17. Torabinejad M, Smith PW, Kettering JD, Pitt Ford TR. Comparative investigation of marginal adaptation of Mineral Trioxide aggregate and other commonly used root-end filling materials. *J Endod*, 1995; 21: 295–299.
 18. Ding SJ, Kao CT, Shei MY, Hung CJ, Huang TH. The physical and cytological properties of white MTA mixed with Na₂HPO₄ as an accelerant. *J Endod*, 2008;34(6):748-51
 19. J Endod, 34: 897–900, 2008.34. Shah PMM, Chong BS, Sidhu SK, Pitt Fortd T. Radio opacity of potential root end filling materials. *Oral Surg Oral Med Oral Pathol Oral Radiol Endod*, 1996; 81: 476–479.
 20. Budig CG, Eleazer PD. In vitro comparison of the setting of dry Pro- Root MTA by moisture absorbed through the root. *J Endod*, 2008; 34: 712–714.
 21. Shipper G, Grossman ES, Botha AJ, Cleaton-Jones PE. Marginal adaptation of mineral trioxide aggregate (MTA) compared with amalgam as a root-end filling material: a low vacuum (LV) versus high vacuum (HV) SEM study. *Int Endod J*, 2004; 37: 325–336.
 22. Torabinejad M, Rastegar AF, Kettering J, Pitt Ford T. Bacterial leakage of mineral trioxide aggregate as a root end filling material. *J Endod*, 1995; 21: 109–112.
 23. Valois CR, Costa ED Jr. Influence of the thickness of mineral trioxide aggregate on sealing ability of root-end filling in vitro. *Oral Surg Oral Med Oral Pathol*, 2004; 97: 108–111.
 24. Al-Hazaimi K, Al-Shalan TA, Naghshbandi J, Oglesby S, Dimon JSH, Rotstein I. Antibacterial effect of two Mineral Trioxide Aggregate (MTA) preparations against *Enterococcus faecalis* and *Streptococcus sanguis* in vitro. *J Endod*, 2006; 1053–1056.
 25. Torabinejad M, Hong CU, Pitt Ford TR, Kettering JD. Antibacterial effects of some root end filling materials *J Endod*, 1995; 21: 403–406.
 26. Nandini S, Ballal S, Kandaswamy D. Influence of glass ionomer cement on the interface and setting reaction of mineral trioxide aggregate when used as a furcal repair material using laser Raman spectroscopic analysis. *J Endod*, 2006; 33: 167–172.
 27. Kettering JD, Torabinejad M. Investigation of Mutagenicity of Mineral trioxide Aggregate and other commonly used Root end filling materials. *J Endod*, 1995; 21: 537–542.
 28. Braz MG, Camargo EA, Salvadori DMF, Marques MEA, Ribeiro DA. Evaluation of genetic damage in human peripheral lymphocytes exposed to mineral trioxide aggregate and Portland cements. *J Oral Rehab*, 2006; 33: 234–239.
 29. Sumer M, Muglali M, Bodrumlu E, Guvenic T. Reactions of connective tissue to amalgam, intermediate restorative material, mineral trioxide aggregate mixed with chlorhexidine. *J Endod*, 2006;32: 1094–1096.
 30. Torabinejad M, Hong CU, Lee SF, Monsef M, Pitt Ford TR. Investigation of mineral trioxide aggregate for root-end-filling in dogs. *J Endod*, 1995; 21: 603–608.
 31. Arens DE, TorabinejadM. Repair of furcal perforation with mineral trioxide aggregate. *Oral Surg Oral Med Oral Pathol Oral Radiol Endod*, 1996; 82: 84–88.
 32. Pelliccioni GA, Ciapetti G, Cenni E, Granchi D, Nanni M, Pagani S and Giunti A. Evaluation of osteoblast-like cell response to Proroot™ MTA (Mineral Trioxide Aggregate) cement. *Journal of Materials Science: Materials in Medicine*, 2004; 15: 167–173.
 33. Myers K, Kaminski E, Miller. The effects of mineral trioxide Aggregate on the Dog Pulp. *J Endod*, 1996; 22: 198.
 34. Chacko V, Kurikose S. Human pulpal response to Mineral Trioxide Aggregate (MTA): A histologic study. *J Clin Pediatr Dent*, 2006; 30: 203–209.
 35. Eidelman E, Holan G, Fuks AB. Mineral trioxide aggregate vs formacresol in pulp-tomized primary molars: a preliminary report. *Pediatr Dent*, 2001;23: 15–18.
 36. JO, Munksgaard EC, Bakland LK. Comparison of fracture resistance in root canals of immature sheep teeth after filling with calcium hydroxide or MTA. *Dent Traumatol*, 2006;22: 154–156.
 37. O’Sullivan S.M. and G.R. Hartwell. Obturation of a retained primary mandibular second molar using mineral trioxide aggregate: a case report. *J Endod*, 2001;27: 703–705.
 38. Lee SJ, Monsef M, Torabinejad M. Sealing ability of a mineral trioxide aggregate for repair of lateral root perforations. *J Endod*, 1993;19: 541–544.
 39. Schwartz R S, Mauger M, Clement D J, Walker WA. Mineral Trioxide Aggregate: A new material for endodontics. *J Am Dent Assoc*, 1999;30:967–975.