

Use of novel method of fibersite preshaped abutment post for the aesthetic treatment of severely compromised maxillary central incisor with 1 year follow-up a case report

Shaik Izaz^{1,*}, Bolla Nagesh², Bhargavi Dasari³, Prasanna Sirla⁴, Mallikarjun Elaparolu⁵

^{1,4,5}Post Graduate, ²HOD, Dept. of Conservative Dentistry & Endodontics, Sibar Institute of Dental Sciences, Guntur, ³Senior Lecturer, KIMS Dental College, Amalapuram, A.P, Preceptor, Oral & Maxillofacial Radiology, Rutgers School of Dental Medicine, Newark, New Jersey

***Corresponding Author:**
Email: shaik.ajas@gmail.com

Abstract

Knowledge about the stability and placement techniques of fiber posts cemented in canal spaces over time scarce in the literature. Thus, the purpose of this case report was to evaluate the performance of a novel fibersite preshaped abutment post in a canal space over the course of 1 year.

Keywords: Aesthetics, Fibersite, Maxillary central incisor.

Introduction

Non-restored devitalized teeth are structurally compromised and represent one of the greatest challenges for the clinician. In such cases, preservation of dentin is during the root canal and post endodontic procedures are the prime factors to improve the clinical longevity and success of the final restoration. The known ideal method for restoration of devital teeth for the past two decade are very few that includes prefabricated or the custom made metallic-post and cores and full crowns.⁽¹⁾ Tooth-colored fiber posts were introduced in the 1990s and have several advantages over conventional metal posts. They are aesthetic, bond to tooth structure, have a modulus of elasticity similar to that of dentin but still require dentin preparation to fit into the canal. Lately, fiber reinforcement systems have been introduced in the attempt to increase RBC durability and damage tolerance. However this standard fiber post does not adapt well to a flared root canal preparation, leaving a large cement space between the post and the tooth structure. Direct anatomic posts are the one which provide an alternative technique for restoring these teeth with less chance of debonding.⁽²⁾ Very few case reports have been reported on the technique used to reinforce the tooth using prefabricated anatomical post.⁽³⁾ This case report describes the novel method of anatomical post placement in severely damage devitalized teeth in maxillary left central incisor with 2 year follow-up.

Case Report

A 30-year-old female patient reported to the department of conservative dentistry and endodontics with a chief complaint of caries in upper front tooth region for the past 2 years. Medical history of the patient was non-contributory. On clinical examination

the tooth was discoloured and grossly decayed and there were no sign of sinus tract in relation to tooth 21 [Fig.1a]. Radiographic examination revealed dental caries involving the pulp and radiolucency involving the apex of the tooth 21 [Fig.3a]. Pulp sensibility test of the same tooth with an electric pulp tester (Ashoo Sons API Pulp Tester, Delhi, India) showed negative response. Based on the clinical and radiographic findings, tooth 21 was diagnosed as irreversible pulpitis with periapical abscess. Root canal treatment followed by post and crown was advised for the afore-mentioned tooth. Two treatment protocols were explained to the patient before the endodontic treatment i.e., cast post with crown and tooth reinforcement with fiber post and crown. Due to lose of extension of the crown structural, reestablishment of the lost crown structure was needed for aesthetic and functional recovery. The patient was economically affordable opted for fiber post. With the patients consent, the treatment of maxillary left central incisor was initiated with endodontic treatment followed by Fibersite (Megadenta Italia) fiber post placement (**Fig. 4**).

Procedure

Caries removal was done before the root canal procedure [Fig. 1b, 1c]. Access opening was performed on left maxillary central incisor and working length was determined radiographically. The apical preparation was done until 60 K file and corresponding gutta percha was selected as master cone. Obturation was performed with lateral condensation technique and was seared at the cement-enamel junction. Later, with the help of no-2, 3 gates glidden drills, the guttapercha was removed leaving 5 mm intact in the apical region [Fig. 3b]. The post space was prepared with 0.4 drill given by the manufacturer [Fig. 1d]. The coronal part upto the CEJ was further shaped with the help of bur guide, which

accommodates the abutment as a replacement of lost coronal architecture. The caliber was then introduced into the canal. The length of the caliber was adjusted and the coronal cap was moved apically upto 2 mm. This marking was transferred to the corresponding Fibersite of diameter 0.4 and the apical part was sectioned with the help of diamond disk. The fit was checked clinically and radiographically and adequate seating of the abutment was confirmed [Fig. 2a, 2b, 3c]. Acid etching was done with 30% phosphoric acid and was rinsed with water. The canal was dried with the help of paper points. Bonding agent (Single Bond Universal Adhesive) was applied to the Fibersite post and was cured for 15 seconds. The coronal tooth

structure and post space was entirely coated with the bonding agent. The canal was loaded with dual cure composite resin (X200 A2 Dual Cured Adhesive Resin Composite Luting Cement) and the Fibersite post was positioned and light cured for 30 seconds.

The crown build was done with flowable composite to reach all the discrepancies and remaining was restored with nano-filled composite (Filtek™ Z250XT Nano Hybrid Universal Restorative) [Fig.2c, 2d, 3d]. Crown preparation was done and impressions were registered. Single unit porcelain fused metal ceramic crown was fabricated and cemented [Fig.3e]. 1 year follow-up IOPAR [Fig. 3f]

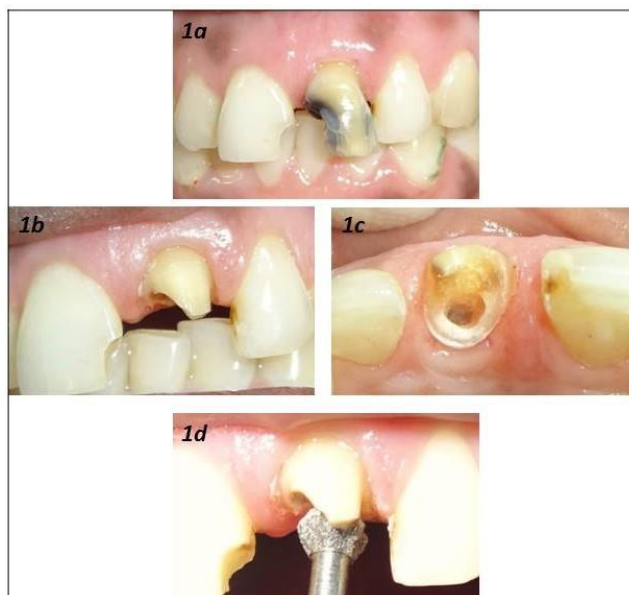


Fig. 1

- 1a: Pre-operative intraoral view
 1b, 1c: Buccal and palatal intra oral view of maxillary left central incisor after caries removal
 1d: Post space preparation with 0.4 drill given by the manufacturer

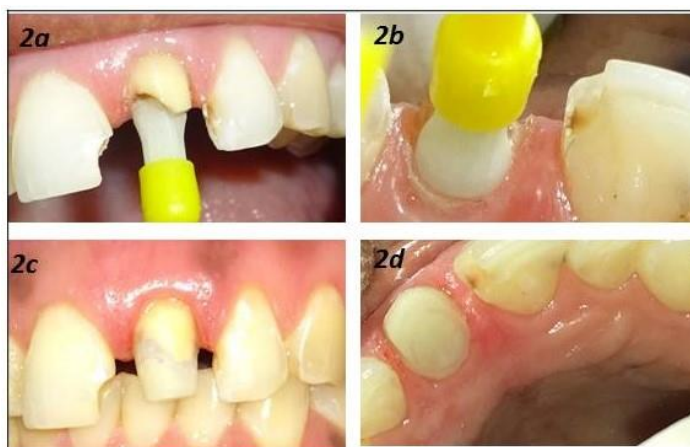

Fig.2

- 2a, 2b: Buccal and palatal intra oral view of maxillary left central incisor with fibersite post check-in
 2c, 2d: Immediate post-operative intra-oral view of maxillary left central incisor with core build-up

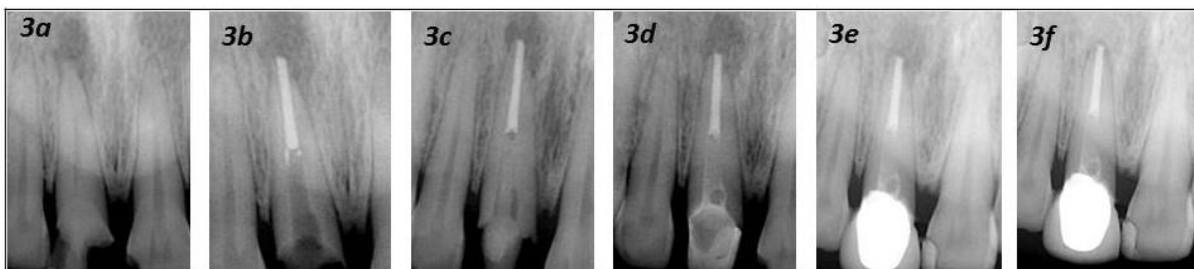

Fig. 3

- 3a: Pre-operative intra-oral IOPAR
- 3b, Post space preparation with no:2, 3 gates gilliden drills and Special guide drill provided by manufacturer
- 3c: Fibersite post check-in done
- 3d: Immediate post-operative IOPAR with post cementation and core build-up
- 3e: Post-operative IOPAR with crown
- 3f: 1 year follow-up IOPAR

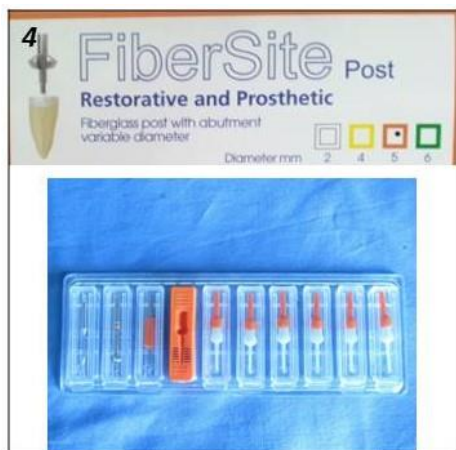
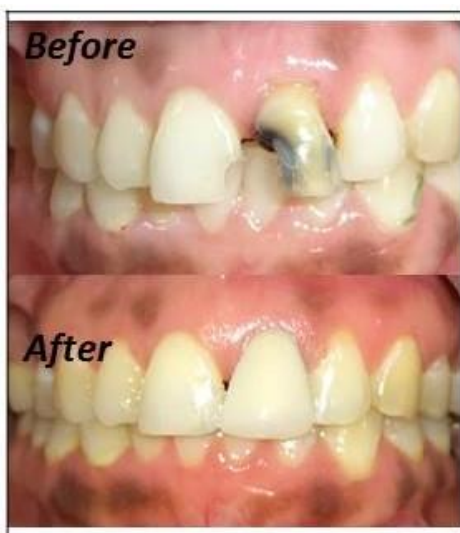

Fig. 4

Fibersite post with drill, guide and posts radiograph.



Discussion

Badly broken down teeth generally poses a great difficulty for the rehabilitation of both function and

aesthetics. Based on the function it much more difficult in the anterior teeth, as it is more prone to stresses at the cervical level. The loss of coronal architecture accounts for 50% of loss of resistance to accommodate and support the forces. Hence the replacement of the lost coronal structure in the core as a single unit helps in reinforcing and withstanding the cervical stress.⁽⁴⁾

Currently, the main reason for using posts is recognized to be a connection of the replacement for the missing coronal portion of the tooth to the remaining tooth structure, thereby providing retention for the crown.⁽⁵⁾

The likelihood of survival of a pulpless tooth is directly related to the quantity and quality of remaining dental tissue. The longevity of endodontically involved teeth has been greatly enhanced by continuing developments made in endodontic therapy and restorative procedures. In the past, it was thought that posts reinforced endodontically treated teeth; however, recent research has shown the opposite.⁽⁶⁾

Thus, they should fulfill the 3Rs criteria retention, resistance and reinforcement. To achieve optimum results, the material used for the post should have physical properties similar to that of dentin, be bonded to the tooth structure and be biocompatible in the oral environment. It should act as a shock absorber by transmitting only limited stress to the residual tooth structure.⁽⁷⁾

To the best of the author knowledge there are no such case report published in the literature with Fibersite post and core technique.

Fibersite (Megadenta Italia) or anatomical posts reproduce these characteristics in its model and can fulfill the criteria in replacing the cingulum area. They also have an added advantage of its flexural strength similar to the teeth and hence act as a single component during the stress distribution patterns.

Fiber site is an innovative fiber glass pin with preshaped abutment that totally revolutionizes the actual method for the rehabilitation of single rooted

teeth and simplifies partial reconstruction of multi rooted teeth which shorten the core preparation for the tooth. As these posts are anatomical and closely adapt to the tooth structure, they leave a very less space for the luting composite material to flow. Therefore it reduces the susceptibility of polymerization shrinkage of the composite resin as fewer amounts is needed for adhesion. The probability of voids and bubbles are also reduced as a uniform layer of adhesive material is distributed along the surface which is very minimal. This uniformity accounts for distribution of equal forces transfer on the remaining tooth structure.

Conclusion

Reverting the original smile is a boom given to the patient with not only the fine artistic work of the endodontist but also the skill to select the material required. For this to be fulfilled one need not practice so called herodontics but can be emphasized on a novel pre-shaped abutment post. This case report describes the technique of restoration of severely destroyed tooth with a lot of ease, less time achieving functional stability and ultimate patient satisfaction. Such cases can be assured with promising aesthetics of natural teeth rather than planning extraction.

References

1. Grandini S, Sapio S, Simonetti M. Use of anatomic post and core for reconstructing an endodontically treated tooth: a case report. *J Adhes Dent.* 2003;5:243–7.
2. Sonkesriya S, Olekar ST, Saravanan V, Somasunderam P, Chauhan RS, Chaurasia VR. An in vitro comparative evaluation of fracture resistance of custom made, metal, glass fiber reinforced and carbon reinforced posts in endodontically treated teeth. *J Int Oral Health.* 2015;7:53–5.
3. Tortopidis D, Kourtis S, Kountouras K. Restoration of Endodontically Treated Anterior Teeth with Cast Metallic Post or Prefabricated Fibre Post Placement: 2 Case Reports and Critical Literature Review. *Balk J Dent Med.* 2015;19:86–91.
4. Mohammadi N, Kahnamoii MA, Yeganeh PK, & Navimipour EJ. Effect of fiber post and cusp coverage on fracture resistance of endodontically treated maxillary premolars directly restored with composite resin *J Endod.* 2009;35:1428-32.
5. Aarti R, Arun K, Sabarinathan, and Ramesh R. Comparison of Stress Distribution in a Maxillary Central Incisor Restored with Two Prefabricated Post Systems with and without Ferrule Using Finite Element Method. *J Clin Diagn Res.* 2016;10: ZC52–55.
6. Andreasen FM, Nore´n JG, Andreasen JO, Engelhardtson S, Lindh-Stro¨ mberg U. Long term survival of fragment bonding in the treatment of fractured crowns. *Quintessence Int.* 1995;26:669–81.
7. Sharma S, Attokaran G, Singh KS, Jerry JJ, Ahmed N, Mitra N. Comparative evaluation of fracture resistance of glass fiber reinforced, carbon, and quartz post in endodontically treated teeth: An in-vitro study. *J Int Soc Prev Community Dent.* 2016;6:373-6.