

Preparing the master cone to fit the shape of the canal vs. preparing the canal to the shape of an industrial master cone

Zvi Metzger^{1,*}, Anda Kfir²

¹Professor Emeritus, ²Chair of Dept., Dept. of Endodontology, Tel Aviv University, Israel

*Corresponding Author:

Email: metzger.zvi@gmail.com

Abstract

Customized master cones represent a change in concept: rather than instrumenting the root canal to fit the shape of a round, industrial, master cone, a cone is prepared to fit the shape of the ready-to-fill canal. As such, it may be effectively used in round canals of any size and taper, in oval canals or in those with an irregular shape, regardless of which file system was used to shape the canal. In many dental schools, this method has been avoided and not been taught due to a long-outdated ban on the use of chloroform in endodontics. The aim of this paper is to highlight the benefits of customized master cones and to explain in detail a method of their preparation, so every dentist or endodontist can apply it, including those who have never had the opportunity to master this useful procedure during their endodontic studies.

Introduction

Lateral compaction is a method for the obturation of root canals that is most commonly taught and utilized technique worldwide.^(1,2) It is an easy-to-use method that does not require any costly materials or instruments, and it is taught in most dental schools. The basic principle of this method involves selecting a master cone that fits best into the prepared, ready-to-fill root canal. This cone is then used as the main core of the root filling. Sealer is then applied to the canal walls, the master cone is inserted and a spreader is used to laterally compact the root filling by the wedging effect of repeatedly inserting the spreader and adding accessory gutta-percha cones until the canal is full and no additional cones can be inserted.^(3,4)

With the introduction of standardized endodontic instruments, standardized master cones were also made available, with various ISO sizes and a 2% taper.⁽⁵⁾ The concept of selecting a master cone was based on selecting a cone that fits snugly at working length. Snugness of fit is confirmed by slight resistance to withdrawal from the canal, termed “tug-back” sensation. This was done under the assumption that such a cone would fit the shape of the apical part of the root canal.^(1,6)

In recent years, manufacturers of NiTi rotary and reciprocating file systems introduced a new type of master cone that has the size, shape and taper of the last instrument that was used in the canal. Such cones are used under the assumption that they can be used either as a single cone or with very little required lateral compaction.⁽⁷⁻¹⁰⁾ This recent concept may be effective in narrow and round root canals. In such canals, the dentinal walls of the canal are indeed *machined* to a given shape by a rotating tool, which has a metal core and blades. The rotary and reciprocating instruments are commonly called NiTi “files”, but they are actually *machining devices* because they are designed to cut the dentin to their shape and do not use any *fil*ing action.

Both the traditional and the more recent concepts presented above assume that there will be an intimate adaptation of the cone to the shape of the prepared canal, to minimize the amount of sealer in the root canal filling. Conceptually, both methods represent an attempt to *shape the canal so it will fit the shape of a round, industrial master cone*.

Nevertheless, the concept of preparing the canal to the shape of a given round master cone may have limited value for canals with oval cross sections. Oval cross sections exist in 25% of all root canals, and in certain types of teeth, they may appear in 90% of the canals.^(11,12) Such canals present a challenge to all rotating/reciprocating file systems. Nevertheless, they may be properly instrumented by using either hand files or one of the novel endodontic file systems, which were specifically designed to meet the challenge of the 3D shaping and cleaning of oval and irregularly shaped canals. The Self Adjusting File (SAF) System and the XP endo Shaper and Finisher represent this new approach.^(13,14) When using such file systems, many operators are puzzled as to which master cone will fit the canal. This puzzlement probably results from years of using round master cones, a concept which have become irrelevant for such *oval* ready-to-fill canals. The traditional “tug-back sensation” method for selecting a master cone may be grossly misleading in the case of oval canals because it is likely to represent only the smallest mesio-distal diameter of the oval canal. By no means does it represent a true adaptation of the master cone to the canal walls (Fig. 1 A).

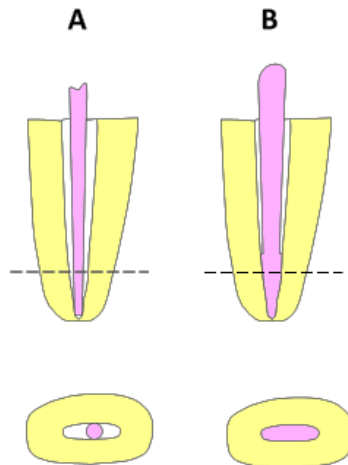


Fig. 1: Adaptation of industrial cones vs. customized cones in oval canals. (A) Industrial, round master cones with a misleading “tug-back” sensation: the cone touches only the mesial and distal walls. (B) A customized master cone adapted to the walls of the apical part of an oval canal

These recent new developments in canal instrumentation call for a change in concept; rather than attempting to prepare the canal for the shape of a given round master cone, a master cone should be prepared to fit the shape of the oval ready-to-fill root canal. This can easily be accomplished by using chloroform-dipped customized master cones.⁽¹⁵⁻¹⁸⁾

Other methods for obturation of oval and irregular shaped canals were introduced, such as filling the canal with a bio-ceramic sealer or the use of thermopasticized gutta percha (see Discussion), but the customized master cone is the simplest and most affordable method.

The method of customized master cones has been used for many years by some dental schools and is mentioned in both text books,^(17,19) and in AAE statement publications,⁽²⁰⁾ as a legitimate and useful obturation method. However, this method is not taught in many other dental schools, and in some, it is not even mentioned or is mistakenly considered negative. It may even be grouped together with obsolete methods such as chloropercha or softened master cones.

The purpose of this paper is to highlight the benefits of this method and to explain, in detail, a method for preparing a customized master cone in a variety of challenging cases and situations, including, but not limited to, oval canals that were prepared with novel instruments that were specifically designed for such canals.

Materials and Method

The principle: Creating a customized master cone may be considered a process of taking an impression of the apical part of the canal on the surface of a master cone. A gutta-percha cone is selected, which stops with a

“tug-back” sensation at 3-5 mm short of the working length. The apical part of the cone is dipped in chloroform for 2 sec and then inserted into the canal with a light apical pressure, which is applied with pecking motions (Fig. 2). The cone should be immediately removed and allowed to dry by evaporation, which takes approximately 15-20 sec,⁽²¹⁾ while the cone is held with locking cotton pliers (Fig. 4 B). The cone should be dipped in chloroform long enough to soften the outer layer of gutta percha but should not be dipped too long to ensure that the inner part of the cone remains solid (Fig. 2).

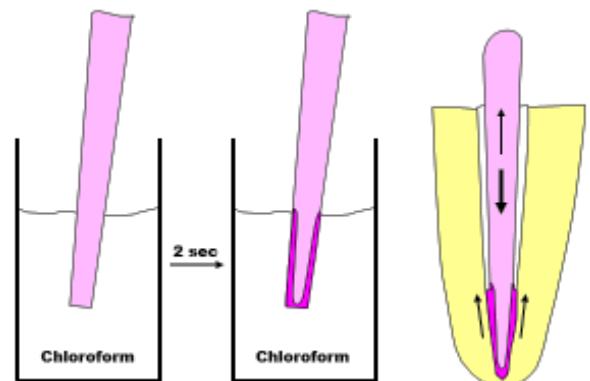


Fig. 2: Preparing a customized master cone. A standardized master cone (.02 taper) is dipped in chloroform for 2 sec and then inserted into the canal with pecking movements. The short exposure to chloroform should soften the outer layer of the cone (purple), leaving the inner part of the cone solid. The softened gutta percha flows coronally to form an imprint of the canal on the cone

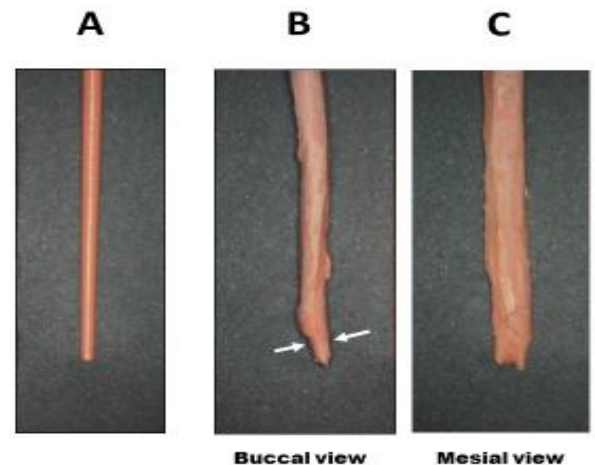


Fig. 3: Two master cones, fitted to the same canal. (A) A standardized master cone that was apparently fitted into the canal, as judged by the tug-back sensation. (B) Buccal view and (C) mesial view of a customized master cone, which was prepared for the same canal. The tug-back sensation of the standardized cone was due to its adaptation to the canal walls in the area marked by arrows

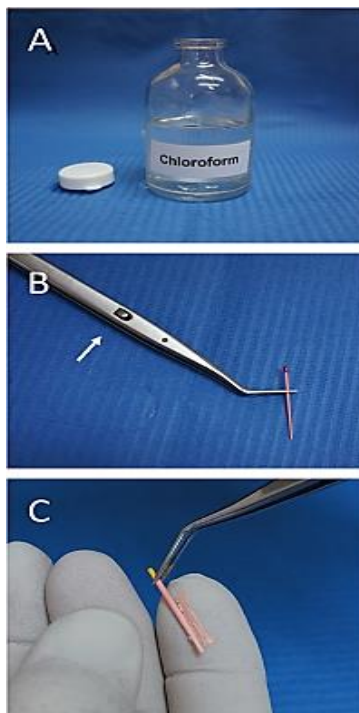


Fig. 4: Technical details. (A) Chloroform container: a small stable *clear glass* bottle, with a small opening (“Penicillin bottle”). (B) Locking cotton pliers holding a master cone. The pliers will allow the cone to re-solidify by evaporation while keeping it in the circular position at which it was formed. Arrow: The locking mechanism. (C) Selecting a master cone brand. The thick cone was dipped in chloroform, and the surface layer is sufficiently soft to smear when touched




Fig. 5: Turning a round master cone into an oval one. The inner part of a pair of surgical scissors (A) is used to compress a standardized, round master cone (B) to generate an oval master cone (C)

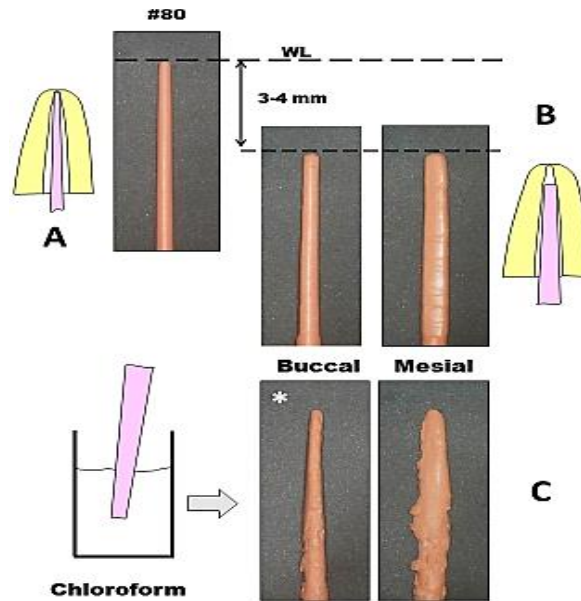


Fig. 6: Standardized vs. customized master cones in an oval canal. A clinical case. (A) Size 80 standardized master cone, which was fitted with a tug-back sensation in the canal at WL. (B) Larger oval master cone, which stopped in the canal at 3-4 mm short of WL. (C) The customized master cone with an imprint of the canal on its surface. Note that when viewed from the buccal direction, the apical part of the customized master cone (*) has similar dimensions to the # 80 master cone. This was the reason for the misleading tug-back sensation with the # 80 master cone

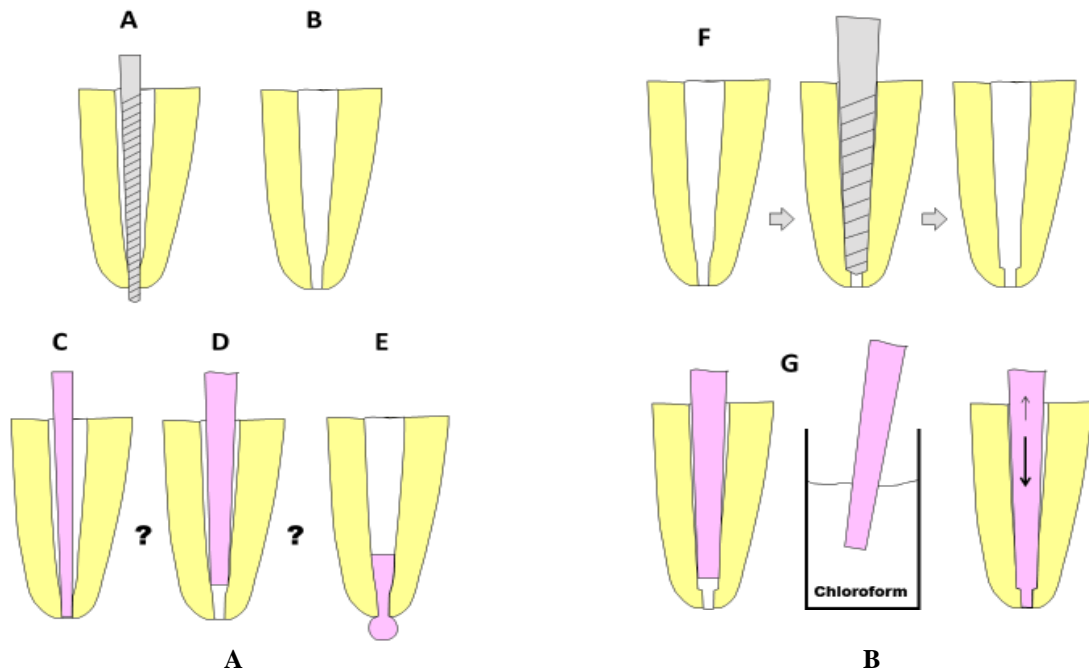


Fig. 7: Master cone for a case of accidental over-instrumentation. (A) Accidental over-instrumentation, resulting in a loss of apical constriction (B). Potential solutions: (C) Master cone adapted to WL with a tug-back sensation: it may slide beyond the apex during lateral compaction. (D) Thick master cone, short of WL: will result in having only sealer in the apical part of the root filling. (E) Warm gutta-percha obturation: may result in a blob of gutta percha in the periapical area. (F) Creation of an artificial positive stop for the master cone, by enlarging the canal by two instrument sizes, 1 mm short of WL. (G) Forming a customized master cone that will fit to WL and yet will have a positive seat, preventing it from sliding through the apical opening

When inserting the cone into the canal, the outer softened layer of gutta percha will flow coronally, thus allowing the cone to reach working length and resulting in a cone with an imprint of the canal on its apical part. The cone will then be allowed to dry and harden to be used as a solid master cone, with an apical part that has been shaped to fit this particular canal (Fig. 3).

Applying too much apical pressure, when taking the impression with the cone, may result in bending of the cone; such cones should be discarded. Leaving the cone in the canal for too long may cause the inner solid core to soften, and the cone may thus, be distorted by elongation when pulled out. Once again, such a cone should be discarded.

The canal should not have free liquid in it when creating a customized master cone, because such liquid may be pushed through the apical foramen due to a piston effect. Nevertheless, the canal walls should be slightly moist, because very dry dentin walls may allow the gutta percha to stick to the dentin, particularly in narrow canals.

It should be considered that a customized cone is frequently not round (as opposed to industrial cones) and may thus enter the canal to its working length only in a given circular direction but not when randomly rotated. Consequently, the cone should be held with locking cotton pliers (Fig. 4) to indicate its direction in relation to a selected reference point.

When removed from the canal, the cone length should be measured in relation to the reference point that was initially used to determine the working length. If the cone reaches the working length, it will be suitable for use once it dries. If the cone fails to reach the working length, the procedure may be repeated once with the same cone. It may not be possible to repeat the procedure more than once with the same cone because the inner solid core will then be softened, which may make it impossible to take an imprint. A new cone should be used if the first cone was already used twice in attempt to produce an adequate customized master cone.

When preparing customized master cones for a multi-rooted tooth, it will be most convenient to have several locking cotton pliers, with one for each canal. The alternative is to prepare the cone and obturate each canal separately, which can be done by re-using the same single locking cotton pliers.

Selecting a suitable gutta-percha brand: Not all gutta-percha brands are suitable for creating customized master cones. One needs a cone that is made from gutta percha that has high solubility in chloroform. The solubility may be easily tested by dipping a thick master cone of a given brand in chloroform for 2 seconds and touching it with one's fingers. The surface of the cone should be softened to the extent that it is slightly smeared on the fingers. (Figure 4 C). One brand that may be used for customized master cones is Sure-endo (Gyeonggi-do, Korea); any other brand that

responds to a short dipping in chloroform, as described above, may also be used.

Standardized gutta-percha master cones with a .02 taper are the most useful raw materials for preparing customized master cones. Larger taper gutta-percha cones will not be suitable for this purpose because there will be no space for the softened outer layer of gutta percha to move coronally.

Oval canals and oval master cones: When preparing a customized master cone for a large oval canal, it may be easier if the initial gutta-percha cone is oval. Such cones are not commercially available but can easily be produced by the operator by mechanically pressing a round cone with the inner part of a pair of surgical scissors or a similar tool (Fig. 6). This oval cone should also be sufficiently thick to stop in the large oval canal, at 3-4 mm short of the working length of the canal, before customization (Fig. 7).

Selecting the solvent: Chloroform is the solvent of choice for this procedure. The solvent should be effective at rapidly dissolving gutta percha, but should also *evaporate quickly* to allow the re-solidification of the customized master cone.⁽²¹⁾ Other gutta-percha solvents, such as xylene, eucalyptol, orange terpenes or rectified turpentine, are not suitable for the creation of customized master cones, because their evaporation is slow and the cone will remain soft within the clinically relevant time of 1-2 min.

Chloroform hygiene: Chloroform is a toxic material and should be handled with care to minimize the presence of its vapors in the clinic. The chloroform may be contained in either a small and stable clear glass bottle with a narrow opening (Fig. 4 A) or in a glass syringe with an opening large enough to allow the insertion of a master cone.⁽²²⁾ The practice of pouring of some chloroform into a glass Dappen dish should be avoided for two reasons: (a) the Dappen dish provides a maximal surface for evaporation of the solvent, and (b) the chloroform is usually discarded into the sink, thereby distributing the chloroform vapors to all other sinks in the clinic/building. When used carefully, chloroform is considered safe for both the patient and the operatory team (see below).⁽²³⁻²⁵⁾

Customized master cones as teaching tools: Customized master cones may also serve as excellent teaching tools. There is no other way for a teacher of endodontics to show a dental student the actual 3D shape of the apical part of the canal that the student just finished instrumenting. Naturally, one cannot use microCT for such a demonstration. An imprint of the canal is, in this case, the only easy-to-obtain tool that will allow a student to understand the shape of the canal that he just created with his files.

Customized master cones in cases of over-instrumentation: Cases of accidental over-instrumentation may present challenges when attempting to obturate the root canal. In such cases, the apical constriction has been often ruined, and when

attempting to obturate the canal by lateral compaction, the master cone may be pushed by the spreader and slide through the apical end of the preparation (Fig. 8 A, B). Customized master cones may thus present a simple and reproducible solution to this problem. First, an artificial positive stop should be created. The actual length of the canal should be determined by using an electronic apex locator and a radiograph. Hand files, in one and two sizes larger than the file that passed the apex, should be used to a new working length that is 1 mm shorter than the present canal length, thus forming a circular ledge that will serve as a positive seat for the master cone (Fig. 8 F).

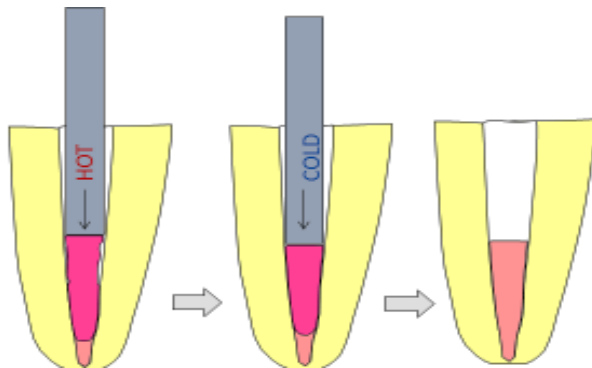


Fig. 8: Customized master cone combined with a warm compaction method. A customized master cone is first prepared to fit in the apical part of the canal, then warm compaction is applied. The chance of pushing softened gutta percha beyond the apex is greatly reduced




Fig. 9: Two common clinical cases of round canals.

In both A and B, a #45 standardized master cone was fitted to the WL with a tug-back sensation. The customized master cones in both cases present a better fit in these round canals

A customized master cone may then be prepared, as discussed above, which will carry an imprint of this ledge with a protruding part that will adequately fill the space of the apical end of the canal (Fig. 8 G). Such a master cone will have a positive seat and will thus have little chance of sliding through the apical foramen during lateral compaction.

Cases of a large apical foramen size caused by apical resorption and cases of accidental perforation may also be handled by using the same principle: forming a ledge that will serve as a positive seat for the customized master cone.

Customized master cones and warm gutta-percha obturation: When using warm gutta-percha obturation, roots with a large apical foramen may present a problem. Such a large apical opening may be either natural or created by apical resorption associated with long-standing apical periodontitis.⁽¹²⁾ In such cases, the heat-softened gutta percha may be pushed through the apical foramen and form a blub of gutta percha in the periapical area (unless an MTA plug is used). Preparing a customized master cone, with or without a ledge, may produce an apical stop that will provide good adaptation to the walls of the canal in the apical area, while allowing the operator to use the warm gutta-percha method in the more coronal parts of the canal (Fig. 8).

Customized master cones in round canals: The use of customized master cones is not limited to the cases described above. The shape of the apical part of the round canal often differs from that of the instruments that created it. This may be the case in canals instrumented by the step-back method but often also occurs in canals that are instrumented with rotary or reciprocating files. A routine use of customized master cones may often result in the condition illustrated in Fig. 9: A master cone that apparently fits the apical part of the canal, as judged by the tug-back sensation, is far from adapting to the canal walls in the apical 2 to 4 mm. The customized master cones, which are presented in Fig. 10, show this clearly.

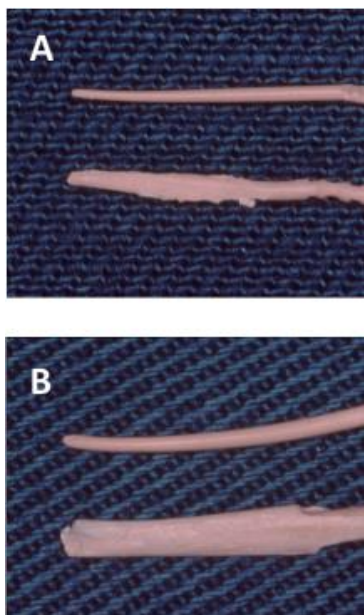


Fig. 10: Common and extreme cases. The two master cones were fitted in the same canal: the standardized round master cone was fitted with a tug-back sensation. The customized master cone reveals the real 3D shape of the canal. (A) Common case from a distal root of a mandibular first molar. (B) An extreme case from a second maxillary bicuspid

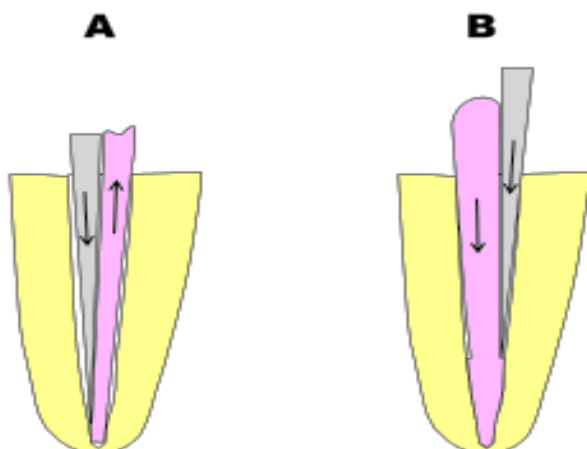


Fig. 11: Lateral compaction in a large canal. (A) The spreader may dislodge the master cone, during lateral compaction, by its wedging effect. (B) With a customized master cone, the pressure of the spreader will only seat the master cone better in the root canal

Discussion

The concept of customized master cones is not new.⁽¹⁵⁾ The method is taught in some dental schools and is an accepted obturation method, as expressed in leading textbooks,^(17,19) and in AAE consensus publication "Colleagues for Excellence".⁽²⁰⁾ Nevertheless, it is either not taught or not practiced in many other dental schools worldwide, mainly and most

likely, due to an outdated concern about the use of chloroform in endodontics.

This concern originated from a statement of the Food and Drug Administration (FDA), regarding the use of chloroform. The FDA published in 1976 a ban related to the use of chloroform.⁽²⁷⁾ Careful look at this ban reveals that the ban was limited to the use of chloroform as an **active ingredient** in cosmetics, cough medicine preparations or tooth pastes, products that are daily applied to the skin or oral mucosa or taken internally. Within the same document, one can find that small residual amounts of chloroform resulting from manufacturing processes were allowed even in cosmetics and these other products. Similar publication was also repeated in 2014.⁽²⁸⁾ The FDA ban never addressed and was not related to the use of chloroform in dentistry or endodontics.

Mattison et al⁽²⁹⁾ took the liberty of stating, that "In view of the FDA's ban on the use of chloroform from Accepted Dental Therapeutics, the continued use of this solvent cannot be justified".⁽²⁹⁾ Such statement was wrong and misleading, as the American Dental Association Council on Dental Therapeutics never published such statement, and in any case, the FDA has no jurisdiction in this matter.⁽²⁴⁾ Nevertheless, publications such as this led to a negative approach towards the use of chloroform in Endodontics, which lasted for almost two decades and filtered even into leading endodontic textbooks such as *Pathways of the Pulp*.⁽³⁰⁾

Since that time, several studies were done and published to clarify this issue,^(23,24,31) with the most important one being the one by McDonald and Vire 1992.⁽²⁴⁾ Consequently, chloroform made its way back into mainstream Endodontics. Current knowledge and status of chloroform use in Endodontics is clearly expressed in the 9th edition of *Pathways of the Pulp*.⁽¹⁷⁾ "The most popular solvent is chloroform, because it dissolves gutta percha rapidly and has a long history of clinical use" and "With careful use, chloroform's cytotoxicity may be eliminated as a risk factor to both patient and the personnel in the operatory. As such, *its continued use as a gutta percha solvent is recommended*".⁽¹⁷⁾

Similarly, another mainstream textbook, "*Principle and practice of endodontics*"⁽¹⁹⁾ also stated that "Chloroform is the most effective solvent",⁽¹⁹⁾ and that "It is safe for use in dentistry, however in high concentrations its vapor is potentially hazardous. Therefore, chloroform is dripped directly into the canal orifice" (in retreatment).⁽¹⁹⁾

It should be noted that all of the persons involved in the more recent Chapters/Statements cited above, as either chapter authors or textbook editors, belong to the first line of professional leaders of the endodontic community. In conclusion, chloroform is no longer banned in endodontics; thus, using the customized master cone is an acceptable method.

The attempts to instrument root canals to the shape of an industrial round master cone may be effective in small, straight canals, which are machined by the rotating file to assume the file's shape. Nevertheless, in large canals, such machining with large-size and large-taper files may risk the long-term integrity of the root^(32,33) and is increasingly avoided. Furthermore, recent years are marked with a better understanding that the 3D cleaning and shaping of oval canals or of those canals with recesses or isthmuses are not possible by using rotating files alone.

The Self-Adjusting File (SAF) and the XP endo Shaper and XP endo Finisher files represent the current leading front of a new concept of endodontic instrumentation aimed at the *minimally invasive* 3D cleaning and shaping of root canals. Similar instruments from other manufacturers are likely to follow soon. Such files do not machine the canal to a given shape but rather respect the anatomical shape of the canal and clean and shape it while *preserving as much of the sound dentin* as possible.^(13,14)

The canals prepared by such files are often not round because the original shape of the canal is greatly preserved. For an operator who uses lateral compaction, this may raise a challenge: how should a master cone be fitted / selected?

Recently, Bio-ceramic sealers were proposed as a way to overcome the above mentioned challenge.^(34,35) Nevertheless, this method is encountered with hesitation due to two aspects. First, these sealers are reported to expand upon setting, raising the issue of potentially creating cracks in the root dentin, and second, such a root filling is likely to be rather difficult to remove in case that retreatment is needed.⁽³⁶⁻³⁸⁾ The high cost of some of these new sealers may also be an issue in certain countries.

Another alternative approach in oval canals could be the use of thermos-plasticized gutta percha. However, this method also involves selecting a master cone and thus can also benefit from the customization of the initial master cone, as presented in Fig. 7E and 8.

The most popular thermos-plasticized methods include a "backfill" stage, which requires additional special equipment and special gutta percha. The backfill stage may also compromise the obturation due to shrinking of the liquefied gutta percha. Both last issues can easily be avoided by the use of customized master cones.

The customized master cone represents the best, fast, easy and most affordable solution for such canals. Furthermore, creating a customized master cone is a convenient and useful method for overcoming other challenging situations, such as oval canals that were instrumented with hand files and large canals in which "machining" with large rotary or reciprocating files should be avoided for long term safety of the root. This method is also particularly useful for canals with large apical foramen sizes, which can result from either

apical resorption or accidental over-instrumentation. In such canals it may be difficult to control and avoid apical extrusion of gutta percha if/when thermo-plasticised gutta percha methods are used alone (Fig. 7 E).

Additionally, when using this method for every case, regardless of which file was used for canal instrumentation, one soon realizes that the shape of the apical part of a canal prepared with either rotating files or by manual instrumentation is often very different from the shape that the operator imagined and expected (Figs 9, 10). As such, customized master cones may be considered an easy and affordable clinically-relevant substitute for micro-CT observation of the shape of the prepared root canal, the last, naturally, is not applicable in the clinic.

Preparing a customized master cone may be apparently considered a time-consuming procedure. However, overall, this is not really the case, because the time required for lateral compaction of the canal is often greatly shortened when customized master cones are used. The volume of the canal is already partly filled by the thick "shaft" of the master cone (Fig. 1B), thus greatly reducing the number of accessory cones required to adequately fill the canal.

Two problems that may occur during lateral compaction may also be avoided by using customized master cones. The first is dislodging an industrial master cone coronally, during compaction, by the wedging effect of the spreader (Fig. 11 A). This is unlikely to occur with a customized master cone because each insertion of the spreader tends to seat the cone better in place (Fig. 11 B).

The second problem is the master cone sliding through the apical foramen and into the periapical tissues. Such an accident often occurs when the apical foramen is oval and when the tug-back sensation misled the operator to believe that his selected industrial master cone had a positive seat, while it really touched only a limited area in the smallest mesio-distal diameter of the oval canal (Fig. 1 A). This is unlikely to occur in the case of a customized master cone because it has a circumferential positive seat that will hold it in the canal and prevent such an accident.

It should be kept in mind that when inserting a customized master cone into a canal that contains sealer, one should do it slowly and with care. The circumferential adaptation of a customized master cone may slow the backflow of excess of sealer (as compared to a .02 taper cone) and may push sealer through the apical foramen. This can be easily avoided by inserting the master cone slowly.

The purpose of the present paper is to make the method of customized master cones more fully understood and easy to perform by any dentist or endodontist, even if his school has avoided teaching this method due to a long-outdated concern about chloroform. It also aims to give the operator a unique

opportunity to become acquainted with the real 3D shape of his just now prepared ready-to fill canals.

References

- Whitworth J. Methods of filling root canals: principles and practices. *Endod Topics* 2005;2: 2–24.
- Bjorndal L, Reit C. The adoption of new endodontic technology amongst Danish general dental practitioners. *Int Endod J* 2005;38:52–58.
- Schäfer E, Olthoff G. Effect of three different sealers on the sealing ability of both thermafil obturators and cold laterally compacted gutta-percha. *J Endod* 2002;28:638–642.
- Chandler NP. Root canal filling. *In: Chong BS, editor. Harty's endodontics in clinical practice.* 6th ed. Edinburgh: Elsevier, 2010:131–157.
- Bal AS, Hicks ML, Barnett F. Comparison of laterally condensed .06 and .02 tapered gutta-percha and sealer *In vitro*. *J Endod* 2001;12:786–788.
- Gutmann J, Witherspoon D. Obturation of the cleaned and shaped root canal system. *In: Pathways of the Pulp,* 7th ed. Cohen and Burns Eds. St Louis, 2002: 293–364.
- Gordon MPJ, Love RM, Chandler NP. An evaluation of .06 tapered gutta-percha cones for filling of .06 taper prepared curved root canals. *Int Endod J* 2005;38:87–96.
- Hörsted-Bindslev P, Andersen MA, Jensen MF, Nilsson JH, Wenzel A. Quality of molar root canal fillings performed with the lateral compaction and the single-cone technique. *J Endod* 2007;33:468–471.
- Marciano MA, Ordinola-Zapata R, Cunha TV, Duarte MA, Cavenago BC, Garcia RB, Bramante CM, Bernardineli N, Moraes IG. Analysis of four gutta-percha techniques used to fill mesial root canals of mandibular molars. *Int Endod J* 2011;44:321–329.
- Schäfer E, Nelius B, Bürklein S. A comparative evaluation of gutta-percha filled areas in curved root canals obturated with different techniques. *Clin Oral Invest* 2012;16:225–230.
- Wu MK, Roris A, Barkis D, Wesselink PR. Prevalence and extent of long oval canals in the apical third. *Oral Surg Oral Med Oral Pathol Oral Radiol Endod* 2000;89:739–743.
- Marroquín BB, El-Sayed MA, Willershausen-Zönnchen B. Morphology of the physiological foramen: I. Maxillary and mandibular molars. *J Endod* 2004; 30: 321–8.
- Metzger z. The self-adjusting file (SAF) system: An evidence-based update. *J Conserv Dent* 2014;17:401–19.
- XP-3D Product Brochure - Brasseler USA 2017. brasselerusadental.com/wp-content/uploads/sites/9/.../B_4744_XP3D-Brochure.pdf.
- Weine FS. *Endodontic Therapy* (2nd Ed), St Louis, Missouri, Mosby, 1976.
- Metzger Z, Nissan R, Tagger M, Tamse A. Apical seal of customized and standardized master cones compared in flat and round canals *in vitro*. *J Endod* 1988;14:381–384.
- Cohen S, Hargreaves KM (Eds). *Pathways of the Pulp,* 9th Ed. St. Louis: Mosby-Elsevier, pp. 968.
- van Zyl SP, Gulabivala K, Ng Y-L. Effect of customization of master gutta-percha cone on apical control of root filling using different techniques: an *ex vivo* study. *Int Endod J* 2005;38:658–666.
- Walton RE, Torabinejad M (Eds). *Principles and Practice of Endodontics,* 3rd ed. Saunders-Elsevier, Philadelphia, pp 357.
- American Association of Endodontists. *Colleagues for Excellence: Obturation of root canal systems.* Chicago, Fall 2009.
- Metzger Z, Assif O, Tamse A. Residual chloroform and plasticity in customized master cones. *J Endod* 1988;14:546–549.
- Donnelly JC. Using a 1-ml syringe for the chloroform diproot canal filling technique. *J Endod* 1993;19:478.
- Margelos J, Verdellis K, Eliades G. Chloroform uptake by gutta-percha and assessment of its concentration in air during the chloroform-dip technique. *J Endod* 1996;22:547–550.
- McDonald MN, Vire DE. Chloroform in the endodontic operator. *J Endod* 1992; 18:301–303.
- Chutich MJ, Kaminski EJ, Miller DA, Lautenschlager EP. Risk assessment of the toxicity of solvents of gutta-percha used in endodontic retreatment. *J Endod* 1998;24:213–216.
- Kerezoudis NP, Valavanis D, Prountzos F. A method of adapting gutta-percha master cones for obturation of open apex cases using heat. *Int Endod J.* 1999;32:53–60.
- United States Drug Administration. Chloroform used as an ingredient (active or inactive) in drug products. Federal Register No. 26845. Washington DC: US Government Printing Office, 1976.
- United States Food and Drug Administration. Prohibited and restricted ingredients. <http://www.fda.gov/Cosmetics/GuidanceRegulation/LawsRegulations/ucm127406.htm>, 2014.
- Mattison GD, Delivanis PD, Thacker RW, Hassel KJ. Effect of post preparation on the apical seal. *J Prost Dent* 1984;51:785–9.
- Cohen S, Burns RS (Eds). *Pathways of the Pulp,* 5th Ed. Mosby, St. Louis, Missouri, 1991.
- Allard U, Andersson L. Exposure of dental personnel to chloroform in root-filling procedures: *Endod Dent Traumatol.*
- Sathorn C, Palamara JE, Palamara D, Messer HH. Effect of root canal size and external root surface morphology on fracture susceptibility and pattern: a finite element analysis. *J Endod.* 2005;31:288–292.
- Tavanafar S, Karimpour A, Karimpour H, Saleh AM, Saeed MH. Effect of different instrumentation techniques on vertical root fracture resistance of endodontically treated teeth. *J Dent* 2015;16: (Suppl.1) 50–55.
- Celikten B, Uzuntas CF, Orhan AI, Orhan K, Tufenkci P, Kursun S, Demiralp KÖ. Evaluation of root canal sealer filling quality using a single-cone technique in oval shaped canals: An *In vitro* Micro-CT study. *Scanning.* 2016;38:133–40.
- Pawar A, Pawar S, Kfir A, Pawar M, Kokate S. Push-out bond strength of root fillings made with C-Point and BC Sealer vs. gutta percha and AH Plus after the instrumentation of oval canals with the Self-Adjusting File vs. Waveone. *Int Endod J.* 2016;49:374–81.
- AL-Haddad A, Che-Ab-Aziz ZA. Bioceramic-Based Root Canal Sealers: A Review. *Int J Biomater.* 2016;2016:9753210. doi:10.1155/2016/975321037.
- Cherng AM, Chow LC, Takagi S. *In vitro* evaluation of a calcium phosphate cement root canal filler/sealer. *J Endod.* 2001;27:613–15.
- Hess D, Solomon E, Spears R, He J. Retreatability of a bioceramic root canal sealing material. *J Endod.* 2011;37:1547–49.