

## Removal of broken endodontic instrument using Ultrasonic's and Magnifying loupes – A case report

Aditi Jain<sup>1,\*</sup>, Pratik Surana<sup>2</sup>, Jayesh Tiwari<sup>3</sup>, Neha Saini<sup>4</sup>

<sup>1</sup>Senior Lecturer, <sup>2,3</sup>PG Student, <sup>1,4</sup>Dept. of Conservative Dentistry & Endodontics, <sup>2,3</sup>Dept. of Pedodontics, <sup>1</sup>Ayush University & Health Sciences, Raipur, <sup>2,3</sup>Maitri Dental College and Research Institute, Chattisgarh, <sup>4</sup>Rungta Dental College, Bhilai, Chattisgarh

**\*Corresponding Author:**

Email: aditijain300789@gmail.com

### Abstract

Separation of endodontic instrument in the middle third of the root canal hinders accessibility to the apical terminus thus compromising cleaning & shaping procedure, which ultimately have a potential impact on the outcome of the success of treatment. The prognosis of such cases mainly depends on the periapical status preoperatively. Today separated instruments can easily be retrieved because of technological advancement such as retreatment rotary files are available, by ultrasonic instrumentation and microtube delivery method & many more. This case report highlights the removal of broken instrument from middle third of the root canal using ultrasonic's and magnifying loupes.

**Keywords:** Separated instrument, Ultrasonic, Prognosis, Challenging.

### Introduction

It has been rightly said, that the only thing that remains constant in this world is change. Since the advent of time and particularly since the dawn of 20<sup>th</sup> century, man has been faced with the opportunity to change and improve upon the pre existing ideas and inventions in order to progress and evolve. The field of endodontics has not been exempted from this challenge, and this is best reflected by the evolution seen in NiTi rotary instruments used in endodontics for root canal preparations. NiTi rotary instruments showed a higher incidence of instrument separation and that hinder cleaning and shaping procedure which will ultimately affects the long term prognosis of endodontic treatment negatively.<sup>(1)</sup>

When an instrument separation occurs during cleaning & shaping procedures, the clinician has to evaluate the treatment options with consideration for the pulp status, the root canal infection, the root canal anatomy, the position and type of fractured instrument and the amount of damage that would be caused to the remaining tooth structure.<sup>(2)</sup> Success of nonsurgical fractured instrument removal from root canals depends on the canal anatomy, the location of the fragment in the canal, the length of the separated fragment, the diameter and curvature of the canal itself, and the impaction of the instrument fragment into the canal wall.<sup>(3)</sup> Removal of the separated instrument, bypassing and sealing the fragment within the root canal or true blockage are chosen approaches.

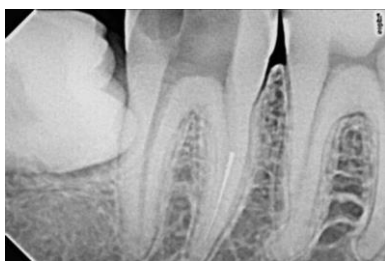Files mostly frequently break in the apical 3 to 5mm because this is the region where a canal usually exhibits its greatest degree of curvature.<sup>(4)</sup> Piezoelectric ultrasonic technology is used which should provide a broad range of power, precise adjustment within the

lower settings and electrical feedback to regulate amplitude and safe tip movement.<sup>(5)</sup>

Ultrasonic instrument should have contra angled design to provide access and parallel side's walls to create a straight line and zirconium nitride coating to precisely sand away dentin during trephine procedure. The tip of ultrasonic instrument is kept in intimate contact against the typically activated with the lower power setting. All ultrasonic work below the orifice is conducted. Dry to enhance vision, a stropko three way adapter with an appropriate tip to direct continuous strain of air to blow out dentinal dust is used. The selected ultrasonic instrument is moved lightly in a CCW direction, except when removing a file that has left handed thread in that case direction will be CW. Gently wedging the energized tip between the tapered file and canal wall often times causes instrument to jump out of the canal.<sup>(6)</sup> If the instrument lies deep that long length and small diameter ultrasonic instrument are used. On occasion, after creating an excellent coronal and radicular access, performing the excellent ultrasonic trephining, the instrument does not come out of the canal.<sup>(7)</sup> Further it may be unsafe to continue trephining around a broken instrument because of lack of anatomical restriction. In these cases the instrument has to be bypass. To maximize efficiency and success the handles from SS file is removed and SS file is then inserted into dense called file. File adapter threads into ultrasonic hand piece. This technique is of useful when root is thin or a portion of file apical to canal curvature.<sup>(8)</sup> This case report represents the removal of fractured instrument at the junction of coronal and middle third of the canal of a permanent mandibular second molar.

### Case Report

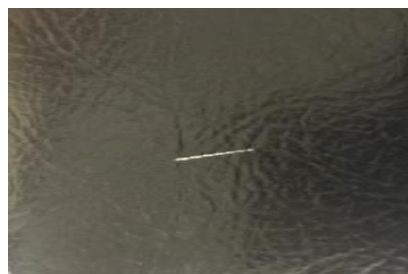A 36 year male patient reported to the department of conservative dentistry and endodontics with chief complaint of pain in lower right back region of jaw since 10 days. Patient had started root canal treatment 3 weeks prior at a local dentist. Medical history was non contributory. Intraoral examination revealed incomplete caries removal and incomplete access cavity preparation with mandibular molar. Tenderness on percussion and palpation was positive. Radiograph suggested that separated instrument file in the middle third of the root canal and periapical radiolucency in the distal root (Fig. 1). The case was diagnosed as an incomplete root canal treatment with apical periodontitis in relation to mandibular molar.



**Fig. 1: Preoperative Radiograph showing separated instrument in the middle third of mesiobuccal canal of right mandibular second molar**

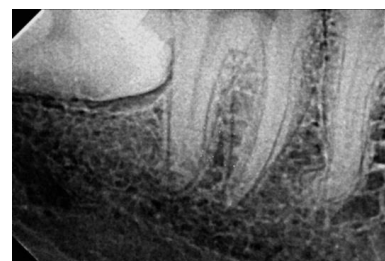In the first appointment, Patient's informed consent was obtained. Under local anesthesia and optra dam isolation, caries were removed and access cavity was modified and canal orifices were located using DG16 explorer & a straight line access was created by Gates Glidden drills. Obstruction to canal was felt when k file No. 15 was introduced into the.... canal but with the help of magnifying loupes exact location of the coronal end of the separated instrument could be appreciated in the canal. After that No. 10 K file was inserted passively and advanced only 1mm at a time with copious amount of irrigant (5.25% NaOCL) and after a given insertion if K file comes out of the canal bent or deformed it was discarded.

Ultrasonic tips (Pro Ultra ENDO Tips, DENTSPLY Tulsa Dental, Tulsa, Oklahoma) were used around the fragment to expose it, and then ultrasonic activation with ultrasonic tips were applied to remove the fragment that makes the fragment loosen now the fractured fragment was removed using H file which was approximately 3mm in length (Fig. 2 & 3). The patency of the canal was checked using magnifying loupes. Multiple radiographs in different angulations were taken; working length was determined using electronic apex locator. Cleaning and shaping was done using WaveOne Gold. Irrigation was performed with 3% sodium hypochlorite solution. Calcium hydroxide paste was used as an intra-canal medicament.

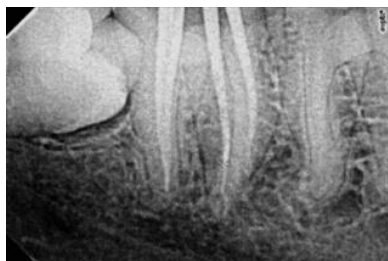


**Fig. 2: Magnifying loupes and ultrasonic's which were used and Clinical image of the retrieved broken instrument**

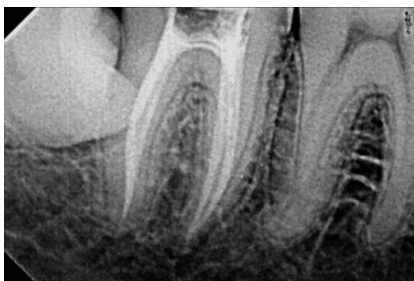In second appointment, Calcium hydroxide paste was removed using normal saline & Canals were then irrigated with 17% aqueous EDTA solution as a final flush. Root canals were obturated with gutta-percha and AH Plus sealer using warm vertical compaction technique (Fig. 4 & 5). The tooth was subsequently restored. Follow up was done for 6 months and the patient was found to be clinically asymptomatic (Fig. 6).



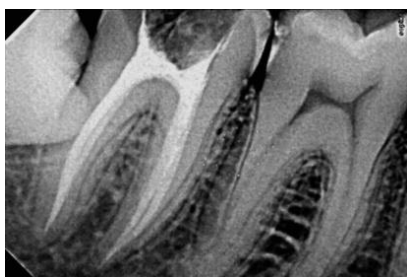
**Fig. 3: Intra Oral periapical radiograph showing retrieval of separated instrument**



**Fig. 4: Intra Oral periapical radiograph showing Master cone**



**Fig. 5: Intra Oral periapical radiograph showing Obturation**



**Fig. 6: Follow-up Intra Oral periapical radiograph after 6 months of treatment**

## Discussion

Factors influencing separated instrument removal are: depends on diameter, length and position of the fragment within the canal, Depends on the including, diameter, length and curvature of the canal anatomy, depends on the root morphology, including the circumferential diameter and thickness of remaining dentin and depth of an external concavity. If the 1/3<sup>rd</sup> of the overall length of the file is exposed it can usually be removed. Stressed instrument is most likely to separate in the canal; recognized by flutes appear unwound; when the spacing appears uneven between cutting edges. Instruments No. 8 & 10 should be used only once; should not be forced or wedged inside the canal.

Depends on the site where the instrument has broken, i.e. instrument that lies in the straightway portion can be removed easily, separated instrument that lie partially around the canal although more difficult. If the broken instrument segment is apical to the curvature of the canal and safe access cannot be established, the removal is not possible and in presence of signs and symptoms, surgery or an extraction is an option.

Stainless steel files tend to be easier to remove they do not fracture during the removal process. NiTi instrument may break again during the ultrasonic removal. Knowledge, training and competency are perhaps the most important central factor for the successful instrument removal. YaShen et al reported that the curvature of tooth affects the removal of the separated instrument.<sup>(9)</sup> The success rate for removal of fractured instrument was found the lowest in the apical third and it is easy to remove from the coronal third by Hulsmann et al.<sup>(10)</sup> Souter et al showed lower success rate in removing instrument from apical third in curved canals.<sup>(11)</sup>

Fors and Berg concluded that separated instruments in the apical third should be left in situ because attempts to remove may result in perforation thus declining the prognosis of the endodontic treatment.<sup>(12)</sup> If fragment cannot be bypassed, canal can be prepared & filled to the level to which instrumentation can be accomplished. As long as the instrument fragment is not protruding through the apex, apical surgery is not needed. Removal of separated fragment should not weaken the remaining tooth structure.

## Conclusion

Location of the fragment and the anatomy of the root canal influence the success of fractured instrument management. Curved canals are a higher risk for instrument fracture than straight canals. Ultrasonic's and Magnifying Loupes is an effective removal method.

## References

1. Sjögren U, Hagglund B, Sundqvist G, Wing K. Factors affecting the long-term results of endodontic treatment. *J Endod.* 1990; 16:498-504.
2. Plotino G, Pameijer CH, Grande NM, Somma F. Ultrasonics in endodontics: A review of the literature *J Endod* 2007;33:81-95.
3. Nagai O, Tani N, Kayaba Y et al Ultrasonic removal of broken instruments in root canals. *Int Endod J* 1986, 19, 298-30.
4. FU M, Zhang Z, Removal of broken files from root canals using ultrasonic techniques combined with dental microscope a retrospective analysis of treatment outcome. *J Endod* 2011, 37(5), 619-622.
5. Shahabinejad H, Ghassemmi. A success of ultrasonic technique in removing fractured rotary nickel- titanium endodontic instruments from root canals and its effect on the required force for root fracture. *J Endod* 2013; 39(6);824-828.
6. Madrati A, Alison J Efficiency of a newly designed ultrasonic unit and tips in reducing temperature rise on root surface during the removal of fractured files. *J Endod* 2009;39(5), 432-436.
7. Ward JR, Parashos P, Messer HH. Evaluation of an ultrasonic technique to remove fractured rotary nickeltitanium endodontic instruments from root canals: Clinical cases. *J Endod.* 2003;29:764-767.
8. YaShen Peng B, Cheung GS. Factors associated with the removal of fractured instruments from root canal systems. *Oral Surg Oral Med Oral Pathol Oral Radiol Endod.* 2004;98:605-610.

9. Hulsmann M. Removal of fractured instruments using a combined automated/ultrasonic technique. *J Endod.* 1994;20:144–147.
10. Ward JR, Parashos P, Messer HH. Evaluation of an ultrasonic technique to remove fractured rotary nickeltitanium endodontic instruments from root canals: an experimental study. *J Endod.* 2003;29:756–763.
11. Souter N, Messer H. Complications associated with fractured file removal using an ultrasonic technique. *J Endod* 2005, 31(6), 450-452.