

Tooth resurrection: Life after death

Akanksha Jain^{1*}, Vineeta Nikhil², Preeti Mishra³, Karan Bansal⁴, Abhinav Jain⁵

^{1,3,4}Senior Lecturer, ²Professor and HOD, ⁵Private Practitioner, ¹Dept. of Conservative and Endodontics, Maharishi Markandeshwar University, ¹Mullana, Ambala, Haryana, ^{2,3}Subharti Dental College, Meerut, Uttar Pradesh, ⁴Adesh Institute of Dental Sciences and Research, Bathinda, Punjab, India

***Corresponding Author: Akanksha Jain**

Email: drakankshajainendo@gmail.com

Abstract

Tissue engineering is an emerging domain. Very soon it will be possible to produce a complete vital tooth from a single stem cell. Pulp revascularization is based on the ability of residual pulp and apical and periodontal stem cells to differentiate. These cells are highly potent to create a highly vascularized and a vital conjunctive tissue, which can colonize the available pulp space. This technique is specifically indicated for teeth with incomplete root formation as a substitute for the traditional treatment of apexification, which consists of placing calcium hydroxide paste into the root canal for a stipulated period of time in order to trigger the formation of a calcified barrier. Therefore, there has been an indefinite search for alternatives which allow the full development of immature teeth. Revascularization is a recent treatment module for immature necrotic permanent teeth.

Keywords: Tissue engineering, Stem cell, Pulp revascularization, Apexification, Immature teeth.

Introduction

In young children, anterior teeth by virtue of their position in the dental arch are more prone to dental trauma. In cases of complicated tooth fracture, the loss of root development with an open apex is a serious sequel. The traditional treatment protocols were surgery, retrograde sealing, and apical barrier formation with different materials and gutta-percha obturation technique.¹ Apexification procedures with calcium hydroxide, Mineral trioxide aggregate used to provide an artificial barrier had their own limitations of long term therapy for barrier formation, non reinforcement of root canal dentin and a high cost. These approaches had the same disadvantage of leaving a tooth with thin dentinal walls susceptible to fracture and no further root development.² Recently, a novel "Regenerative concept", termed as Revascularization was introduced by Ostby in 1961 and 1966. "Revascularization has been described as replacement of infarcted and necrotic pulp by ingrowing mesenchymal cells and capillaries, followed by deposition of hard tissue on the dentinal walls or by formation of bone in the pulpal lumen."³ Though, the nature of the hard tissue formed in the canal space following revascularization procedures is still under evaluation.⁴ The purpose of this review article is to introduce the novel concept of revascularization in the light of present research and to present the data in a scientific manner.

Overview of Regeneration

'Regeneration' is used to describe 'the process in humans whereby lost specialized tissue is replaced by proliferation of undamaged specialized cells'. It empowers scientists to grow tissues and organs in the laboratory and safely implant them when the body cannot heal itself.⁵ The logic behind the evolution of regenerative endodontic procedures is that the pulp in a fully developed tooth plays no major role in form, function or esthetics and thus its replacement by a filling material in conventional root canal therapy is the most

practical treatment.⁶ Regenerative endodontics comprises research in adult stem cells, growth factors, organ-tissue culture, and tissue engineering materials.

Overview of Potential Technologies For Regeneration Endodontics

Murray et al⁷ recognized the following dimensions of research that could have been utilized for the augmentation of regenerative endodontic techniques:

Root canal revascularization via blood clot

Postnatal stem cell therapy

Pulp implantation

Scaffold implantation

Injectable scaffold delivery

Three dimensional cell printing

Gene delivery

These regenerative procedures are based on the basic tissue engineering principles.⁷

Overview of Revascularization

Revascularization is the procedure to re-establish the vitality in a non-vital tooth to allow repair and regeneration of tissues.⁸ Although according to researchers, term revascularization is debatable as it suggests that the blood supply to the previously necrotic pulp space has been restored.⁹ Lenzi and Trope¹⁰ suggested the term revitalization as being more appropriate because it is descriptive of the non-specific vital tissue that forms in the root canal.

Rationale for Revascularization

The rationale of the revascularization is that if a sterile tissue matrix is provided in which new cells can grow, pulp vitality can be re-established.¹¹

Criteria for Clinical Case Selection

The American Association of Endodontists (AAE) Regenerative Endodontists Committee created a document entitled "Considerations for Regenerative Procedures"¹² The AAE considerations for Case Selection suggest that the cases fulfilling following criteria can be considered for the revascularization. These are:

Tooth with necrotic pulp and an immature apex.
Apex open 1.5 mm allow in growth of tissues.¹³
Pulp space not needed for post/core, final restoration.
Compliant patient/parent.
Patients not allergic to medicaments and antibiotics necessary to complete procedure.¹³

Clinical Technique for Revascularization

A clinical protocol is followed to treat the immature teeth via revascularization procedure which is done in two appointments.¹² (Table no. 2) Pulp revascularization using a triple antibiotic paste (TAP).¹⁴ (a) First appointment:

Local anesthesia followed by isolation of the tooth with a rubber dam and disinfection of the tooth with 10% povidone-iodine (iso-Betadine) before opening it. Opening of the pulp chamber to canal entrance followed by irrigation of root canal with 20mL sodium hypochlorite (1.25%-5.25%) then with physiological saline and finally with 2% chlorhexidine but No instrumentation in root canal. Drying root canal with paper points and insertion of the triple antibiotic paste into root canal. Placement of a cotton ball at the root canal entrance and sealing of the access cavity with a temporary filling

(b) Second appointment (two or three weeks later if asymptomatic tooth and/or absence of fistula):

Local anesthesia without vasoconstrictor followed by isolation of the tooth with a rubber dam and disinfection of the tooth with 10% povidone-iodine (iso-Betadine) before opening it. Opening the tooth to have a access to root canal Removal of the triple antibiotic paste using irrigation with sodium hypochlorite (1.25%-5.25%) then with physiological saline and finally with 2% chlorhexidine. Apical bleeding is initiated. Blood level must be at the cement-enamel junction. Preparation of mineral trioxide aggregate (MTA) and its placement on the clot and in order to form a hermetic seal. Place a wet a cotton ball on MTA filling and sealing of the cavity with a temporary filling.

Composition and mixing instructions of triple antibiotic paste¹⁵

3-Mix-MP Antibiotics (3 Mix)

Ciprofloxacin 200mg

Metronidazole 500mg

Minocycline 100mg

Carrier (MP)

Macrogol ointment

Propylene glycol

The paste can be inserted in the root canal with a lentulo spiral or with a syringe type carrier. Once placed in the root canal, it should be tapped down in the canal gently with a moist cotton pellet to extend it to a point 1mm short of the root apex.¹⁶

Patient Evaluation, Assessment and Recall

The follow up should consist of clinical and radiographic examination. The clinical examination should reveal no pain to percussion /palpation and no soft tissue swelling or sinus tract. Post-operative periapical radiographs should be compared with pre-operative that whether there has been following.¹⁷

Resolution of an apical radiolucency if it was present before treatment.

An increased width of root walls.

An increased root length.

Mechanism of Revascularization

Various researchers have stated the possible mechanisms for the revascularization procedure as:

1. It is likely that few residual vital pulp cells at the apical end of the root canal^{18,19} might multiply into the newly formed matrix and transform into odontoblasts under the organizing influence of cells of Hertwigs epithelial root sheath and can lay down atubular dentin at the apical end, causing apexogenesis and on the lateral aspects of dentinal walls of the root canal, thereby reinforcing as well as strengthening the root.
2. It may also be due to multipotent dental pulp stem cells present in abundance in immature teeth. These cells from the apical end can also attach on the existing dentinal walls and might differentiate into odontoblasts and deposit tertiary or tubular dentin.
3. It could also be due to the existence of stem cells in the periodontal ligament^{21,22} which can increase rapidly and grow in apical end and within the root canal and deposit hard tissue both at the apical end and on lateral walls.
4. The stem cells from the apical papilla (SCAP) or the bone marrow (BMSC). Instrumentation beyond the extent of the root canal to induce bleeding may also transplant mesenchymal stem cells from the bone into the canal lumen.²³
5. Another probable mechanism could be the blood clot which being a rich source of growth factors might stimulate differentiation, growth, and maturation of fibroblast, odontoblast, cementoblast etc. from the immature, undifferentiated mesenchymal cells in the freshly formed tissue matrix.²⁴

Nature of the Tissue Formed

Radiographic changes in the length and thickness of the root could be an indication of pulp revascularization in the canal space.²⁵ Anderson et al¹³ analysed more than 1200 traumatized teeth and 370 auto transplanted premolars and gave four possible outcomes: Revascularization of the pulp with accelerated dentin formation causing pulp canal obliteration. Ingrowth of cementum and periodontal ligament. Inward growth of cementum, PDL, and bone. Ingrowth of bone and bone marrow.

Clinical Complications in Revascularization Procedure

The actual procedure encountered several different problems which were seen during the follow up and

required modifications. These problems were: Tooth discoloration: Bluish discoloration of the crowns was seen. Discoloration appeared on the day following the first therapeutic appointment, which is when the antibiotic mixture is placed in the root canal space.²⁶ Hoshino et al²⁷ developed the triple antibiotic paste and demonstrated the effectiveness of the combination of minocycline, metronidazole, and ciprofloxacin in eliminating the bacteria from the canal space. The bluish discoloration or staining was reported because of the presence of minocycline in the paste. Sato et al²⁶ and Hoshino et al²⁷ both recognized that minocycline caused pigmentation and suggested that it can be replaced with amoxicillin, cefaclor, cefroxadin, fosfomycin or rokitamycin. Another reason for the presence of discoloration may be the use of grey MTA.²⁸ Failure to produce significant bleeding may be the other cause of failure.²⁹ It is seen that induction of significant blood clot is difficult to achieve. It serves to allow the migration of the stem cells along the canal consequently. Absence of such a clot would impede such a migration and thus adversely affect the treatment. It is hypothesized that absence of significant bleeding was caused by the epinephrine in the local anesthetic solution. Bleeding can be induced by overinstrumenting beyond the apex with slightly bent endodontic file dipped in calcium chelator 17% ethylenediaminetetraacetic acid. There can be **collapse of MTA material in the canal space**³⁰ MTA is inserted on top of the newly formed blood clot. The MTA has a setting time of over 2.5 hours and attains an ideal seal at 48 hours and

often the blood clot is not strong enough to withstand the MTA resulting in the collapse of the material. Placing of collagen matrix, Collaplug above the blood clot served as a solid absorbable matrix against which MTA could be packed.³¹ In some studies no significant results were seen in the first 6 months.³² The protocol called for recalls at 1, 2, 3, 6, 12, 18 and 24 months. No significant radiographic changes noted before 6 month follow up appointment. So, it becomes mandatory to emphasize to the parents that success could only be achieved after a long period such as 2 years, and to adhere closely to the protocol.

Challenges and Future Prospects

The next innovation in endodontics is the expected to be the use of regenerative endodontic procedures which are needed to generate the pulp dentin complex.³³ The most challenging part of tissue regeneration is perhaps the functional tissue engineering and regeneration. Pulp tissue is very small, it is highly organized and complex. Regenerated pulp tissue in a tooth should be:³⁴

i) Vascularized. ii) Containing similar cell density and architecture of extracellular matrix to those of natural pulp. iii) Capable of giving rise to new odontoblasts lining against the existing dentin surface and produce new dentin. iv) Innervated.³⁵

Thus for the various regenerative procedures to be widely available and predictable, the clinicians have to depend on tissue engineering therapies to generate pulp in future.

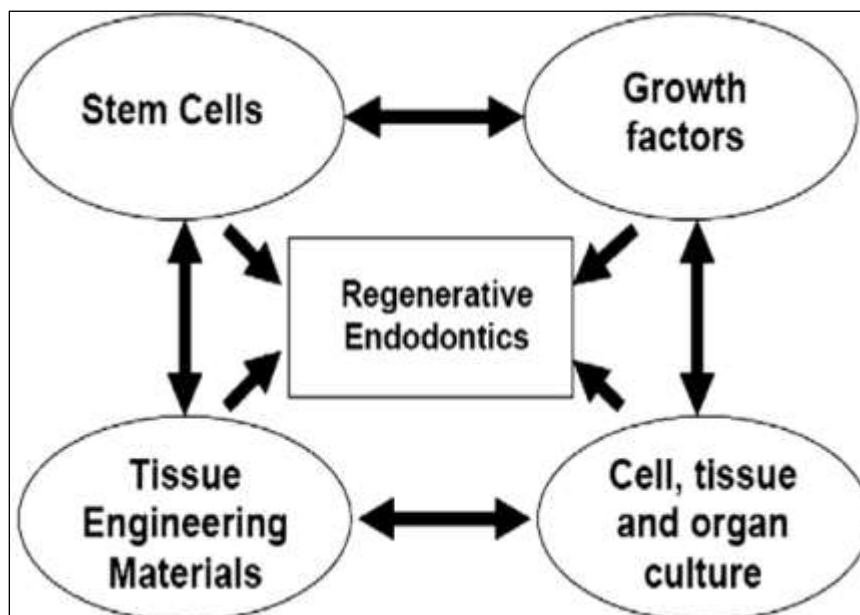



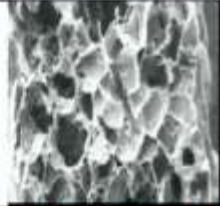





Fig. 1: The major domains of research required to develop regenerative endodontic procedures.

Current considerations for REPs
<p>Case selection:</p> <ul style="list-style-type: none"> • Tooth with necrotic pulp and an immature apex • Pulp space not needed for post/core, final restoration • Compliant patient <p>Informed consent:</p> <ul style="list-style-type: none"> • Two (or more) appointments • Use of antimicrobial(s) • Possible adverse effects: staining of crown/root, lack of response to treatment, pain/infection • Alternatives: MTA apexification, no treatment, extraction (when deemed nonsalvageable) • Permission to enter information into AAE database (optional) <p>First appointment:</p> <ul style="list-style-type: none"> • Local anesthesia, rubber dam isolation, access • Copious, gentle irrigation with 20 mL NaOCl using an irrigation system that minimizes the possibility of extrusion of irrigants into the periapical space (eg, needle with closed end and side vents, or EndoVac). To minimize potential precipitate in the canal, use sterile water or saline between NaOCl; lower concentrations of NaOCl are advised, to minimize cytotoxicity to stem cells in the apical tissues. • Dry canals • Place antibiotic paste or calcium hydroxide. If the triple antibiotic paste is used: (1) consider sealing pulp chamber with a dentin bonding agent to minimize risk of staining, and (2) mix 1:1:1 ciprofloxacin/metronidazole/minocycline (or, if esthetics are crucial, then consider a 1:1 mixture of ciprofloxacin/metronidazole). • Deliver into canal system via lentulo spiral, MAP system, or Centrix syringe • If triple antibiotic paste is used, ensure that it remains below the CEJ (to minimize crown staining) • Seal with 3 to 4 mm of Cavit, followed by immediate restorative material, glass ionomer cement, or another temporary material • Dismiss patient for 3 to 4 weeks <p>Second appointment:</p> <ul style="list-style-type: none"> • Assess response to initial treatment. If there are signs/symptoms of persistent infection, consider additional treatment time with antimicrobial, or alternative antimicrobial. • Anesthesia with 3% mepivacaine without vasoconstrictor, rubber dam, isolation • Copious, gentle irrigation with 20 mL of ethylenediamine tetraacetic acid, followed by normal saline, using a similar closed-end needle • Dry with paper points • Create bleeding into canal system by overinstrumenting (endo file, endo explorer) • Stop bleeding 3 mm from CEJ • Place CollaPlug/CollaCote at the orifice, if necessary • Place 3 to 4 mm of white MTA and reinforced glass ionomer and place permanent restoration <p>Follow-up:</p> <p>Clinical and radiographic examination:</p> <ul style="list-style-type: none"> • No pain or soft tissue swelling (often observed between first and second appointments) • Resolution of apical radiolucency (often observed 6–12 months after treatment) • Increased width of root walls (this is generally observed before apparent increase in root length and often occurs 12–24 months after treatment) • Increased root length <p>Data from Available at: www.aae.org/Dental_Professionals/Considerations_for_Regenerative_Procedures.aspx.</p>

Fig. 2: Considerations for revascularization procedure.

Technique	Image	Advantages	Disadvantages
Root-canal revascularization: open up tooth apex to 1 mm to allow bleeding into root canals		<ul style="list-style-type: none"> ✓ Lowest risk of immune rejection ✓ Lowest risk of pathogen transmission 	<ul style="list-style-type: none"> ➤ Minimal case reports published to date ➤ Potential risk of necrosis if tissue becomes reinfected
Stem cell therapy: autologous or allogenic stem or cells are delivered to teeth via injectable matrix		<ul style="list-style-type: none"> ✓ Quick, ✓ Easy delivery ✓ Least painful ✓ Cells are easy to harvest 	<ul style="list-style-type: none"> ➤ Low cell survival ➤ Cells do not produce new functioning pulp ➤ High risk of complications
Pulp implant: pulp tissue is grown in the laboratory in sheets and implanted surgically		<ul style="list-style-type: none"> ✓ Sheets of cells are easy to grow ✓ More stable than an injection of dissociated cells 	<ul style="list-style-type: none"> ➤ Sheets lack vascularity so only small constructs are possible ➤ Must be engineered to fit root canal precisely
Scaffold implant: pulp cells are seeded onto a 3-D scaffold made of polymers and surgically implanted		<ul style="list-style-type: none"> ✓ Structure supports cell organization ✓ Some materials may promote vascularization 	<ul style="list-style-type: none"> ➤ Low cell survival after implantation ➤ Must be engineered to fit root canal precisely
3-D cell printing: ink-jet-like device dispenses layers of cells in a hydrogel which is surgically implanted		<ul style="list-style-type: none"> ✓ Multiple cell types can be precisely positioned 	<ul style="list-style-type: none"> ➤ Must be engineered to fit root canal precisely ➤ Early-stage research has yet to prove functional in vivo
Injectable scaffolds: polymerizable hydrogels, alone or containing cell suspension are delivered by injection		<ul style="list-style-type: none"> ✓ Easy delivery ✓ May promote regeneration by providing substitute for extracellular matrix 	<ul style="list-style-type: none"> ➤ Limited control over tissue formation ➤ Low cell survival ➤ Early-stage research has yet to prove functional in vivo
Gene therapy: mineralizing genes are transfected into the vital pulp cells of necrotic and symptomatic teeth		<ul style="list-style-type: none"> ✓ May avoid cleaning and shaping root canals ✓ May avoid the need to implant stem cells 	<ul style="list-style-type: none"> ➤ Most cells in a necrotic tooth are already dead ➤ Difficult to control ➤ Risk of health hazards ➤ Not approved by the FDA

Tables 1: Developmental approaches for regenerative endodontic technique.

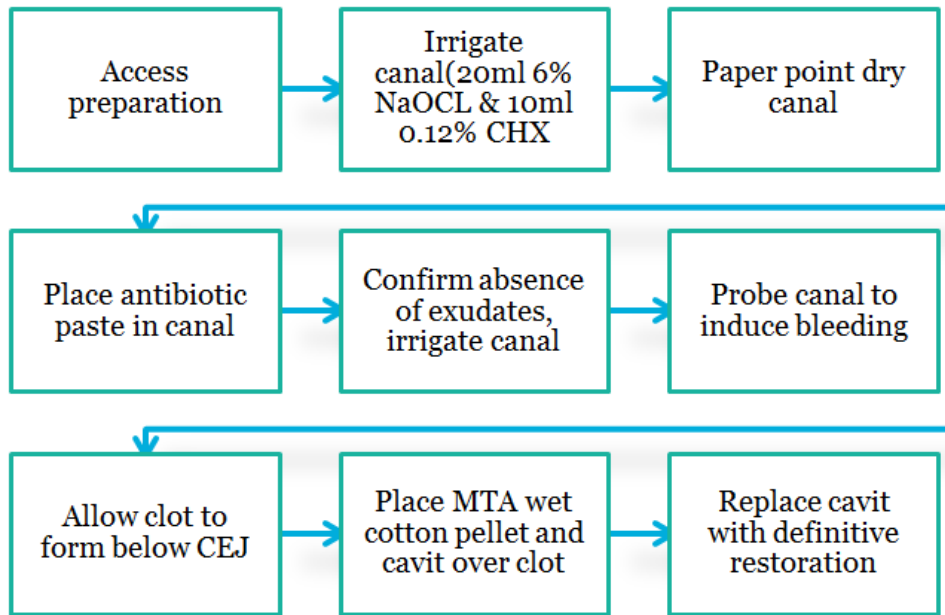


Table 2: Pulp revascularization using a triple antibiotic paste (TAP)

Conclusion

The revitalization approach for managing immature permanent teeth with infected pulp and/or apical periodontitis allows the ingrowth of vital tissue consisting of tissues resembling cementum, PDL, bone. These tissues are not pulp tissues. They do not function like pulp tissue. The available case reports of pulp revascularization were generally reported on young patients (with high stem cell populations) and teeth with open apices. The proposed therapies involving stem cells, growth factors, and tissue engineering all require pulp revascularization, in itself an enormous challenge. One of the most challenging aspect is to understand how the various component procedures can be optimized and integrated to produce the outcome of a regenerated pulp-dentin complex. The future development will require a comprehensive research program directed at each of these components and their application to our patients. Based on the accumulated laboratory and clinical evidence, a road map to establish "Regeneration of Pulp" should thus be presented, as a solid consensus towards the future of dentistry.

Conflict of Interest: None.

References

- Jadhav GR, Shah N, Logani A. Comparative outcome of revascularization in bilateral, non-vital, immature maxillary anterior teeth supplemented with or without platelet rich plasma: A case series. *J Conserv Dent* 2013;16(6):568-72.
- Thibodeau B. Case Report: Pulp revascularization of a necrotic, infected, immature permanent tooth. *Pediatr Dent* 2009;31(2):145-8.
- Kling M, Cvek M, Mejare I. Rate and predictability of pulp revascularization in therapeutically reimplanted permanent incisors. *Endod Dent Traumatol* 1986;2(3):83-9.
- Reynolds K, Johnson JD, Cohenca N. Pulp revascularization of necrotic bilateral bicuspid using a modified novel technique to eliminate potential coronal discoloration: A case report. *Int Endod J* 2009;42(1):84-92.
- Mason C, Dunnill P. A brief definition of regenerative medicine. *Regen Med Jan* 2008;3(1):1-5.
- Van der Burgt TP, Plasschaert AJ. Tooth discoloration induced by dental materials. *Oral Surg Oral Med Oral Pathol* 1985;60(6):666-9.
- Murray PE, Garcia-Godoy F, Hargreaves KM. Regenerative Endodontics: A review of current status and a call for action. *J Endod* 2007;33(4):377-90.
- Archana MS, Sujana V, Nagesh B, Babu PJK. Revascularization – An Overview. *J Int Dent Med Res* 2012;5(1):55-9.
- Lenzi R and Trope M. Revitalization procedures in two traumatized incisors with different biological outcomes. *J Endod* 2012;38(3):411-4.
- Lenzi R, Trope M, Thibodeau B. Revitalization procedures in two traumatized incisors with different biological outcomes. *J Endod* 2012;38(3):411-4.
- Kansal N, Kansal R, Garg P, Joshi R, Garg D, Grover HS. Management of immature teeth by dentin- pulp regeneration: A recent approach. *Med Oral Patol Oral Cir Bucal* 2011;16(7):e997-1004.
- Law, Alan S. American Association of Endodontics. Considerations for regenerative procedures. *Pediatr Dent* 2013;35(2):141-152.
- Anderson JO, Paulsen HU, Yu Z. A long term study of 370 autotransplanted premolars: Part I- Surgical procedures and standardized techniques for monitoring healing. *Eur J Orthod* 1990;12(1):3-13.
- Namour M, Theys S. Pulp Revascularization of Immature Permanent Teeth: A Review of the Literature and a Proposal of a New Clinical Protocol. *Sci World J* 2014x;1-9.
- Trope M. Treatment of immature teeth with non- vital pulps and apical periodontitis. *Dent Clin North Am* 2010;54(2):313-24.
- Wigler R, Kaufman AY, Lin S, Steinbock N, Hazan-Molina H, Torneck CD et al. Revascularization: A treatment for permanent teeth with necrotic pulp and incomplete root development. *J Endod* 2013;39(3):319-26.
- Law AS. Considerations for regeneration Procedures. *Pediatr Dent* 2013;35(2):141-52.

18. Banchs F, Trope M. Revascularization of immature permanent teeth with apical periodontitis: new treatment protocol? *J Endod* 2004;30(4):196-200.
19. Heithersay GS. Stimulation of root formation in incompletely developed Pulpless teeth. *Oral Surg Oral Med Oral Pathol* 1970;29(4):620-30.
20. Gronthos S. Stem cell properties of human dental pulp stem cells. *J Dent Res* 2002;81(8):531-5.
21. Liberman J, Trowbridge H. Apical closure of non vital permanent incisor teeth where no treatment was performed: case report. *J Endod* 1983;9(6):257-60.
22. Nevin A, Wrobel W, Valachovic R, Finkelstein F. Hard tissue induction into Pulpless open apex teeth using collagen-calcium phosphate gel. *J Endod* 1977;3(11):431-3.
23. Krebsbach P, Kuznetsov SA, Satmura K, Emmons RV, Rowe DW, Robey PG et al. Bone formation in vivo: comparison of osteogenesis by transplanted mouse and human marrow stromal fibroblasts. *Transplant* 1997;63(8):1059-69.
24. Wang Q, Lin XJ, Lin ZY, Liu GX, Shan XL. Expression of vascular endothelial growth factor in dental pulp of immature and mature permanent teeth in human. *Shanghai KonQiang Yi Zue* 2007;16(3):285-9.
25. Ritter ALS, Ritter AV, Murrah V, Sigurdson A, Trope M. Pulp revascularization of replanted immature dog teeth after treatment with minocycline and doxycycline assessed by laser Doppler flowmetry, radiography, and histology. *Dent Traumatol* 2004;20(2):75-84.
26. Sato I, Ando-Kurihara N, Kota K, Iwaku M, Hoshino E. Sterilization of infected root canal dentine by topical application of a mixture of ciprofloxacin, metronidazole and minocycline in situ. *Int Endod J* 1996;29(2):118-24.
27. Hoshino E, Kurihara –Ando N, Sato I. In vitro antibacterial susceptibility of bacteria taken from infected root dentine to a mixture of ciprofloxacin, metronidazole and minocycline. *Int Endod J* 1996;29(2):125-30.
28. Parirokh M, Torabinejad M. Mineral trioxide aggregate: a comprehensive literature review – part I chemical, physical, and antibacterial properties. *J Endod* 2010;36(1):16-27.
29. Dabbagh B, Alvaro E, Vu DD, Rizkallah J, Schwartz S. Clinical complications in the revascularization of immature necrotic permanent teeth. *Pediatr Dent* 2012;34(5):414-7.
30. Torabinejad M and Parirokh M. Mineral Trioxide Aggregate: A Comprehensive Literature Review—Part II: Leakage and Biocompatibility investigations. *J Endod* 2010;36(2):190-202.
31. Gomes-Filho JE. Tissue reaction to a triantibiotic paste used for endodontic tissue self-regeneration of nonvital immature permanent teeth. *J Endod* 2012;38(1):91-4.
32. Huang GT. A paradigm shift in endodontic management of immature teeth: conservation of stem cells for regeneration. *J Dent* 2008;36(6):379-86.
33. Goodis HE, Kinaia BM, Atheel M, Kinaia, Sami, M.A. Chogle. Regenerative Endodontics and Tissue Engineering: What the Future Holds?: *Dent Clin N Am* 2012 Jul; 56 (3):677-89.
34. Hargreaves KM, Geisler T, Henry M, Wang Y. Regeneration potential of the young permanent tooth: what does the future hold? *Pediatr Dent* 2008;30(3):253-60.
35. Wigler R, Kaufman AY, Lin S, Steinbock N, Hazan-Molina H, Torneck CD et al. Revascularization: A treatment for permanent teeth with necrotic pulp and incomplete root development. *J Endod* 2013;39(3):319-26.

How to cite this article: Jain A, Nikhil V, Mishra P, Bansal K, Jain A, Tooth resurrection: Life after death. *Indian J Conserv Endod* 2019;4(2):42-8.