

Conservative management of pink tooth of mummery: A case report

Preeti Mishra^{1*}, Vineeta Nikhil², Shikha Jaiswal³, Isha Sajjanahar⁴

^{1,4}Lecturer, ²Professor and Head, ³Professor, Dept. of Conservative Dentistry and Endodontics, Subharti Dental College Swami, Vivekanand Subharti University, Uttar Pradesh, India

***Corresponding Author: Preeti Mishra**

Email: preeti.prajesh@gmail.com

Abstract

Resorption is a condition associated with either a physiologic or a pathologic process that results in loss of substance from a tissue such as dentin, cementum or alveolar bone". It is of great concern to the endodontists. Early diagnosis, removal of the cause, proper treatment and reinforcement of the resorbed root is mandatory for achieving success. This paper present a case report of successful conservative management of internal resorption in maxillary incisor.

Keywords: Calamus, Endoactivator, Internal resorption, Pink tooth, Thermoplastized obturation

Introduction

Internal resorption is a resorptive defect of the internal aspect of the root as a result of the chronic inflammation and bacterial invasion of the pulpal tissue.¹ Due to bacterial stimulation chronic inflammation of the coronal/radicular pulp sets in. This causes damage to predentin transformation of normal pulp tissue into granulomatous tissue with giant cells that resorbs dentin.² The diagnosis and management of this condition is a challenge to dental practitioner. Treatment requires inhibiting cellular activity which is responsible for resorptive process. This case reports presents a case of internal resorption following trauma which was treated successfully using thermoplastized obturation technique.

Case Report

A 25 years old male patient reported to the Department of Conservative Dentistry and Endodontics, Subharti Dental College and Hospital, Meerut with a chief complaint of discoloration in the upper front tooth region. Clinical examination revealed the presence of pink discoloration with respect to the crown of the

right maxillary central incisor (Fig. 1: 1,2). The tooth was found to be unresponsive to vitality testing. An intraoral periapical radiograph revealed the presence of an enlarged root canal space with mild to moderate radiolucency (Fig. 1: 1,3). The diagnosis of pulpal necrosis with internal resorption was made. Root canal treatment was planned for this tooth. An access opening was done followed by cleaning and shaping of root canal space upto F4 Protaper Universal file. Irrigation was carried out with normal saline and 3% sodium hypochlorite. The irrigant was activated with endoactivator which was followed by placement of calcium hydroxide mixed with saline for 1 week. After 1 week the root canal was obturated using thermoplasticised obturation technique (Fig. 2: 2. 1). Sectional obturation was performed in the apical portion of the canal till the resorptive defect. The remainder of the canal was back filled with Calamus (Fig. 2: 2,3). The tooth was restored with composite. During the follow-up visit tooth was found to be asymptomatic and functional.

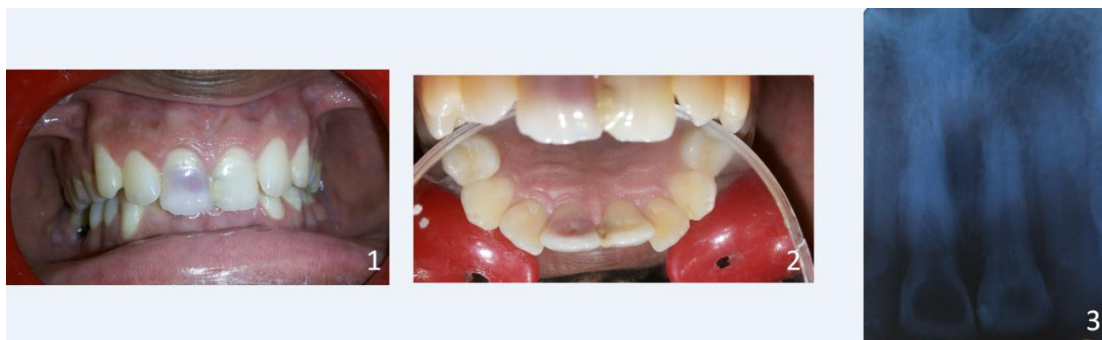


Fig. 1-3: Preoperative facial view; 2. Preoperative palatal view; 3. Preoperative radiograph

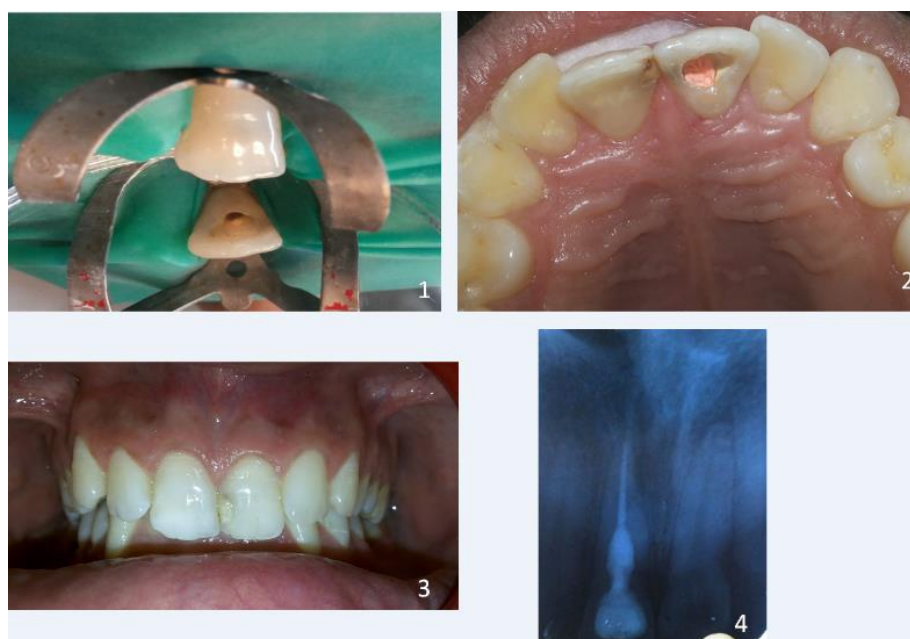

Fig. 2: 1 Access cavity preparation; 2. Post operative palatal view; 3. Post Operative facial view; 4. Post operative radiograph.

Discussion

Internal resorption is commonly asymptomatic and is often diagnosed clinically or through full mouth radiographs.³ However, pain may occur depending on the pulpal condition or perforation of the root into the periodontal space. The location of internal resorption determines the clinical signs for this condition. If resorption is localized to the coronal part of the tooth, it may appear as a pinkish hue that is classically described as the pink tooth of Mummery.^{4,5} The presence of highly vascularized connective tissue adjacent to the resorbed enamel or dentin imparts the pinkish color to the crown. However, if left untreated the tooth turns gray/ dark gray in color.

Resorption as a result of the inflammatory process progresses without any deposition of hard tissues

adjacent to the resorptive sites. This is characterized by the presence of granulation tissues in the resorbed area and appears as a radio clear zone centered on the root canal.⁶ Histologically, internal root resorption is characterized by the presence of highly vascularized pulpal connective tissue infiltrated by lymphocytes and plasma cells as well as 'resorptive bays'. Bacteria may be present only in the teeth undergoing rapidly progressing resorption. Scanning electron microscopy (SEM) revealed large odontoclastic cells, 50 μ m in size and with a ruffled border directed against the dentin surface. Treatment of such cases involves sealing of internal resorption with bioactive materials either surgically or non surgically. The choice of treatment depends on the extension of resorption. The aim of conservative treatment is to remove remaining vital, apical tissue and the necrotic coronal portion of the

pulp that might be stimulating the resorbing cells via their blood supply, and to disinfect and obturate the root canal system.⁷ Because of irregular canal shape, a great emphasis is placed on the chemical dissolution of the vital and the necrotic pulp tissue with concentrated sodium hypochlorite. The use of ultrasonic devices facilitates the penetration of the irrigation solution such as sodium hypochlorite into the inaccessible areas of the root canal system. The use of calcium hydroxide as an intracanal medicament in internal resorption has two important goals. One is to control bleeding, other is to necrotize residual pulp tissue and to make the necrotic tissue more soluble to sodium hypochlorite. Thermoplastic gutta-perch techniques are significantly better in filling resorptive cavities than cold lateral condensation.⁸ Sealing of internal root resorption with bioactive material is indicated in presence of a perforation of the canal walls with a communication between the root canal system and the periapical tissue. Mineral trioxide aggregate (MTA) is the material of choice.

The surgical approach is needed when it is not possible to get access to the perforated lesion through the canal. The surgical approach allows direct access to the lesion and mechanical cleaning of the resorbed defect. Prognosis of the treatment is fairly good or even excellent for cases that have not perforated and where the tooth has not been weakened too much by the loss of tooth structure. The smaller the perforation size, the more predictable the prognosis of the tooth.

Conclusion

Internal resorption is difficult to predict and also challenging to treat. It requires good clinical skills to diagnose, treat, and prevent the progression of such a condition. However, safest approach is to prevent its

occurrence and take measures to inhibit its extension. This area needs further investigation.

Source of Funding

None.

Conflict of Interest

None.

References

1. Altindasar E, Demir B. Management of a Perforating Internal Resorptive Defect with Mineral Trioxide Aggregate: A Case Report. *J Endod* 2009;35(10):1441-4.
2. Meire M, Moor R. Mineral trioxide aggregate repair of a perforating internal resorption in a mandibular molar. *J Endod* 2008;34(2):220-3.
3. Thomas P, Pillai RK, Ramakrishnan BP, Palani J. An Insight into Internal Resorption. *ISRN Dent* 2014;2014:759326.
4. Thomas P.: An Insight into Internal Resorption". *ISRN Dentistry* 2014:759326.
5. Ingle JJ. "Ingle's Endodontics". 6th edition Lewiston: BC Decker 2008.
6. Fuss Z, Tsesis I, Lin S. Root resorption- diagnosis, classification and treatment choices based on stimulation factors. *Dent Traumatol* 2003;19(4):175-82.
7. European society of endodontology. Quality guidelines for endodontic treatment: consensus report of the European Society of Endodontology. *Int Endod J* 2006;39(12):921-30.
8. Goldman F, Massone EJ, Esmoris M, Alfie D. Comparison of different techniques for obturating experimental internal resorptive cavities. *Endod Dent Traumatol* 2000;16:116-21.

How to cite this article: Mishra P, Nikhil V, Jaiswal S, Sajjanahar I. Conservative management of pink tooth of mummery: A case report. *Indian J Conserv Endod* 2019;4(4):140-2.