



Case Report

Nonsurgical management of a large periapical lesion – A case report

Ramesh Kumar M¹, Amitha Krishna^{1,*}, Elsy P Simon¹, Chandini Raveendran¹,
Mariyam Sanoona¹, Deepa Jayaraj¹

¹Dept. of Conservative Dentistry and Endodontics, KMCT Dental College, Kozhikode, Kerala, India



ARTICLE INFO

Article history:

Received 09-04-2020

Accepted 28-04-2020

Available online 25-05-2020

Keywords:

Radicular cyst

Cleaning and shaping

ABSTRACT

A 14 year child reported with a swelling and mobile upper right lateral incisor and was diagnosed with periapical cyst. the case report deals with the diagnosis, treatment and follow up of the case.

© 2020 Published by Innovative Publication. This is an open access article under the CC BY-NC-ND license (<https://creativecommons.org/licenses/by/4.0/>)

1. Introduction

Periapical lesions are the result of bacterial infection invading the dental pulp.¹ The finding of this infection is typically accomplished either during assessment of the radiographs or following intense indications or symptoms in a tooth. The vast majority of the periapical injuries (>90%) can be delegated as dental granulomas, radicular growths or abscesses. The incidence of cysts, periapical granulomas and abscesses within periapical lesions ranges between 6 and 55%, 9.3 and 87.1% and 28.7 and 70.07% respectively.²

Traditionally, diagnosis of disease of tissues or organs is dependent on clinical and histologic findings. Clinical diagnosis is a provisional diagnosis and uses objective and subjective signs and/or symptoms and all available tests in clinical dental medicine as well as imaging systems. Radiography is designed to detect pathologic changes at the tissue or organ level and not at the cellular level. Histologic examination provides information that makes a definitive and final diagnosis possible at a cellular level.

Periapical cysts, being the most widely recognized odontogenic cysts are inflammatory jaw cysts, generally found at the apices of teeth with contaminated or

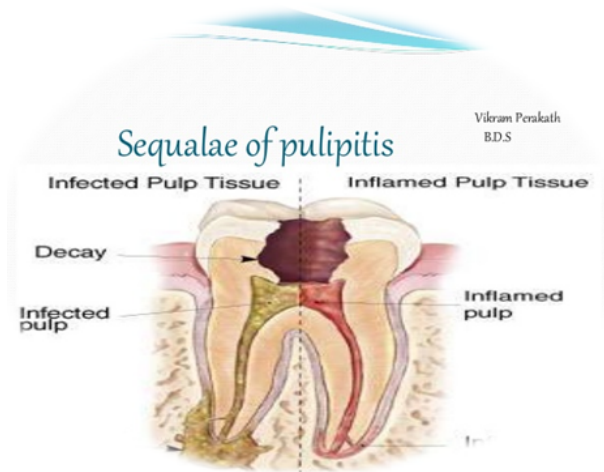


Fig. 1:

necrotic pulps.^{2,3} However, some huge lesions have been demonstrated to be granulomas. They can't be analyzed clinically and the best way to arrive at an authoritative conclusion is histologic assessment. Be that as it may, a periapical cyst can be distinguished dependent on certain

* Corresponding author.

E-mail address: krishnamith@gmail.com (A. Krishna).

clinical discoveries:

1. More than one non fundamental teeth is included and the size of the lesion is more prominent than 200mm²
2. Radiographically, the injury is a very much characterized, radiolucency encompassed by a slight radiopaque line.
3. A straw-colored exudate while aspirating the lesion or draining from the canals on access opening.⁴

The goal behind the endodontic treatment is to concentrate on the included teeth to return it to a condition of wellbeing and capacity without careful mediation.⁵ Initially, regular endodontic treatment ought to be the treatment of decision for all the inflammatory injuries.⁶ Surgical intercession is prescribed just if the nonsurgical procedures come up short.⁷

This case report describes how the periapical lesion was managed nonsurgically with orthograde endodontic treatment, which not only treated the lesion but also recovered the esthetics and function, founding inspirational disposition towards dental treatment in a developing kid.

2. Case Report

A 14-year-old boy along with his parents reported to dept. of conservative dentistry and endodontics complaining pain and swelling on the right upper front tooth region. Patient and patient's parent gave a past filled with an accidental ball hit a half year prior concerning a similar area.

2.1. On Examination

Clinical, subjective and objective examination revealed that the right lateral incisor (#7) was found to be non-vital with grade II mobility.

#7 gives - non vital response to cold test, tender on percussion, obliteration of the labial sulcus suggestive of swelling

2.2. Radiograph assessment

Intraoral periapical radiograph revealed a very large radiolucency surrounding apex and lateral parts of the root displacing the nearby adjacent roots. The clinical and radiographic signs were suggestive of chronic periapical abscess (cyst) in relation to #7.

2.3. Treatment planned and executed

The access cavity was prepared in relation to #7 with endoaccess bur. The root canal was negotiated, instrumented and sterile normal saline irrigant was used in large amounts, to clear out the yellowish straw-colored exudate. Root canal preparation was done using a CROWN DOWN TECHNIQUE using hand ProTaper files after estimating the working length using electronic apex locator and confirming it radiographically.

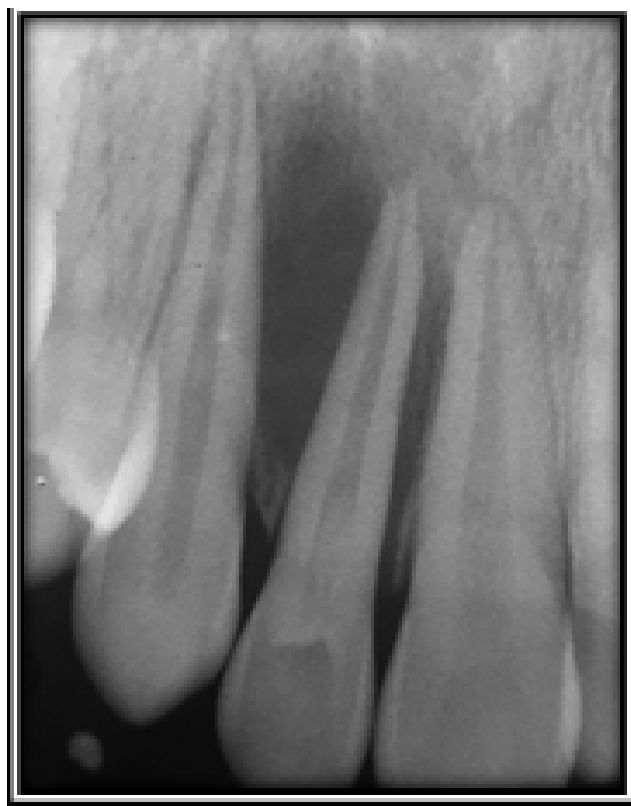

Fig. 2:

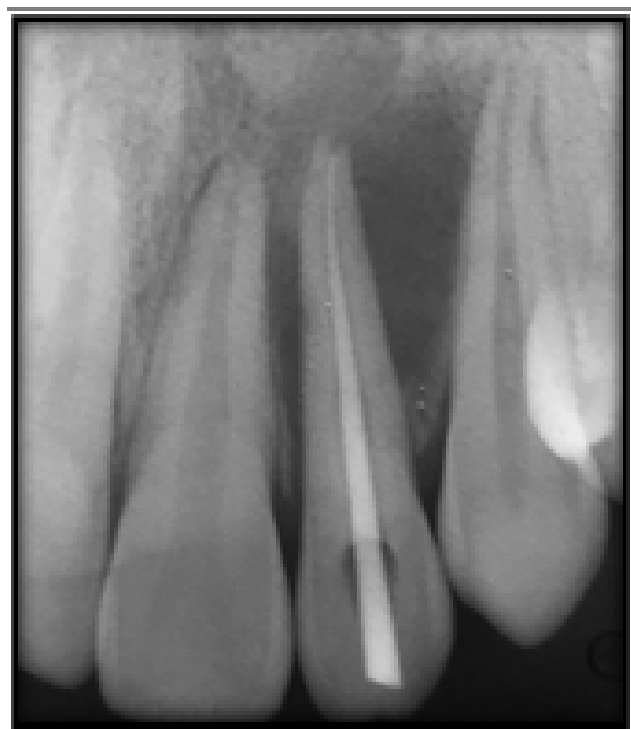

Fig. 3:

This procedure of only irrigating the canals without the placement of any intracanal medicament, continued till the active drainage ceased. At the point when the drainage stopped totally, calcium hydroxide dressing was mixed and placed. The medicament was reestablished multiple times in the term of 1.5 months. After 2 months, a dynamic involution of periapical radiolucency was observed radiographically.

The tooth was then obturated after confirming the canal is dry. Obturation was done with gutta percha cones and zinc oxide eugenol sealer using lateral condensation technique, sealing the cavity with a temporary filling material which was later replaced by composite resin filling material. Patient stayed asymptomatic during post-treatment recalls. 3 months and 6 months post treatment radiographic follow up uncovered practically complete goals of endodontic treatment with nearly complete involution of periapical radiolucency.

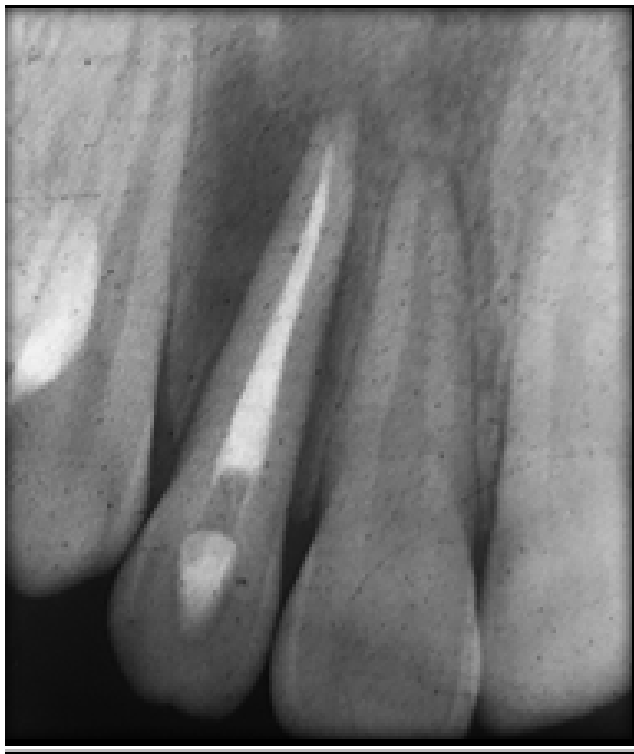

Fig. 4: Immediate post op radiograph

Review and follow up...

3. Discussion

An apical cyst be it a pocket or a true cyst is believed to have formed from proliferation of remnants of Hertwig's epithelial root sheath, i.e.; epithelial cell rests of Malassez in apical periodontitis lesions.⁸ Henceforth periapical cyst ought to be viewed as apical periodontitis with cyst enlargement. It is more like an inflammatory lesion, rather than a tumor. Hence, it has a capacity to subside once the irritant is

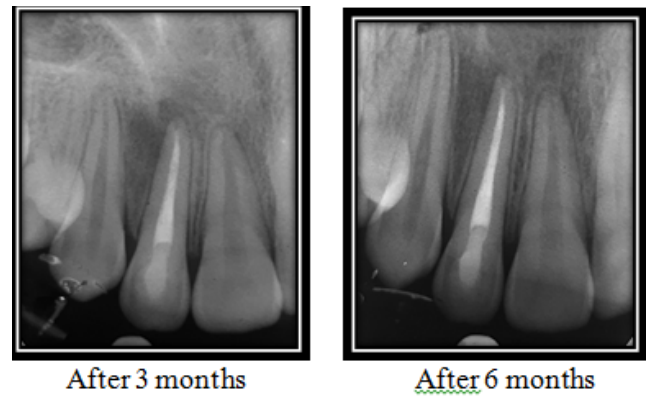


Fig. 5:

removed.⁹

Inflammatory mediators, pro-inflammatory cytokines, along with signaling molecules released from innate and adaptive immune cells will be reduced and lining epithelium of the cyst will die from apoptosis, until periapical inflammation is reduced.¹⁰

In cases where the lesion on the radiograph is visible, Bhaskar SN has demonstrated that the instrumentation of the root canal ought to be performed 1 mm past the apical foramen. It brings about impermanent irritation and ulceration of the epithelial coating, which results in cyst resolution.¹¹ Bender strengthened in his analysis on Bhaskar's speculation that drainage is achieved after the instrument of the root channel is entered through the apical foramen to the focal point of the radiolucency, as an outcome of which the pressure is relieved.

Subsequently, when the drainage ceases, fibroblasts begin to proliferate and collagen deposits contribute to the collapse of the capillary network, which leads the epithelial cells to starve and degenerate and is eventually eaten up by the macrophages.¹²

Full debriding is difficult with root canal irrigation, which was achieved using 3 percent NaOCl, but should also be accompanied by the application of an intracanal calcium hydroxide drug to minimize bacterial count. *Candida albicans* are regularly present in endodontic insusceptible and secondary infections, just as in periradicular lesions. 3% NaOCl has indicated some bactericidal impact against *C. albicans* and *E. faecalis*.¹³ Calcium hydroxide medicament is obviously to have gained notoriety for being an intracanal medicament on account of its high alkalinity and bactericidal effects, including eliminating bacterial endotoxins.^{14,15} It is proposed that the base time should be 2-3 weeks for Ca(OH)₂ to stay in the root canal, as this may impact its sufficiency depending upon the scattering of the hydroxyl particles at proper fixations in the root canal.¹⁶

A definitive fix happens through the dissemination of calcium hydroxide through the apical foramen, actuating

plentiful inflammatory activity to cut off the cystic epithelial lining, joined by an invagination of the connective tissue.¹⁶ Furthermore, Souza et al proposed the fourfold activity of calcium hydroxide past the peak: anti-inflammatory activity; acid neutralization; alkaline phosphatase activation; antibacterial action.¹⁷ Periapical wound is slowly filled with fibrovascular granulation tissue as activated macrophages gradually extract damaged periapical tissue.¹⁸

Surgical treatment should have included removal and possibly apicectomy of the diseased periapical tissue. For children an operation will normally be painful and more stressful than traditional endodontic treatment. Truth be told, apicectomy will decrease the usable length of a young permanent tooth, hampering the proportion of the crown root² This entanglement would be deflected by following a traditionalist technique that would permit healing and develop mature configurations of the root canal and apices.¹⁹

4. Conclusion

Nonsurgically, the treatment of periapical lesions has shown a high success rate. A detailed clinical review, proper diagnosis and the appropriate treatment procedure shall be used to remove their etiology in the root canal system rather than the apical true cyst of their drug.

A nonsurgical treatment should always precede surgical treatment. Studies conclude that surgical success rate is always high when it is preceded by nonsurgical treatment. Periodic follow-up monitoring and follow up examination are essential. Those situations that are refractory to nonsurgical therapy, such as in obstructed or non-negotiable channels and where long-term monitoring of periapical lesions is not feasible, are considered an optimal therapy of preference.

5. Source of Funding

None.

6. Conflict of Interest

None.

References

1. Möller AJ, Fabricius L, Dahlén G, Ohman AE, Heyden G. Influence on periapical tissues of indigenous oral bacteria and necrotic pulp tissue in monkeys. *Scand J Dent Res*. 1981;89(6):475-84.
2. Fernandes M, Ataide I. Nonsurgical management of periapical lesions. *J Conserv Dent*. 2010;13(4):240.
3. Natkin E, Oswald RJ, Carnes LI. The relationship of lesion size to diagnosis, incidence, and treatment of periapical cysts and

- granulomas. *Oral Surg, Oral Med, Oral Pathol*. 1984;57:82-94.
4. Eversole LR. Clinical outline of oral pathology: diagnosis and treatment. PMPH-USA; 2001.
5. Salamat K, Rezai RF. Nonsurgical treatment of extraoral lesions caused by necrotic nonvital tooth. *Oral Surg, Oral Med, Oral Pathol*. 1986;61(6):618-623.
6. Lin LM, Huang GT, Rosenberg PA. Proliferation of epithelial cell rests, formation of apical cysts, and regression of apical cysts after periapical wound healing. *J Endod*. 2007;33(8):908-16.
7. Nicholls E. Bristol: John Wright Sons Ltd; 1984. p. 206.
8. Cate ART. The epithelial cell rests of Malassez and the genesis of the dental cyst. *Oral Surg, Oral Med, Oral Pathol*. 1972;34:956-964.
9. Main D. Epithelial jaw cysts: 10 years of WHO classification. *J Oral Pathol*. 1985;14(1):1-7.
10. Lin LM, Ricucci D, Lin J, Rosenberg PA. Nonsurgical Root Canal Therapy of Large Cyst-like Inflammatory Periapical Lesions and Inflammatory Apical Cysts. *J Endod*. 2009;35(5):607-15.
11. Bhaskar SN. Nonsurgical resolution of radicular cysts. *Oral Surg, Oral Med, Oral Pathol*. 1972;34:458-68.
12. Bender IB, Bender. Commentary on General Bhaskar's hypothesis. *Oral Surg Oral Med Oral Pathol*. 1972;34:469-76.
13. Mohamad AA, Fariba F, Nahid MM, Yadollah M. Evaluation of the antimicrobial effects of MTAD, NaOCl against selected endodontic pathogens. *Int Endod J*. 2009;4(2):63-68.
14. Siqueira JF, Lopes HP. Mechanisms of antimicrobial activity of calcium hydroxide: a critical review. *Int Endod J*. 1999;32(5):361-9.
15. Tanomaru JMG, Leonardo MR, Filho MT, Filho IB, Silva LAB. Effect of different irrigation solutions and calcium hydroxide on bacterial LPS. *Int Endod J*. 2003;36(11):733-9.
16. Ghose LJ, Baghdady VS, Hikmat BYM. Apexification of immature apices of pulpless permanent anterior teeth with calcium hydroxide. *J Endod*. 1987;13(6):285-90.
17. Caliskan M. Prognosis of large cyst-like periapical lesions following nonsurgical root canal treatment: A clinical review. *Int Endod J*. 2004;37(6):408-16.
18. Lin LM, Gaengler P, Langeland K. Periradicular curettage. *Int Endod J*. 1996;29(4):220-7.
19. Dandotikar D, Peddi R, Lakhani B, Lata K, Mathur A, Chowdary UK, et al. Nonsurgical management of a periapical cyst: a case report. *J Int Oral Health: JIOH*. 2013;5(3):79.

Author biography

Ramesh Kumar M Professor and HOD

Amitha Krishna Post Graduate Student

Elsy P Simon Professor

Chandini Raveendran Senior Lecturer

Mariyam Sanoona Post Graduate Student

Deepa Jayaraj Post Graduate Student

Cite this article: Kumar M R, Krishna A, Simon EP, Raveendran C, Sanoona M, Jayaraj D. **Nonsurgical management of a large periapical lesion – A case report.** *IP Indian J Conserv Endod* 2020;5(2):75-78.