



## Case Report

# Morphologic variations of roots and root canals in maxillary second molar: Case reports

M Ramesh Kumar<sup>1</sup>, Mariyam Sanoona Areekan<sup>1,\*</sup>, Elsy P Simon<sup>1</sup>, Chandini Raveendran<sup>1</sup>, Amitha Krishna<sup>1</sup>, Deepa Jayaraj<sup>1</sup>

<sup>1</sup>Dept. of Conservative Dentistry & Endodontics, KMCT Dental College, Kozhikode, Kerala, India



### ARTICLE INFO

#### Article history:

Received 2604-2020

Accepted 13-05-2020

Available online 25-05-2020

#### Keywords:

Maxillary molar  
Complex anatomy  
Four roots.

### ABSTRACT

The importance of potential variations in root canal system in the field of dentistry cannot be ignored. The goal of this case report is to present endodontically treated maxillary second molars with an uncommon morphology of four roots and a single fused root.

© 2020 Published by Innovative Publication. This is an open access article under the CC BY-NC-ND license (<https://creativecommons.org/licenses/by/4.0/>)

## 1. Introduction

In multirouted tooth, there are chances in having deviations in root canal number and anatomy and need proper diagnosis and skilful management.<sup>1</sup> For successful endodontic management, dentist must be familiar with these distinctive root canal configurations and their variations.<sup>2</sup> Inability to identify and to negotiate the complexities in root canal system result in uncertainty of the treated tooth. The endodontic treatment of maxillary second molars (MSMs) can consistently be incredibly inconvenient as a result of the perplexed root canal anatomy and variant internal structures. Root canal morphology of the MSM have demonstrated that the most frequently encountered type, considered as standard morphology, has three roots: one mesiobuccal, one distobuccal, and one palatal with a single canal in each root.<sup>3</sup>

Some unusual anatomy of the MSM have been accounted in the literature. Several authors reported MSMs with one mesial and one distal root, which are like mandibular molars and 2 root canals in relation to each root. Zmener et al<sup>4</sup>

reported a case of maxillary second molar with three buccal roots and Ozcan et al<sup>5</sup> reported endodontic management of MSM with three canals in the MB(mesiobuccal) root. Kottoor et al<sup>6</sup> showed a case of 5 roots with 5 canals. Double palatal roots were also reported by several authors.<sup>7</sup>

The root canal anatomy and its complexities are genetically determined and are of decisive significance in anthropology there by requiring the identification of root canal morphologies of teeth in different ethnic groups.<sup>8</sup> This case reports presents the endodontic treatment of single rooted MSM with single canal and four rooted MSM with four canals.

## 2. Case Report 1

(Single rooted maxillary second molar)

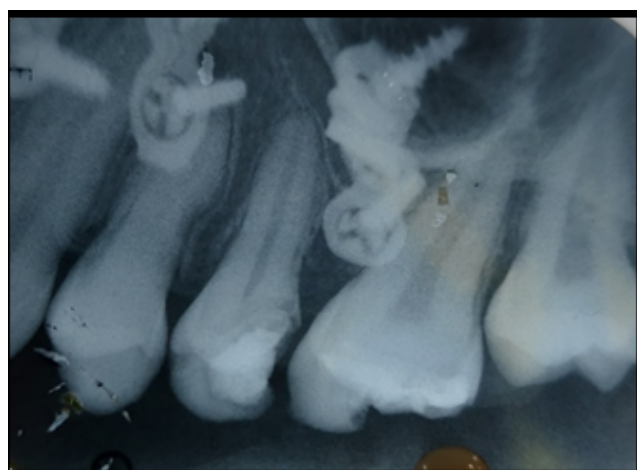
A 19-year-old female patient reported to department of conservative dentistry and endodontics with a chief complaint of pain in the upper right back tooth region for the past 3 months and got it severe for the last 3 days. Medical history revealed that she underwent facial reconstructive surgery 8 years ago. Carious right maxillary second molar (tooth #2) detected on clinical examination which was tender on percussion. Based on clinical and

\* Corresponding author.

E-mail address: [mariyamsanoonaabdulwaris@gmail.com](mailto:mariyamsanoonaabdulwaris@gmail.com) (M. S. Areekan).

radiographic findings chronic irreversible pulpitis of right maxillary second molar (#2) was diagnosed, which required endodontic management.

Conventional access and de roofing of the pulp chamber was completed using Endo access bur no 1 (Maillefer-Dentsply, Switzerland). Pulp tissue was extirpated with broaches and pulp chamber cleaned using 3% sodium hypochlorite. Canal patency was confirmed with #10 K file (Mani Inc.). Working length was assessed using Electric apex locator and obtained 19mm. Cleaning and shaping of tooth was completed using crown technique and enlargement was done up to size 40 master apical file. The canal was copiously irrigated with 3% sodium hypochlorite during instrumentation and a final rinse was done with 2ml saline followed with 3% NaOCl. Master cone was trial fit and the position was confirmed with a radiograph. All the canals were obturated with lateral condensation technique using zical sealer and accessory GP cones. GIC barrier was given and access cavity restored using composite restorative material. Patient was clinically asymptomatic on subsequent follow up.



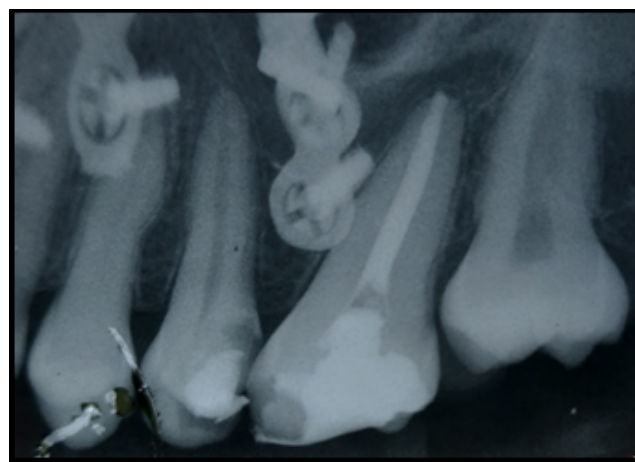
**Fig. 1:** Preoperative radiograph

### 3. Case Report 2

(Four rooted maxillary second molar)

A 14-year-old male patient referred to the same department with a chief complaint of pain in the upper right back tooth region while lying down for the last 3 consecutive nights. The pain increased in intensity from mild to severe, lasting for half an hour. A carious right maxillary second molar (tooth #2) detected on clinical examination, was tender on percussion. Based on clinical and radiographic examination, diagnosis of chronic pulpitis of the right maxillary second molar (#2) was made, which required endodontic therapy.

Radiographic evaluation of the affected tooth indicated a complex root canal anatomy with the roots overlapped each



**Fig. 2:** Postobturation radiograph

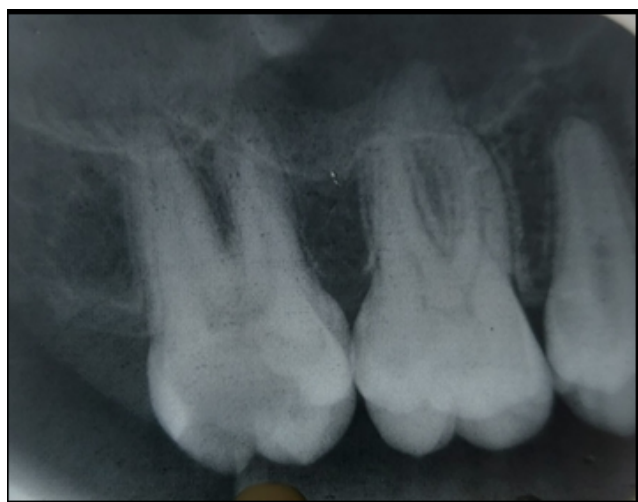other. Accurate radiographic assessment was difficult due to superimposition of the roots and canal anatomy was unclear. After rubber dam application conventional access opening done using diamond bur (No.4, MANI Inc.; Tochigi-Ken, Japan). Four canal orifices, two on each of the buccal and palatal canals, were confirmed by clinical examination of chamber floor.

Pulp tissue was extirpated using broaches and pulp chamber flushed with 3% sodium hypochlorite. Canal patency was confirmed using #10 K file (Mani Inc.). Working length was assessed using radiographic technique applying angles method and it was found to match with the readings obtained with Electric apex locator. Cleaning and shaping with protaper rotary system up to F2 completed using crown down technique. The canals were irrigated with 5.2% sodium hypochlorite during instrumentation and final rinse was done with 2ml saline. Master cone position was confirmed with a radiograph. Obturation of all the canals were completed with lateral condensation technique using zical sealer and accessory GP cones. The access was then restored with composite restorative material.

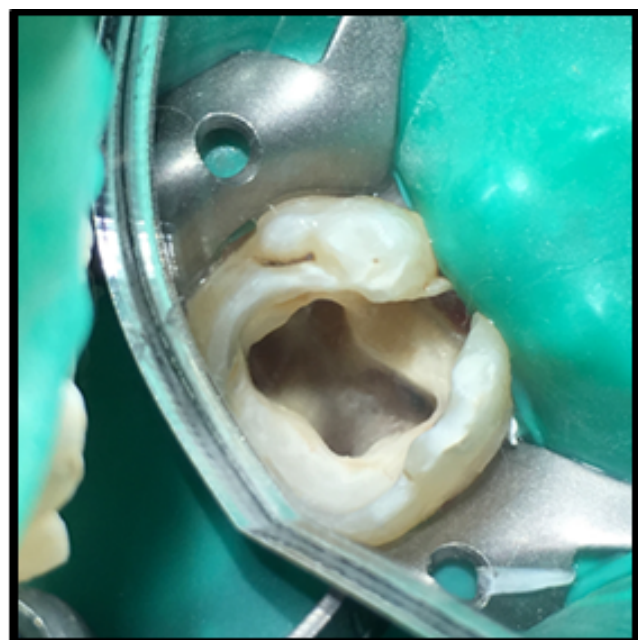
### 4. Discussion

PEIKOFF, et al<sup>9</sup> conducted a study on variations in the number of roots and canals in maxillary 2<sup>nd</sup> molar and six variants found in the study and their frequency of occurrence are as follows:

1. Three separate roots and three separate canals (56.9%).
2. Three separate roots and four canals (two in the mesiobuccal root) (22.7%)
3. Three roots and canals whose mesiobuccal and distobuccal canals combine to form a common buccal with a separate palatal (9%)



**Fig. 3:** Preoperative radiograph.

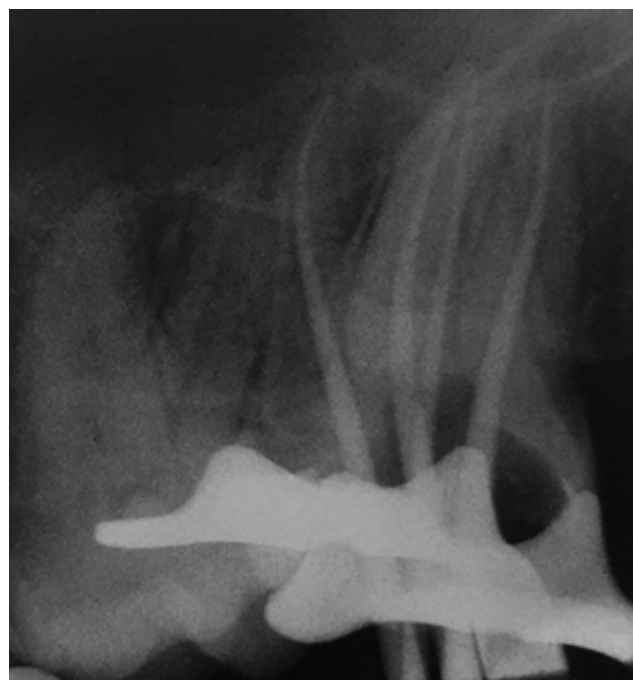

**Fig. 4:** Access opening of tooth #17.

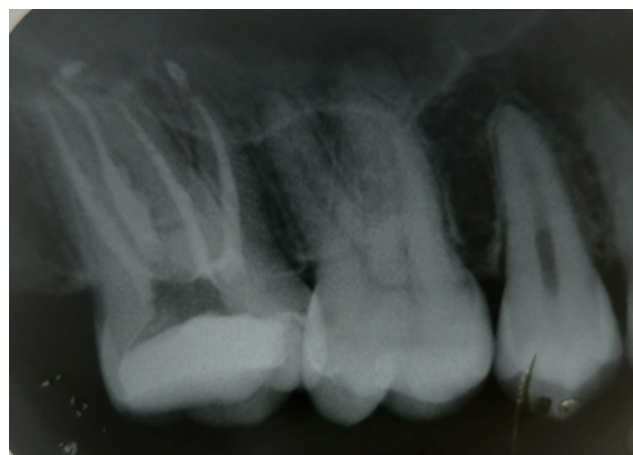4. Two separate roots with a single canal in each (6.9%)
5. One main root and canal (3.1%)
6. Four separate roots and four separate canals including two palatal (1.4%).<sup>9</sup>

A review article on the double palatal root by Christi et al<sup>10</sup> the highest occurrence of two palatal canals and double palatal roots (21/24 teeth) were found in the maxillary second molar tooth. The variation seemed to occur as three root anatomy types:

1. Type I, the two palatal roots being long and divergent. The buccal roots of these teeth are frequently "cow-horn" shaped and less divergent.



**Fig. 5:** Master cone radiograph of tooth #17.



**Fig. 6:** Postobturation radiograph of tooth #17.

2. Type II, the two palatal roots being shorter, nearly parallel and comparable to the two buccal roots.
3. Type III, variations of root fusion that included a two-canal system on the palatal aspect. The distobuccal root appears to stand alone.<sup>10</sup>

Libfeld and Rotstein examined the periapical radiographs of 200 maxillary second molars treated by 2 endodontists or dental students, just 1 tooth (0.5%) had 2 palatal roots. They likewise analysed periapical radiographs of 1000 maxillary second molars in 570 full mouth radiographs and found 4 (0.4%) had 2 palatal roots.<sup>11</sup>

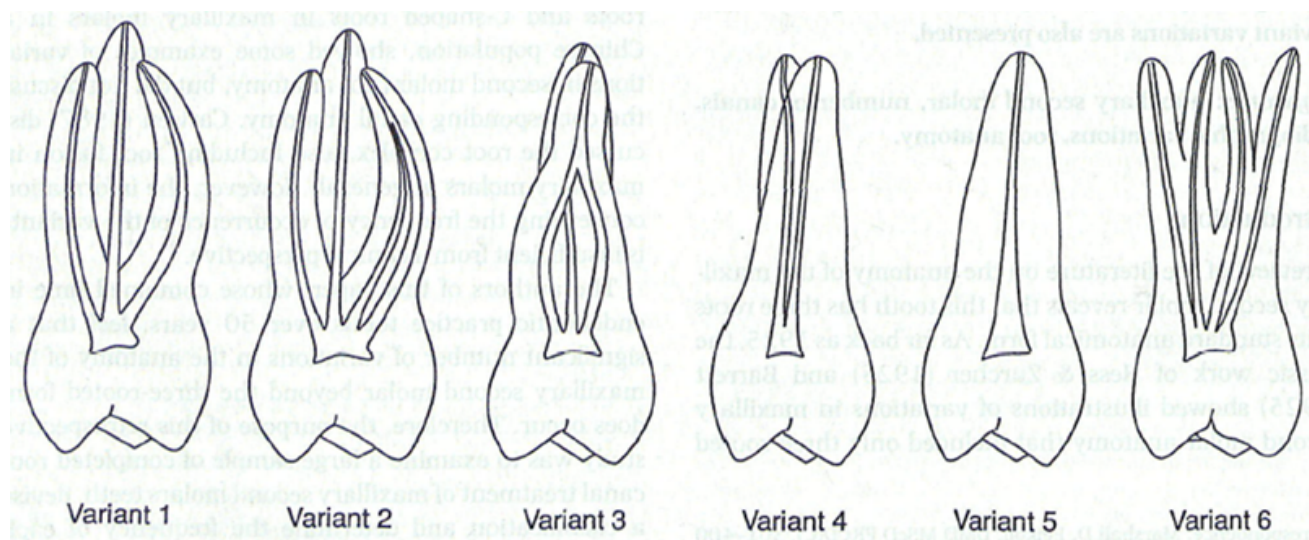


Fig. 7:

The Indian population is commonly viewed as a hybrid of several ethnic groups with Caucasian, Mongoloid, and Negroid qualities, commonly referred to as the Dravidian group. Neelakantan et al<sup>8</sup> conducted CBCT (Cone-Beam Computed Tomography) investigation of root and canal morphology of maxillary first and second molars in an Indian population and the outcome exhibited that the root number, morphology, and canal morphology of Indian maxillary molars differed from Caucasian and Mongolian traits. The result showed that the most widely recognized morphology was that of 3 separate roots in both the first (96.8%) and second molars (93.1%), first and second Single-rooted molars were identified in 0.9% of the studied samples. Four separate roots were found in 0.9% of the first molars, whereas no second molar had 4 roots.<sup>8</sup>

Shishir Singh et al<sup>12</sup> conducted a study on root canal morphology of south Asian Indian maxillary molar teeth and showed that seventy-two (72%) teeth had three separate roots, twenty-three (23%) had two separate roots and five (5%) teeth had a single root and none of the tooth showed an extra palatal root.<sup>12</sup>

## 5. Conclusions

Information on potential variations in the root canal anatomy of human teeth is critical for effective endodontic therapy. The maxillary second molar displays deviation and varieties in root canal numbers and its internal configurations. Likewise, the unpredictability of the root canal system, particularly in multi rooted teeth, increases with the presence of such variations. Utilizing newer imaging strategies can help in achieving an ideal endodontic treatment without flaw.

## 6. Source of Funding

None.

## 7. Conflict of Interest

None.

## References

- Malagnino V, Gallottini L, Passariello P. Some unusual clinical cases on root anatomy of permanent maxillary molars. *J Endod.* 1997;23(2):127–8.
- Gopikrishna V, Reuben J, Kandaswamy D. Endodontic management of a maxillary first molar with two palatal roots and a single fused buccal root diagnosed with spiral computed tomography - a case report. *Oral Surg Oral Med Oral Pathol Oral Radiol Endod.* 2008;105:74–8.
- Unusual Root Canal Morphology of the Maxillary Second Molar: A Case Report; 2019. Available from: <https://www.hindawi.com/journals/crid/2013/138239/abs/>.
- Zmener O, Peirano A. Endodontic therapy in a maxillary second molar with three buccal roots. *J Endod.* 1998;24(5):376–7.
- Ozcan E, Aktan AM, Ari H. A case report: Unusual anatomy of maxillary second molar with 3 mesiobuccal canals. *Oral Surg, Oral Med, Oral Pathol, Oral Radiol Endod.* 2009;107:e43–6.
- Kottoor J, Hemamalathi S, Sudha R, Velmurugan N. Maxillary second molar with 5 roots and 5 canals evaluated using cone beam computerized tomography: a case report. *Oral Surg Oral Med Oral Pathol Oral Radiol Endod.* 2010;109(2):e162–5.
- Zeng C, Shen Y, Guan X, Wang X, Fan M, Li Y, et al. Rare Root Canal Configuration of Bilateral Maxillary Second Molar Using Cone-beam Computed Tomographic Scanning. *J Endod.* 2016;42(4):673–7.
- Neelakantan P, Subbarao C, Ahuja R, Subbarao CV, Gutmann JL. Cone-Beam Computed Tomography Study of Root and Canal Morphology of Maxillary First and Second Molars in an Indian Population. *J Endod.* 2010;36(10):1622–7.
- Peikoff MD, Christie WH, Fogel HM. The maxillary second molar: variations in the number of roots and canals. *Int Endod J.* 1996;29(6):365–9.
- Christie WH, Peikoff MD, Fogel HM. Maxillary molars with two palatal roots: A retrospective clinical study. *Journal of Endodontics.*

1991;17(2):80–84. Available from: [https://dx.doi.org/10.1016/s0099-2399\(06\)81613-4](https://dx.doi.org/10.1016/s0099-2399(06)81613-4). doi:10.1016/s0099-2399(06)81613-4.

11. Nosrat A, Verma P, Hicks ML, Schneider SC, Behnia A, Azim AA, et al. Variations of Palatal Canal Morphology in Maxillary Molars: A Case Series and Literature Review. *J Endod*. 2017;43(11):1888–96.
12. Singh S, Pawar M. Root canal morphology of South Asian Indian maxillary molar teeth. *Eur J Dent*. 2015;9(1):133–44.

### Author biography

**M Ramesh Kumar** Professor and HOD

**Mariyam Sanoona Areekan** Post Graduate Student

**Elsy P Simon** Professor

**Chandini Raveendran** Senior Lecturer

**Amitha Krishna** Post Graduate Student

**Deepa Jayaraj** Post Graduate Student

**Cite this article:** Kumar MR, Areekan MS, Simon EP, Raveendran C, Krishna A, Jayaraj D. **Morphologic variations of roots and root canals in maxillary second molar: Case reports.** *IP Indian J Conserv Endod* 2020;5(2):92-96.