



Case Report

Endodontic retreatment of mandibular incisors with variable anatomy: A case report

Shreya Khanna^{1,*}

¹Dept. of Conservative Dentistry and Endodontics, DEIC, Guru Gobind Singh Hospital, Jamnagar, Gujarat, India



ARTICLE INFO

Article history:

Received 11-03-2020

Accepted 09-07-2020

Available online 07-09-2020

Keywords:

anatomy
endodontic retreatment
incisors
mandibular

ABSTRACT

Single rooted teeth are often considered as the easiest teeth to treat endodontically. Literature revealed several cases documenting single rooted tooth with anatomical variations. The present report is a unique case of two canals in all the mandibular incisors of same patient.

© 2020 Published by Innovative Publication. This is an open access article under the CC BY-NC license (<https://creativecommons.org/licenses/by-nc/4.0/>)

1. Introduction

Extensive knowledge of root canal morphology with diversities is extremely needed for victorious endodontic treatment. The basic principal to succeed in doing endodontic treatment can be easily achieved through adequate chemo- mechanical debridement along with filling the canal space completely in three-dimensional manner.¹ If there is any negligence by the operating endodontist in analysing the root canal anatomy or any possible complexities and anomalies, due to which there are further chances of inappropriate cleaning and shaping of the root canals which may lead to failure of whole treatment and will be needed endodontic retreatment in future.²

Several reports have been published earlier documenting the presence of extra canals in mandibular incisors. Research supported that more than 40% of mandibular incisors have two canals and in them more than 1% have two separate identifiable apical foramina.³

The present case report demonstrates the endodontic retreatment of mandibular central and lateral incisors and documenting the presence of two root canals in all the

mandibular incisors of the same patient.

2. Case Report

A 36-year-old female reported to the dental clinic with the chief complaint of pain in lower front region since one month. Patient had a history of trauma to the mandibular anterior region 10 years back and he took the treatment for the same. The medical history was non-contributory as no systemic disease was present. Clinical examination revealed a dislodged bridge with respect to lower central and lateral incisors, with associated pain on percussion. Radiographic examination with different angulations revealed inadequate root canal filling material and presence of periapical radiolucency wrt teeth #32–42 along with instrument separation seen wrt teeth #31 [Figure 1]. Nonsurgical root canal retreatment was planned as further treatment.

On observing the same radiograph, we found the presence of two root canals in 31,32,41,42, which is a rare morphological variation. Considering this an unusual observation additional radiographs at different angles were again taken for the symptomatic mandibular incisors after completion of treatment which also revealed two root canals in them.

* Corresponding author.

E-mail address: drshreyakl@gmail.com (S. Khanna).

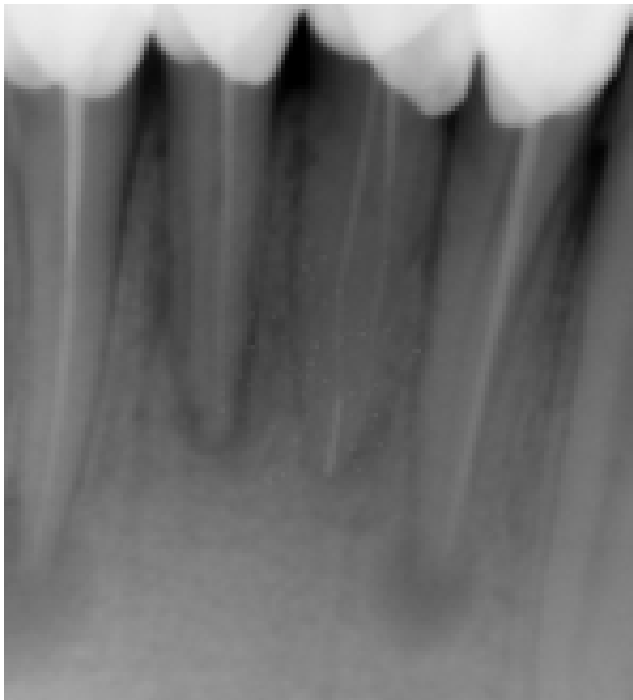


Fig. 1: Preoperative radiograph of teeth (#32,31,41,42) with inadequate root canal treatment, periapical radiolucency, and instrument separation seen #31

Clinical preview of symptoms, faulty obturation and periapical pathology suggested endodontic retreatment for teeth 31,32,41,42 and we planned accordingly. All coronal restorations were removed.

The teeth were isolated with rubber dam, the access cavities were modified and the previously condensed guttapercha points were softened with guttapercha solvent (septodont) and removed using K and H files alternatively [figure 2]. Careful exploration of the root canals revealed two separate canals, buccally and lingually in both the teeth with vertucci type IV morphology of root canals. Working length was established and verified both radiographically and using apex locator (J Morita).

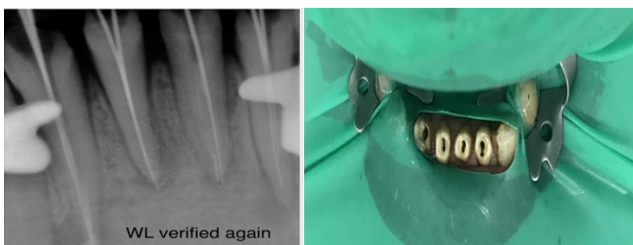


Fig. 2: Radiograph of working length showing two different instruments in two canals of teeth (#32,31,41,42), and photograph showing two canals in each tooth

The canals were prepared using a crown down instrumentation technique. 5.5% of sodium hypochlorite and normal saline (sodium chloride injection I.P 0.9% w/v core health care limited) were alternatively used as irrigants at every change of instrument. File couldn't be retrieved (with the risk of pushing it beyond the apex) so thorough irrigation protocol was followed. The canals were dried with sterile paper points and were dressed with calcium hydroxide paste (pulpdent) [figure3].

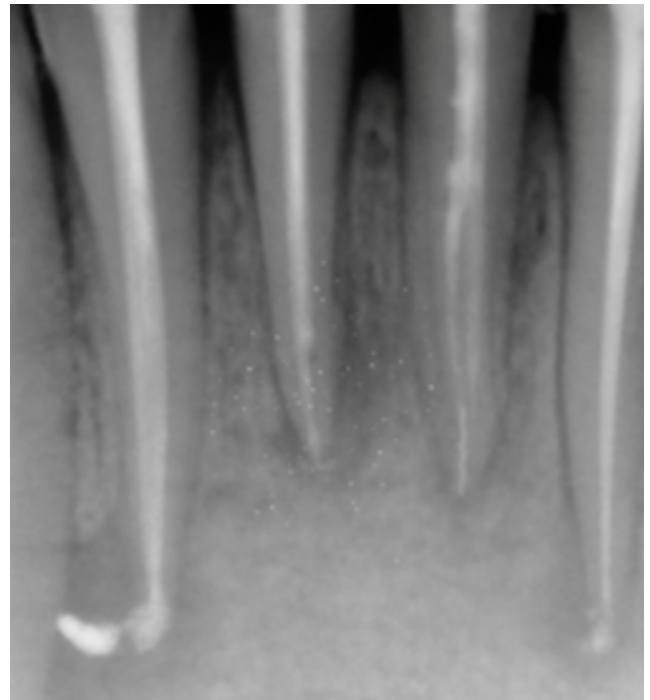


Fig. 3: Calcium hydroxide dressing placed for 2 weeks

The access cavities were then temporarily sealed with IRM. After 2 weeks follow up, the teeth were checked and they were found asymptomatic, therefore further obturation of the root canals with gutta-percha using lateral condensation technique was done. Post obturation radiograph showed well obturated 2 canals in all lower incisors and the access cavities were sealed with IRM. The patient was followed up at regular interval of 1, 3, and 6 months respectively.

3. Discussion

Dr. Hermann Prinze wrote “Object of the clinical dentistry is to institute preventive measures to relieve suffering, and to cure disease. To gain this goal clinician should have sound knowledge of dental anatomy, differential diagnostic modulates.”⁴ Presence of accessory root canals should be detected to avoid failure of endodontic treatment.⁵ Improper cleaning of root canals may increase the possibility of treatment failure.^{6,7} A common reason for

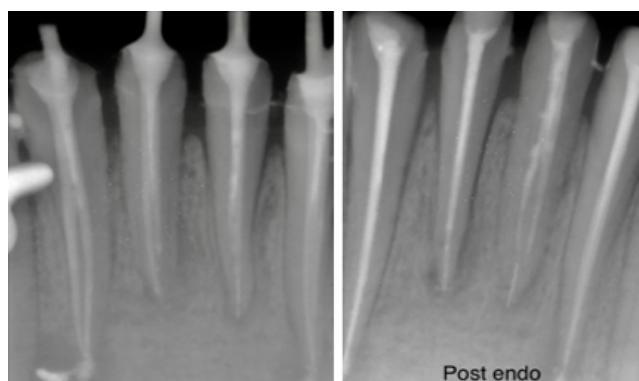


Fig. 4: Master cone and post obturation radiographs

not locating a second canal in mandibular incisors is an inadequate access opening into the tooth that leaves a lingual shelf of dentine over the second (usually the lingual) canal.⁸ Therefore, it may be necessary to modify the conventional access preparation to permit better visualization and instrumentation of additional canal even at the emphasis of compromising the crown structure.⁹

Numerous antimicrobial agents have been recommended as inter appointment dressings.^{10,11} Calcium hydroxide paste being one of the simplest and remarkably effective antimicrobial medicament was used in this case.

The present case report demonstrates the root canal retreatment for all mandibular incisors, each with 2 separate canals merging in a single foramina.

4. Conclusion

The basic cause for failure of endodontic treatment of mandibular incisors in the reported case was inability to detect secondary unusual lingual canals which are definitely difficult to diagnose. For such cases, we need a complete knowledge of root canal anatomy and morphology and additional radiographs should be taken at different angles for interpretation to be more precise. As the advancement in endodontic techniques is available, therefore such kind of teeth with complex root canal complexities can be easily treated without any surgical intervention.

5. Source of Funding

None.

6. Conflict of Interest

None.

References

1. Vertucci FJ. Root canal morphology and its relationship to endodontic procedures. *Endod Top.* 2005;10(1):3-29.
2. Kabak YS, Abbott PV. Endodontic treatment of mandibular incisors with two root canals: Report of two cases. *Aust Endod J.* 2007;33(1):27-31.
3. Carrotte P. Endodontics: Part 4 Morphology of the root canal system. *Br Dent J.* 2004;197(7):289-367.
4. Hargreaves K. Cohen's Pathways of the Pulp. Mosby-Year Book, Inc; 2011. p. 2-4.
5. Slowey RR. Radiographic aids in detection of extra root canals. *Oral Surg Oral Med Oral Pathol.* 1974;37:762-71.
6. Nair R, Sjogren U, Kreg G, Khanberg KE, Sandquist G. Intraradicular bacteria and fungi in root filled asymptomatic human teeth with therapy resistant periapical lesion- a long term light and electron microscope follow up study. *J Endod.* 1990;16:580-8.
7. Sjogren U, Hagglund B, Sundquist G, Wing K. Factors affecting the long term results of endodontic treatment. *J Endod.* 1990;16:498-504.
8. Miyashita M, Kasahara E, Yasuda E, Yamamoto A, Sekizawa T. Root canal system of the mandibular incisor. *J Endod.* 1997;23(8):479-84.
9. Slowey RR. Root canal anatomy. Road map to successful endodontics. *Dent Clin North Am.* 1979;23(4):555-73.
10. Bystrom A, Claesson R, Sundqvist G. The antibacterial effect of camphorated paramonochlorophenol, camphorated phenol and calcium hydroxide in the treatment of infected root canals. *Dent Traumatol.* 1985;1(5):170-5.
11. Hasselgren G, Olsson B, Cvek M. Effects of calcium hydroxide and sodium hypochlorite on the dissolution of necrotic porcine muscle tissue. *J Endod.* 1988;14(3):125-7.

Author biography

Shreya Khanna Dental Officer

Cite this article: Khanna S. Endodontic retreatment of mandibular incisors with variable anatomy: A case report. *IP Indian J Conserv Endod* 2020;5(3):120-122.