



Case Report

Management of c-shape root canal configuration: Case reports

Nirmala Bishnoi^{1,*}, Ida de Noronha de Ataide², Marina Fernandes², Rajan Lambor²,
Bobbil Sandhu¹

¹Dept. of Conservative Dentistry and Endodontics, Vyas Dental College and Hospital, Jodhpur, Rajasthan, India

²Dept. of Conservative Dentistry and Endodontics, Goa Dental College, Goa, India



ARTICLE INFO

Article history:

Received 09-06-2020

Accepted 24-07-2021

Available online 07-09-2020

Keywords:

Anatomic variation

Cshaped canal

Mandibular second molars

Endodontic treatment

Thermoplasticized obturation

ABSTRACT

Unusual root canal anatomy always poses a diagnostic and treatment challenge. Therefore a thorough knowledge of root canal anatomical variations along with proper diagnosis, treatment planning and clinical expertise is the key to their successful management. The C-shaped root canal configuration is one such aberrant canal anatomy, common in the mandibular second molar. It often goes undetected and due to the intricate root canal configuration, it is often difficult to negotiate, debride and obturate such canals leading to failure of root canal treatment.

Case Reports: This article presents management of four different C-shape root canal configurations using the cold lateral condensation and thermoplasticized obturation techniques.

Conclusion: Understanding the anatomical presentations of this variation will enable the clinician to manage these cases effectively. Advanced irrigation and obturation techniques help in managing such anomalous canal configurations.

© 2020 Published by Innovative Publication. This is an open access article under the CC BY-NC license (<https://creativecommons.org/licenses/by-nc/4.0/>)

1. Introduction

C-shaped canal anatomy was first documented by Cooke and Cox in mandibular second molar in 1979, though Weine et al reported that several clinicians had suggested its presence in lectures earlier.¹ This type of Canal configuration has a high prevalence in mandibular second molars (2.7% - 45.5%)²⁻⁵ and has also been reported in maxillary first molars (0.12%), maxillary third molars (4.7%), mandibular third molars (3.5% - 4%) and mandibular second premolars (1%).⁶⁻⁹ It has been found that there is no correlation of C-shaped canal configuration with gender and also with age and tooth position but ethnic variation is found with highest frequency being reported in the East Asian population groups like Chinese population (29.7%) and Koreans (31.3%-45.5%).¹ The definition of the C-shaped root canal system is that the morphology of its horizontal cross section is in the form of a C, with canals

which may or may not be separate.¹⁰

This anatomical variation results from the failure of Hertwig's epithelial sheath to develop or fuse in the furcation area in the developing stage of the teeth.²

Fan et al modified Melton's method into the following categories (Figure 1)

1. Category I (C1): interrupted "C" with no separation or division.
2. Category II (C2): resembled a semicolon resulting from a discontinuation of the "C" outline, but either angle α or β should be no less than 60° .
3. Category III (C3): 2 or 3 separate canals and both angles, α and β less than 60° .
4. Category IV (C4): Only one round or oval canal in the cross-section.
5. Category V (C5): No canal lumen could be observed (which is usually seen near the apex only)

C-shaped canal poses diagnostic difficulty radiographically because of the two-dimensional view of the radiograph.

* Corresponding author.

E-mail address: nbishnoi21@gmail.com (N. Bishnoi).

The presence of thin fin, slit and web create difficulty in the canal shaping, thorough debridement and obturation. Irregular areas in a C-shaped canal that may house soft-tissue remnants or infected debris may escape through cleaning or filling and may be a source of bleeding and severe pain.¹¹ Therefore, it is imperative to select the correct obturation technique to obturate C-shape canal. This report presents the management of C-shaped mandibular molar teeth with different obturation systems.






C1		The shape is an uninterrupted "C" with no separation or division
C2		The canal shape resembles a semicolon resulting from a discontinuation of the "C" outline, but either angle α or β should be no less than 60°
C3		Two or three separate canals and both angles, α or β are less than 60°
C4		Only one round or oval canal in that cross-section
C5		No canal lumen can be observed (which is usually seen near the apex only)

Fig. 1: Fan et al's anatomic classification of C-shaped canal configuration

2. Case Reports

3. Case 1

A 35 year old female patient reported to the department of Conservative Dentistry and Endodontics with a chief complaint of pain in lower right back tooth. Medical history was non-contributory. Intra oral examination revealed fractured restoration with respect to #47 and tenderness to percussion. Radiographically, the tooth was conical in shape with fused mesial and distal root with a thin radiolucent line between them, with a suspected C-shaped canal and improper obturation with periapical radiolucency suggestive of periapical abscess/periapical granuloma (Figure 2 a). Re endodontic treatment was planned and explained to the patient. After proper isolation and anesthesia, fractured restoration was removed and guttapercha removal was performed using rotary and hand H-files, following which Fan et al's C3 type canal anatomy was found. After working length determination, canal was prepared with ProTaper rotary files (Dentsply Maillefer, Switzerland) up to F2 followed by circumferential filing with hand K files. 5% sodium hypochlorite (Acrylates, India) was used for irrigation which was activated using Endo activator (Dentsply Maillefer, Switzerland) and calcium hydroxide dressing was given as an intracanal medicament. The patient was recalled after 2 weeks and was sign and symptom free; obturation was then completed with thermoplasticized

gutta-percha (Calamus, Dentsply Maillefer, Switzerland) and post-endodontic restoration done using composite resin (Figure 2c,d).

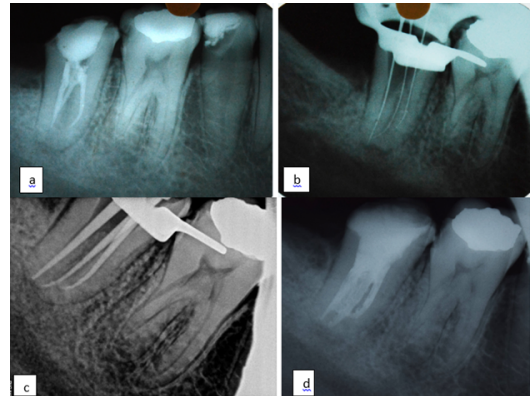


Fig. 2: a-d

4. Case 2

A 24 year old female patient reported to the department with a chief complaint of pain on eating food in lower right back tooth. The medical history was non-significant. Intraoral examination revealed carious # 47 with tenderness on percussion. Radiographically, a large occluso-proximal radiolucency was seen in tooth 47 closely approximating the pulp space along with an associated widening of periodontal ligament space (Figure 3 a). Tooth was conical in shape with fused mesial and distal roots. Cold test using cold spray and Electric pulp testing gave negative response. The tooth was diagnosed with necrotic pulp with acute apical periodontitis. Root canal treatment was planned and explained to the patient. After proper isolation and anesthesia, an access cavity was prepared and Fan et al C1 type canal anatomy was found. After working length determination, canal was prepared with ProTaper rotary files (Dentsply Maillefer, Switzerland) up to F3 followed by circumferential filing with hand K files. 5% sodium hypochlorite (Acrylates, India) was used as an endodontic irrigant which was activated with Endo activator (Dentsply Maillefer, Switzerland) (Figure 3b). Calcium hydroxide (RC Cal Prime Dental Products, Thane, India) was placed as an intracanal medicament. After 1 week, patient was recalled and obturation was done using thermoplasticized gutta-percha (Calamus, Dentsply Maillefer, Switzerland). Post endodontic restoration with composite was done (Figure 3c,d).

5. Case 3

A 27 year old female patient reported to the department with the chief complaint of boil with respect to lower left back tooth. Medical history was non-contributory.

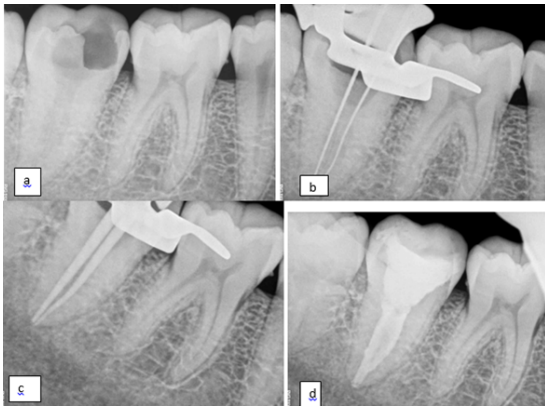

Fig. 3: a-d

Intraoral examination revealed amalgam restored #37 and associated draining sinus. The tooth was tender on percussion. Radiographically the tooth was conical in shape with fused mesial and distal root with a thin radiolucent line between them, with suspected C-shaped canal and improper obturation with periapical radiolucency suggestive of periapical abscess (Figure 4 a). Re-root canal treatment was planned and explained to the patient. After proper isolation and anesthesia, amalgam restoration was removed and Gutta percha removal was performed with the help of rotary files and hand H-files. Working length was determined after locating two separate canals (Fan et al C2 type anatomy) in the pulp chamber floor (Figure 4b). Canals were prepared with ProTaper rotary file system (Dentsply, Maillefer) upto F2 and 5% sodium hypochlorite (Acrylates, India) was used as an endodontic irrigant. Calcium hydroxide (RC Cal Prime Dental Products, Thane, India) was placed as an intracanal medicament. Patient was recalled after 15 days and the calcium hydroxide dressing was replaced. After the next 15 days patient was sign and symptom free so obturation was carried out using thermoplasticized gutta-percha (Calamus, Dentsply Maillefer, Switzerland) and post endodontic restoration was done with composite resin (Figure 4c,d).

6. Case 4

A 29 year old female patient reported to the department with a chief complaint of pain on eating food in lower right back tooth. No relevant medical history. Intraoral examination revealed carious # 47 with tenderness on percussion. Radiographically, a proximal radiolucency was seen in tooth 47 closely approximating the pulp space along with an associated widening of periodontal ligament space (Figure 5 a). Tooth was conical in shape with fused mesial and distal roots and a thin radiolucent line between them, with a suspected C-shaped canal. After proper isolation and anesthesia, an access cavity was prepared and Fan et al C3 type canal anatomy was found. After working

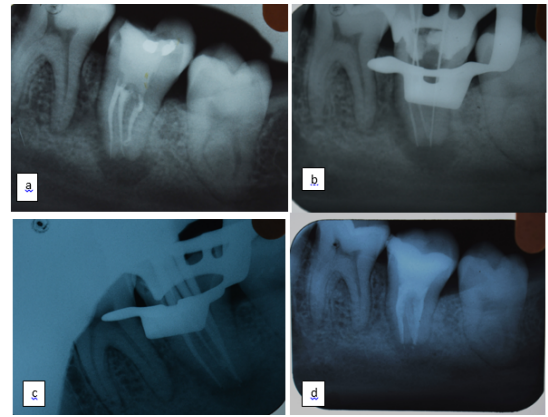


Fig. 4: a-d

length determination (Figure 5b), cleaning and shaping was done with ProTaper rotary files (Dentsply Maillefer, Switzerland) up to F3 followed by circumferential filing with hand K files (Dentsply Maillefer, Switzerland). 5% sodium hypochlorite (Acrylates, India) was used as an endodontic irrigant which was activated with Endo activator (Dentsply Maillefer, Switzerland). Calcium hydroxide (RC Cal Prime Dental Products, Thane, India) was placed as an intracanal medicament. After a week patient was recalled, radiograph was taken to confirm fit of the master cone and obturation was completed using thermoplasticized gutta percha (Calamus, Dentsply Maillefer, Switzerland) and post endodontic restoration was done with composite resin (Figure 5c,d).

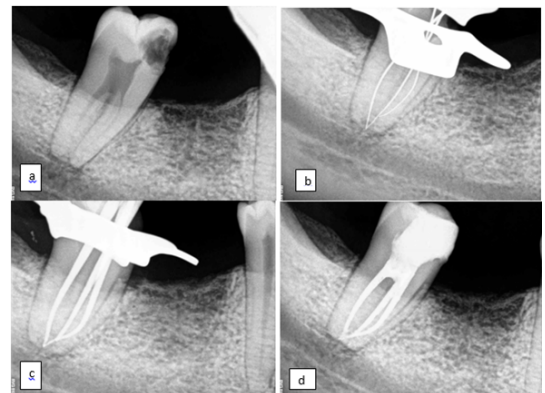


Fig. 5: a-d

7. Discussion

The etiology for C-shaped morphology is failure of the Hertwig's epithelial root sheath to fuse on the lingual or buccal root surface. The C-shaped root may also be formed by coalescence because of deposition of the cementum with time.²

Melton et al's classification describes the following three types of C shaped canals continuous C shaped (C1), semicolon (C2) and separate canals (C3). This classification was further modified by Fan et al and the most prevalent type of C shape canal was single orifice with an uninterrupted "C" shape configuration according to this classification.³

Following features are a must for the canal morphology to be called as "C" shape:

1. Fused roots,
2. A longitudinal groove on the lingual or buccal surfaces of the root,
3. At least one cross-section of the canal belongs to the C1, C2, or C3 configuration.¹²

Management of this type of canal configuration is a highly challenging task for a clinician. However, with the advent of newer technical advancements in the form of Cone beam CT scan, Operating microscopes, sonic, ultrasonic irrigation devices and thermoplasticized obturation techniques successful management of this anatomical aberration has been achieved.

Points to be considered in management of C shaped canal morphology:

1. Preoperative radiograph will show fused roots so additional 20° mesial or the distal angulation will be useful to deduct this configuration.
2. Isthmus preparation should be restricted till no 25 file and anti-curvature filing is recommended to avoid strip perforations. Avoid use of Gates-Glidden drills for the same.
3. Irrigation supplemented with ultrasonic agitation is the key to success as it would clean the inaccessible areas of the complex "C" shape anatomy.
4. To ensure proper placement of the master cones in C-shaped canals, Walid's technique involves placing the master points simultaneously in the C-shaped canal. A large plugger is placed on one of the sealed master points while the other master point is down packed with a smaller plugger.¹³
5. Thermoplasticized obturation technique is preferred as it ensures a better 3 dimensional fill than cold lateral compaction technique.

8. Conclusion

The C-shaped root canal configuration has an ethnic predilection and a high prevalence rate in mandibular second molars. For successful endodontic management proper diagnosis, sound knowledge about aberrant root canal anatomy, a thorough chemo-mechanical preparation with a 3-dimensional obturation of C-shaped canals is essential to ensure a good long term prognosis.

9. Source of Funding

None.

10. Conflict of Interest

None.

References

1. Fernandes M, Ataide ID, Wagle R. C-shaped root canal configuration: A review of literature. *J Conserv Dent*. 2014;17:p. 312-9.
2. Manning SA. Root canal anatomy of mandibular second molars. Part II: C shaped canals. *Int Endod J*. 1990;23:40-5.
3. Fan B, Cheung GS, Fan M, Gutmann JL, Bian Z. C-shaped Canal System in Mandibular Second Molars: Part I—Anatomical Features. *J Endod*. 2004;30(12):899-903.
4. Gulabivala K, Opananon A, Ng YL, Alavi A. Root and canal morphology of Thai mandibular molars. *Int Endod J*. 2002;35(1):56-62.
5. Jin GC, Lee SJ, Roh BD. Anatomical study of C-shaped canals in mandibular second molars by analysis of computed tomography. *J Endod*. 2006;32:10-3.
6. Sidow SJ, West LA, Liewehr FR, Loushine RJ. Root canal morphology of human maxillary and mandibular third molars. *J Endod*. 2000;26:p. 6758.
7. Yu X, Guo B, Li KZ, Zhang R, Tian YY, Wang H. Conebeam computed tomography study of root and canal morphology of mandibular premolars in a western Chinese population. *BMC Med Imaging*. 2012;12:18.
8. Kuzekanani M, Haghani J, Nosrati H. Root and canal morphology of mandibular third molars in an Iranian population. *J Dent Res Dent Clin Dent Prospects*. 2012;6:858.
9. Cleghorn BM, Christie WH, Dong CC. Root and root canal morphology of the human permanent maxillary first molar: A literature review. *J Endod*. 2006;32:813-21.
10. Vieira MVB, Vieira MM, Pileggi R. C-shaped canal": an anatomical variation. *RBO*. 1998;55(4):204-8.
11. Elumalai D, Kumar A, Tewari RK, Mishra SK, Iftekhar H, Andrabi SM, et al. Management of C-shaped root canal configuration with three different obturation systems. *Eur J Gen Dent*. 2015;4(1):25-8.
12. Yadav K, Ataide IDND, Fernandes M, Lambor R. Management of C shaped canals: 3 case reports. *Int J Contemp Med Res*. 2016;3(5):1340-2.
13. Walid N. The use of two pluggers for the obturation of an uncommon C shaped canal. *J Endod*. 2000;26:4224.

Author biography

Nirmala Bishnoi Senior Lecturer

Ida de Noronha de Ataide Professor and HOD

Marina Fernandes Assistant Professor

Rajan Lambor Assistant Professor

Bobbin Sandhu Reader

Cite this article: Bishnoi N, Ataide IN, Fernandes M, Lambor R, Sandhu B. **Management of c-shape root canal configuration: Case reports.** *IP Indian J Conserv Endod* 2020;5(3):131-134.