



## Case Report

# Demystifying anatomical variations – Endodontic therapy of twin rooted mandibular canine with concomitant root canals: An unusual case report

Kishan Agarwal<sup>1</sup>, Praveen Singh Samant<sup>1</sup>, Vipul Srivastava<sup>1</sup>, Gaurav Jain<sup>1,\*</sup>

<sup>1</sup>Dept. of Conservative Dentistry & Endodontics, Saraswati Dental College, Lucknow, Uttar Pradesh, India



## ARTICLE INFO

### Article history:

Received 29-08-2020

Accepted 05-09-2020

Available online 07-09-2020

### Keywords:

Endodontic therapy

Mandibular canine

Root canal anatomy

Root canal variations

Two roots

## ABSTRACT

The precise knowledge of endocanalicular systems of different human teeth is a "road map" for the successful root canal treatment. Permanent mandibular canines usually contain one root with a single root canal. Many investigators have reported the anatomical variations associated with mandibular canines. This paper describes case of root canal therapy of permanent mandibular canine having two roots and two root canals (Type IV, Weine's Classification). The clinicians must always suspect anatomical varieties and use all the available tools to diagnose and manage the cases.

© 2020 Published by Innovative Publication. This is an open access article under the CC BY-NC license (<https://creativecommons.org/licenses/by-nc/4.0/>)

## 1. Introduction

Root canal morphology plays an essential role in determining the conditions under which the endodontic treatment can be performed effectively with a successful outcome.<sup>1</sup> In addition to knowledge of morphology, proper diagnosis, meticulous cleaning & shaping, and further filling the root canals resulting in a three dimensional obturation are prerequisites for successful endodontic therapy. Failure in doing any of it may lead to postoperative diseases, pain and further complications.<sup>2</sup> Both coronal and radicular cohorts flow together in a single preparation during endodontic treatment. A tooth having canal with graceful tapering and a single apical foramen is more of an exception rather than a rule. Investigators have shown the presence of multiple foramina, deltas, accessory canals, etc. in most of the teeth.<sup>3,4</sup>

Generally, mandibular canines contain a single root and canal.<sup>1</sup> The anatomical variations associated with permanent mandibular canines have been reported by several investigators. Pineda and Kuttler,<sup>5</sup> Green,<sup>6</sup> and

Vertucci,<sup>7</sup> reported that the occurrence of mandibular canines with one root and two root canals is approximately 15%. Few studies have already reported 5% incidence of mandibular canines having two roots and two canals.<sup>8,9</sup>

Every clinician should be aware of anatomical variations, and should never misunderstand root canals as same and simple. This paper reports successful management of a mandibular canine with two roots and two canals.

## 2. Case Report

A 40 years old male patient with a non-significant medical history reported in the Department of Conservative Dentistry and Endodontics, Saraswati Dental College, Lucknow, with chief complaint of severe pain in right mandibular anterior region since past three weeks. Clinical examination and testing revealed distal cervical deep caries involving pulp of tooth #43 with positive tenderness to percussion. Pulp vitality tests showed negative results. The tooth was rotated distally. Intraoral periapical radiographs in different angulations were taken which revealed proximal caries involving the pulp of tooth #43 along with two roots and two canals & periapical pathology involving

\* Corresponding author.

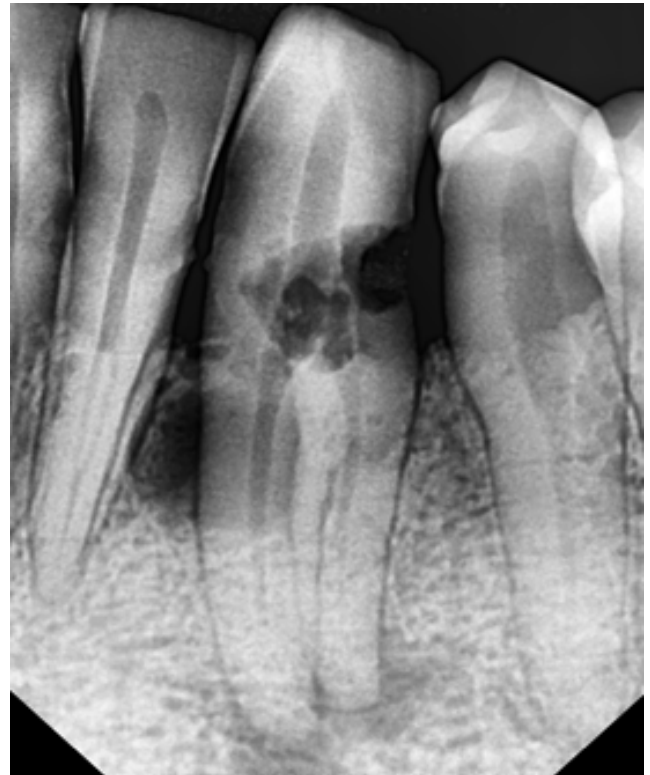E-mail address: [gauravjs23@yahoo.com](mailto:gauravjs23@yahoo.com) (G. Jain).

both the roots.(Figure 1) The periodontal examination (CP 12 periodontal probe, Hu Friedy) showed the presence of a periodontal pocket with a probing depth of 4mm. No abnormal findings were seen during extra oral examination. A clinical diagnosis of acute apical abscess was made and root canal therapy was planned after obtaining patient's consent.


All treatments were performed under an overhead light source and magnification 2.5x loupes. In the first appointment, after administration of local anesthesia of 2% Lidocaine with 1:200000 epinephrine (Neon, India) using an aspirating syringe, the tooth was isolated using rubber dam (Hygienic Dental Dam, Coltène/Whaledent Inc.,Cuyahoga Falls, USA). Pre-endodontic build-up was done with composite resin to prevent contamination. The access opening was prepared with an endo access #1 round diamond bur and endo-Z tapered safe-end bur access cavity (Dentsply Maillefer, Ballaigues, Switzerland). After removing coronal pulp, with the use of DG-16 endodontic explorer, we found that there were two canal orifices situated in labial and lingual direction.(Figure 2) This finding was not same from the usual anatomy where single orifice is commonly located in the center of the crown/root. K file of sizes 6, 8 and 10 (Dentsply Maillefer, Ballaigues, Switzerland) were used for creating the glide path. Working length was determined with 15 K file using an electronic apex locator (Root ZX J Morita Corp; Kyoto, Japan) & later verified radiographically to prevent over instrumentation.(Figure 3) Canal preparation was performed with manual hand k-files and Protaper rotary Ni-Ti instruments according to manufacturer instructions (Dentsply Maillefer, Ballaigues, Switzerland). After each file, the canals were irrigated with 5.25% sodium hypochlorite and 17% ethylene diaminetetraacetic acid (EDTA). The root canals were dried with sterile paper points and obturated with matching gutta percha cones and AH-Plus (Dentsply, Ballaigues, Switzerland) sealer using the cold lateral compaction technique.(Figure 4) The tooth was then coronally sealed with the temporary filling material (Cavit;3MESPE AG, Seefeld, Germany). After 1 week, patient reported asymptotically and temporary filling was replaced with Z350 composite resin (3MESPE AG, Germany).

### 3. Discussion

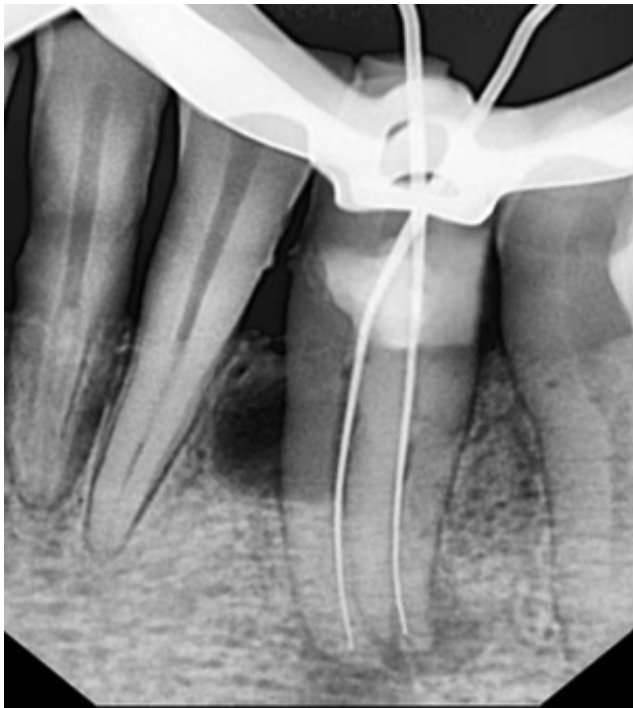It is important to recognize the possible permutations of canal morphology in endodontic therapy. Morphologically, permanent mandibular canines are usually mono-radicular in humans.<sup>1</sup> Some atypical findings like, two root canals, one or two roots with three canals; as well as two roots and two canals have been reported.<sup>2,10-13</sup> Heling I et al. reported a case of mandibular canine with two roots and three radicular canals.<sup>14</sup> There is also evidence of even three canals with only two apices,<sup>15</sup> and of two



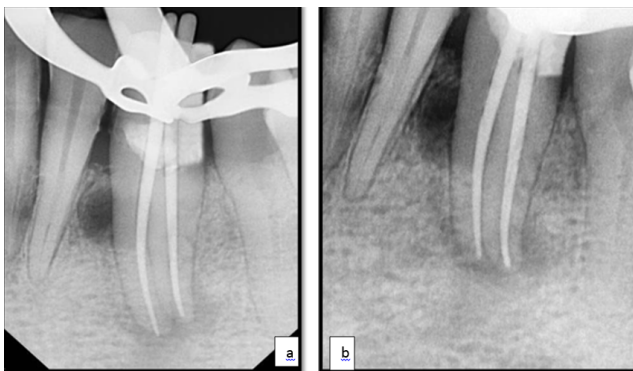
**Fig. 1:** Diagnostic radiograph showing two separate roots with dental caries and pathology wrt #43.



**Fig. 2:** Buccal and lingual canals seen after access opening wrt #43.



**Fig. 3:** Working length estimation with k file wrt #43.



**Fig. 4:** Radiograph showing root canals obturated with gutta percha and post endodontic restorations coronally wrt #43.

roots with two separate canals present.<sup>16</sup> The clinician must be mindful of variations in root canal anatomy from the beginning of the treatment until its completion because endodontic treatment becomes technically difficult when unexpected complexity is found in root canal.<sup>11</sup> Although the main etiology of this variation is unknown, a disturbance in the development of Hertwig's epithelial root sheath and consequent formation of a horizontal flap is construed.<sup>17</sup> This case reports successful management of a mandibular canine with two roots and two canals.

It is crucial to carefully inspect the diagnostic radiographs; it is helpful to be aware of the importance of detection of a sudden loss in the continuity of the root canal lumen or a radiolucent groove in the lateral

part of the root, which are findings, that hint to the presence of more than one canal.<sup>18</sup> Radiographs taken in different horizontal angulations helps in better visualization of the canals. SLOB (Same Lingual Opposite Buccal) also known as tube shift/buccal object rule/Clark's Rule can be employed to better visualize the radicular morphology.<sup>19</sup> In the current case, X-ray tube was projected at  $-30^\circ$  and the second projection was altered  $10^\circ-15^\circ$  mesially. Despite the use of these techniques for taking an intraoral periapical radiograph, there may be a chance of superimposition, distortion, foreshortening or elongation of the resultant image.<sup>19</sup> These shortcomings were overcome with the invent of cone beam computed tomography (CBCT), which accurately determine the number of roots, curvatures, and bifurcations in both sagittal and axial planes.<sup>20</sup> Moreover, use of magnification tools (magnification loupes or DOM), the use of fiber optics, and soap bubble test/champagne test might help to locate any additional canal orifices.<sup>21</sup>

#### 4. Conclusion

Knowledge of the internal anatomy of the tooth is as important as diagnosis and treatment planning of the tooth for its long term success. Our population has some complex root canal structures, dimensions and alterations of canal anatomy which should be taken care of. Although the probability of permanent mandibular canine having extra roots and root canals is infrequent, the clinicians should be appraised about it. Careful interpretation of conventional radiographs with different angulations and use of advanced radiographic tools such as CBCT, appropriate access cavity design to visualize the entire pulp chamber floor as well as the use of magnifying tools are helpful to evaluate complex root canal anatomy.

#### 5. Acknowledgement

I acknowledge all the faculties, supporting staffs from the Department of Conservative Dentistry and Endodontics, Saraswati Dental College, Lucknow for their support in treating the patients and encouraging me to document and write this case report.

#### 6. Source of Funding

None.

#### 7. Conflict of Interest

None.

#### References

1. Arora V, Nikhil V, Gupta J. Mandibular canine with two root canals-an unusual case report. *Int J Stomatol Res.* 2013;2(1):1–4.
2. Alenezi MA, Al-Hawwas AY. Permanent mandibular canine with two roots and two root canals: Two case reports. *Saudi Endod J.* 2016;6(2):98–100.

3. Dexton AJ, Kumar MR, Arundas D, Shoba K. Retreatment of maxillary lateral incisor with supernumerary root. *J Conserv Dent*. 2011;14(3):322–4.
4. Hasan A, Khan JA. Combined Endodontic and Surgical Management of Twin Rooted Maxillary Lateral Incisor with a Palatogingival Groove. *Iran Endod J*. 2018;13(3):413–19.
5. Pineda F, Kuttler Y. Mesiodistal and buccolingual roentgenographic investigation of 7,275 root canals. *Oral Surg, Oral Med, Oral Pathol*. 1972;33(1):101–10.
6. Green D. Double canals in single roots. *Oral Surg Oral Med Oral Pathol*. 1973;35:689–96.
7. Vertucci FJ. Root canal anatomy of the human permanent teeth. *Oral Surg, Oral Med, Oral Pathol*. 1984;58(5):589–99.
8. Ouellet R. Mandibular permanent cuspids with two roots. *J Can Dent Assoc*. 1995;61:159–61.
9. Pecora JD, Neto MDS, Saquy PC. Internal anatomy, direction and number of roots and size of human mandibular canines. *Braz Dent J*. 1993;4:53–7.
10. Kulkarni NR, Kamat SB, Hugar SI, Nanjannawar GS. Mandibular canine with two roots and two root canals—a rare case. *J Clin Diagn Res JCDR*. 2016;10(9):10–11.
11. Kaffe I, Kaufman A, Littner M, Lazarson A. Radiographic study of the root canal system of mandibular anterior teeth. *Int Endod J*. 1985;18(4):253–9.
12. Shrivastava N, Arora V, Bhandari M, Nikhil V. Endodontic management of mandibular canine with two canals. *J Int Clin Dent Res Organ*. 2014;5(1):24–6.
13. Laurichesse JM, Maestroni J, Breillat J. *Endodontie clinique*; 1986.
14. Heling I, Gottlieb-Dadon I, Chandler NP. Mandibular canine with two roots and three root canals. *Dent Traumatol*. 1995;11(6):301–2.
15. Orguneser A, Kartal N. Three canals and two foramina in a mandibular canine. *J Endod*. 1998;24(6):444–5.
16. Victorino FR, Bernardes RA, Baldi JV, de Moraes IG, Bernardinelli N, Garcia RB, et al. Bilateral mandibular canines with two roots and two separate canals: case report. *Braz Dent J*. 2009;20(1):84–6.
17. Sert S, Bayirli GS. Evaluation of the Root Canal Configurations of the Mandibular and Maxillary Permanent Teeth by Gender in the Turkish Population. *J Endod*. 2004;30(6):391–8.
18. Vertucci FJ. Root canal morphology and its relationship to endodontic procedures. *Endod Top*. 2005;10(1):3–29.
19. White SC, Pharoah MJ. *Intraoral radiographic examinations. Oral radiology principles and interpretation*. Amsterdam: Elsevier; 2008. p. 121–65.
20. Soleymani A, Namaryan N, Moudi E, Gholinia A. Root canal morphology of mandibular canine in an Iranian population: a CBCT assessment. *Iran Endod J*. 2017;12(1):78–82.
21. Carr GB. Microscopes in endodontics. *J Calif Dent Assoc*. 1992;20:55–61.

### Author biography

**Kishan Agarwal** MDS

**Praveen Singh Samant** Professor & HOD

**Vipul Srivastava** Professor

**Gaurav Jain** Reader

**Cite this article:** Agarwal K, Samant PS, Srivastava V, Jain G. **Demystifying anatomical variations – Endodontic therapy of twin rooted mandibular canine with concomitant root canals: An unusual case report.** *IP Indian J Conserv Endod* 2020;5(3):150-153.