



## Case Report

# Nonsurgical management of trauma-induced inflammatory internal- external root resorption: A case report

Siddharth Rai<sup>1,\*</sup>, R Anitha Kumari<sup>1</sup>

<sup>1</sup>Dept. of Conservative Dentistry and Endodontics, Vokkaligara Sangha Dental College and Hospital, Bengaluru, Karnataka, India



## ARTICLE INFO

### Article history:

Received 08-09-2020

Accepted 15-09-2020

Available online 11-11-2020

### Keywords:

Calcium hydroxide

Cone beam computed tomography

Mineral trioxide aggregate

Root resorption

## ABSTRACT

Root resorption is one of the serious consequences of dental trauma. If left untreated, it may lead to loss of significant portion of the root, rendering the tooth unsalvageable. This report documents the nonsurgical management of a previously traumatized maxillary lateral incisor (#22) with a large periapical lesion, severely affected by inflammatory communicating internal- external root resorption. A cone beam computed tomography was advised, to aid in diagnosis and treatment planning. Endodontic treatment comprised of copious irrigation with 1.5% sodium hypochlorite and 2% chlorhexidine gluconate, intracanal calcium hydroxide dressings and mineral trioxide aggregate (MTA) placement in apical 5mm. Follow up at 6 months showed arrest of resorptive process and initiation of periapical healing. At 12 months, complete radiographic healing in the absence of clinical signs and symptoms was evident.

© 2020 Published by Innovative Publication. This is an open access article under the CC BY-NC license (<https://creativecommons.org/licenses/by-nc/4.0/>)

## 1. Introduction

Root resorption is a serious complication of traumatic dental injuries. If resorption is extensive and involves a large portion of the root, the tooth becomes unsalvageable and extraction remains the only option. Upon detection of root resorption, treatment should be promptly initiated in order to arrest the resorptive process and prevent tooth loss.

Root resorption is initiated when the protective, non-mineralized precemental (outer) layer or the predental (inner) layer of the root gets damaged due to mechanical or chemical injury.<sup>1,2</sup> However, for the progression of resorptive process, a stimulating factor such as intrapulpal infection or pressure is necessary.<sup>1,3</sup> Traumatic injury to the teeth with subsequent intrapulpal and periradicular infection is one of the main cause of inflammatory root resorption.<sup>4,5</sup> Inflammatory root resorption may manifest as internal, external or combined internal-external lesions.<sup>6</sup>

This case report presents the successful nonsurgical management of a previously traumatized maxillary lateral

incisor with a large periapical lesion, severely affected by combined internal-external root resorption.

## 2. Case Report

A 21 year old female patient was referred to department of conservative dentistry and endodontics for endodontic management of her upper left front tooth. Patient presented with a chief complaint of pain and swelling in relation to her upper left front tooth and had a history of trauma, 8 years back, for which no dental treatment was sought. Pain was intermittent, mild and non-radiating in nature.

### 2.1. Clinical and radiographic examination

Upon clinical examination, an intraoral swelling was noticed in relation to maxillary left lateral incisor(#22).#22 was slightly discoloured and rotated, and showed no signs of fracture, mobility or caries. On percussion, the tooth was slightly tender. Upon vitality testing, both #22 and #23 were non-responsive to electric pulp test and cold test (Roeko Endo-Frost, Coltene, Switzerland), indicative of non-vital #22 and #23.#21 gave positive response to electric pulp test

\* Corresponding author.

E-mail address: [siddharthjai@gmail.com](mailto:siddharthjai@gmail.com) (S. Rai).

and cold test.

On radiographic examination, IOPA revealed a large, round, well circumscribed radiolucency in relation to #22. Also, #22 showed widening of root canal space and resorption of root apex. Considering the complexity of the case, a cone beam computed tomography (CBCT) was advised. Preoperative CBCT (Figure 1A) revealed a large, well defined periapical lesion associated with the apex of #22. The lesion measured 1.5cm x 1.25cm in size and extended from the distal aspect of root of #21 to the mesial aspect of root of #23. Also, #22 showed abnormal widening of the root canal space and resorption of root apex. Widening of the canal space was more pronounced in the apical 4-5 mm. The outer wall of the root was intact and showed no signs of perforation. Based on history, and clinical and radiographic examination, a diagnosis of trauma-induced inflammatory combined internal-external root resorption was made.

## 2.2. Treatment

After explaining the risks and alternative treatments, consent was obtained from the patient. Treatment was completed in four visits.

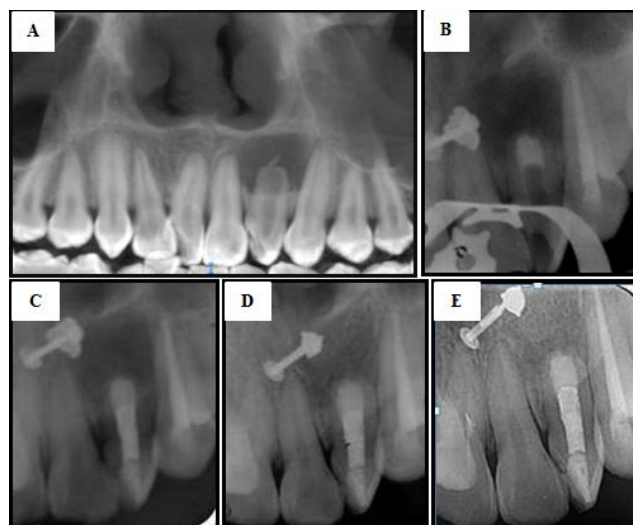
After achieving adequate local anaesthesia, #22 and #23 were isolated with the help of a rubber dam. After gaining access to the canals, working length was determined by Ingle's radiographic method (#22-19mm; #23-25mm). Canals were prepared using stainless steel K-files (Dentsply, Switzerland), in a step back fashion. During the procedure, a straw coloured fluid could be seen draining through the canal of #22. In between instrumentation, the canals were gently irrigated with copious 1.5% sodium hypochlorite (NaOCl) solution. After completion of instrumentation, the canals were irrigated with 17% EDTA, followed by 1.5% NaOCl and sterile saline. Manual dynamic agitation was performed and a final rinse of 2% chlorhexidine gluconate (CHX) was carried out. Calcium hydroxide (ApexCal, Ivoclar Vivadent) dressing was placed in #22, and accesses were temporarily sealed with Cavit<sup>TM</sup>G (3M ESPE). Patient was recalled after one week.

In one week time, the swelling drastically reduced in size. #23 was obturated with gutta percha and Roeko Seal sealer (Coltene) using cold lateral condensation technique and access cavity restored with composite resin. Calcium hydroxide from #22 was removed with the help of copious sterile saline irrigation and size 40 H-file. Slight amount of fluid drainage from #22 was still observed. The irrigation regimen of the first visit was repeated. A fresh dressing of calcium hydroxide was placed and patient was recalled after one week.

In the third visit, swelling had completely disappeared. Calcium hydroxide from #22 was removed in the same manner. At this stage, drainage had stopped completely. The canal was completely dried with paper points. Mineral

trioxide aggregate (MTA Angelus) was mixed according to manufacturer's instruction and a small portion of it was introduced into the canal with the help of MTA carrier. The material was then gently condensed to the working length with the help of hand pluggers. The procedure was repeated until the apical 5 mm of #22 was filled with MTA (Figure 1B). Access was temporarily sealed and MTA allowed to set. Patient was recalled after 2 days and the remaining root canal space was obturated with thermoplasticized gutta percha technique (Calamus Dual 3D Obturation System, Dentsply Sirona) (Figure 1C).

Radiographic follow up at 6 months showed arrest of the resorptive process and initiation of periapical healing in the absence of clinical signs and symptoms. The lesion reduced in size, and new bony trabeculae in the area of defect were evident (Figure 1D). At 12 months, patient was asymptomatic, and there was radiographic evidence of complete periapical healing with advanced osseous regeneration (Figure 1E).



**Fig. 1: A-E);** A- Preoperative CBCT (Panoramic reconstruction) image; B- Non-vital 23 obturated and MTA placed w.r.t 22; C- Immediate postoperative radiograph; D- 6 months follow-up radiograph; Root resorption is arrested and periapical healing is in place; E- At 12 months, healing is complete, with advanced osseous regeneration.

## 3. Discussion

A CBCT was advised in this case, so as to determine the three dimensional extent of the periapical lesion, and the severity and type of root resorption. Unlike the 2D periapical radiography, CBCT aids in accurately determining the location and extent of a lesion. A study by Estrela et al. showed that CBCT were superior in detecting inflammatory root resorption than periapical radiographs when root third, root surface and extension

were determined.<sup>7</sup>

In the present case, the initiating and stimulating factor for root resorption was trauma, and pulpal and periapical infection respectively. In order to arrest the resorptive process, removal of the stimulating factor (pulpal and periapical infection in this case) is mandatory.<sup>1,5,8</sup> Treatment options for large periapical lesions may range from nonsurgical endodontic treatment to different surgical interventions. The present case was managed by nonsurgical endodontic treatment as it is conservative and less traumatic, with successful outcomes in majority of cases. Previous reports have shown that 42 to 74% of these lesions healed after conventional root canal treatment.<sup>9–11</sup> Considering the size and severity of the periapical lesion in the present case, stringent irrigation regimen was carried out, along with two dressings of calcium hydroxide medicament at one week intervals. Previous studies suggest that intracanal calcium hydroxide can eliminate residual microorganisms and promote periapical healing via handling of inflammation, endotoxin neutralization and stimulation of calcification.<sup>12,13</sup>

The apical 5 mm (portion most affected by resorption) of #22 was obturated with MTA. This could be attributed to the good sealing ability, excellent biocompatibility and hard tissue inductive effect of MTA.<sup>14,15</sup> Also, it has been shown that MTA can release calcium ions into resorption defects via dentinal tubules, favouring repair potential of surrounding tissues.<sup>16</sup> These favourable properties render MTA a suitable material for managing inflammatory root resorption defects.<sup>17</sup>

In the present case, the crown-root ratio could not be re-established to an ideal level. Nevertheless, the treatment outcome was considered successful, because the resorption was arrested and complete regeneration of the periapical tissues, in the absence of clinical signs and symptoms was evident. Patient was pleased with the treatment outcome, as a permanent tooth with otherwise questionable prognosis was salvaged.

#### 4. Conclusions

CBCT may be of great help in diagnosis and treatment planning of inflammatory root resorption. Thorough chemo-mechanical debridement of the root canal system and use of bioactive root repair materials such as MTA can significantly improve the healing outcomes in cases of infection related inflammatory internal-external root resorption.

#### 5. Source of Funding

No financial support was received for the work within this manuscript.

#### 6. Conflict of Interest

The authors declare they have no conflict of interest.

#### References

1. Trope M. Root resorption of dental and traumatic origin: classification based on etiology. *Pract Periodontics Aesthet Dent.* 1998;10:515–22.
2. Andreasen J, Bakland L. Pathologic tooth resorption. In: Ingle J, Bakland L, Baumgartner J, editors. *Ingle's Endodontics.* BC Decker; 2008. p. 1358–82.
3. Tronstad L. Root resorption - etiology, terminology and clinical manifestations. *Dent Traumatol.* 1988;4(6):241–52. doi:10.1111/j.1600-9657.1988.tb00642.x.
4. Andreasen JO, Bakland LK, Andreasen FM. Traumatic intrusion of permanent teeth. Part 2. A clinical study of the effect of preinjury and injury factors, such as sex, age, stage of root development, tooth location, and extent of injury including number of intruded teeth on 140 intruded permanent teeth. *Dent Traumatol.* 2006;22(2):90–8. doi:10.1111/j.1600-9657.2006.00422.x.
5. Heithersay GS. Management of tooth resorption. *Aust Dent J.* 2007;52:S105–21. doi:10.1111/j.1834-7819.2007.tb00519.x.
6. Trope M, Chivian N, Sigurdsson A, Vann WF. Traumatic injuries. In: Cohen S, Burns RC, editors. *Pathways of the pulp.* St Louis: Mosby; 2002. p. 603–49.
7. Estrela C, Bueno MR, Alencar AHGD, Mattar R, Neto JV, Azevedo BC, et al. Method to Evaluate Inflammatory Root Resorption by Using Cone Beam Computed Tomography. *J Endod.* 2009;35(11):1491–7. doi:10.1016/j.joen.2009.08.009.
8. Trope M. Root Resorption due to Dental Trauma. *Endod Topics.* 2002;1(1):79–100. doi:10.1034/j.1601-1546.2002.10106.x.
9. Çalışkan M. Prognosis of large cyst-like periapical lesions following nonsurgical root canal treatment: a clinical review. *Int Endod J.* 2004;37(6):408–16.
10. Asgary S, Ehsani S. Endodontic treatment of a large periradicular lesion: A case report. *Iran Endod J.* 2008;3(4):134.
11. Sood N, Maheshwari N, Gothi R, Sood N. Treatment of Large Periapical Cyst Like Lesion: A Noninvasive Approach: A Report of Two Cases. *Int J Clin Pediatr Dent.* 2015;8(2):133–7. doi:10.5005/jp-journals-10005-1299.
12. Farhad A, Mohammadi Z. Calcium hydroxide: a review. *Int Dent J.* 2005;55(5):293–301. doi:10.1111/j.1875-595x.2005.tb00326.x.
13. Tronstad L, Andreasen JO, Hasselgren G, Kristerson L, Riis I. pH changes in dental tissues after root canal filling with calcium hydroxide. *J Endod.* 1981;7(1):17–21. doi:10.1016/s0099-2399(81)80262-2.
14. Holden D, Schwartz S, Kirkpatrick T, Schindler W. Clinical Outcomes of Artificial Root-end Barriers with Mineral Trioxide Aggregate in Teeth with Immature Apices. *J Endod.* 2008;34(7):812–7.
15. Witherspoon DE, Small JC, Regan JD, Nunn M. Retrospective Analysis of Open Apex Teeth Obturated with Mineral Trioxide Aggregate. *J Endod.* 2008;34(10):1171–6. doi:10.1016/j.joen.2008.07.005.
16. Özdemir HÖ, Özçelik B, Karabucak B, Cehreli ZC. Calcium ion diffusion from mineral trioxide aggregate through simulated root resorption defects. *Dent Traumatol.* 2008;24(1):70–3. doi:10.1111/j.1600-9657.2006.00512.x.
17. Torabinejad M, Chivian N. Clinical applications of mineral trioxide aggregate. *J Endod.* 1999;25(3):197–205. doi:10.1016/s0099-2399(99)80142-3.

#### Author biography

**Siddharth Rai**, Consultant

**R Anitha Kumari**, Professor

**Cite this article:** Rai S, Kumari RA. Nonsurgical management of trauma-induced inflammatory internal- external root resorption: A case report. *IP Indian J Conserv Endod* 2020;5(4):212-215.