



Case Report

Radix entamolaris: An anatomical challenge

Varnika Yadav^{1,*}, Praveen Singh Samant¹, Ayush Razdan Singh¹

¹Dept. of Conservative Dentistry and Endodontics, Saraswati Dental College and Hospital, Lucknow, Uttar Pradesh, India



ARTICLE INFO

Article history:

Received 14-01-2021

Accepted 14-01-2021

Available online 16-03-2021

Keywords:

Endodontic treatment

Mandibular first molar

Morphological Variations

Radix Entamolaris

ABSTRACT

Generally, mandibular first molars have one mesial and distal root but in few cases there are morphological variations where in the number of roots and root canals may vary. Radix Entomolaris (RE) is the presence of an additional lingual root distally in mandibular molars. Correct diagnosis is important before starting with endodontic therapy in these teeth to ensure successful treatment outcome. This case report series describes the endodontic management of mandibular first molar with radix entamolaris.

© This is an open access article distributed under the terms of the Creative Commons Attribution License (<https://creativecommons.org/licenses/by/4.0/>) which permits unrestricted use, distribution, and reproduction in any medium, provided the original author and source are credited.

1. Introduction

The main aim of root canal treatment is to get rid of bacteria from root canal and complete elimination of micro-organism which ultimately prevents the chances of re-infection. An adequate cleaning and shaping of root canal, hermetic seal after obturation helps in achieving an endodontic goal. Thus, clinicians should have thorough knowledge about anatomic variations such as webs, fins, extra canals, and extra roots.¹

For successful root canal treatment thorough understanding of root canal morphology is important. Missed canals may act as a place in which bacteria can multiply eventually leading to the failure of an endodontic treatment. Developmental anomaly like supernumerary root can affect any tooth. Carabelli was the first to describe an additional third root i.e. radix entamolaris. Radix entamolaris can be mature or short conical extension of usual length. Development of radix entamolaris has an uncertain etiology. In euphoric roots, etiology could be associated with racial genetic factors where as dysmorphic roots could be correlated with external factors like odontogenesis, polygenetic system or with the penetrance

of an atavistic gene.²

Probability of finding extra canals or extra roots is more in premolars and molars.³ Radix entamolaris is a macrostructure, lingually located extra root.⁴ If a macrostructure is present mesiobuccally, it is known as radix paramolaris.³ 43.7% of radix entamolaris with maximum frequency has been reported in Mangolian population and about 3.4 % has been reported in European population.⁴ Incidence of an occurrence of radix entamolaris in Indian population is only 0.2%.³

Root canal configuration and morphologies can be evaluated with different methods like in vitro studies, cone beam computed tomography, radiographs and computed tomography. Cone beam computed tomography is preferred over radiographs as CBCT helps to bring out the three dimensional image which can be sectioned.⁵ CBCT provides high-contrast resolution that totally removes the superimposition of structural images, which are not of interest.¹

The purpose of this case report is to present a case series of radix entamolaris having in mandibular 1st molar with beneficial knowledge of its incidence, identification and management.

* Corresponding author.

E-mail address: varnika223@gmail.com (V. Yadav).

2. Case Report 1

A 22-year-old female patient reported in a Department of Conservative Dentistry and Endodontics, Saraswati Dental College with a chief complaint of pain in a lower-right posterior tooth since fifteen days. The pain aggravates on taking hot beverages. A radiograph revealed the radiolucency approaching to pulp and the presence of extra root in distal side. Diagnosis of irreversible pulpitis was made for right mandibular molar #46.

Local anesthesia (2% lidocaine with 1:40,000 adrenaline) was administered. Under rubber dam, all carious tissue was removed. An adequate access cavity was prepared. The working length was determined by an apex locator (Denta Port; J.Morita Mfg Corp, Kyoto, Japan) and radiograph (Figure 1a). All canals were cleaned with Protaper NiTi rotary instruments (Dentsply-Maillefer, Ballaigues, Switzerland) under magnifying loupes. Irrigation with 5.25% sodium hypochlorite, 17% EDTA (Prime Dental Products Pvt Ltd, Mumbai India) and saline was performed. Canals were dried with sterile paper point and mastercone radiograph was taken (Figure 1b). Obturation was done using single cone for tooth #46. The tooth was restored using composite.

3. Case Report 2

A 26-year old female patient reported in a Department of Conservative Dentistry and Endodontics, Saraswati Dental College with a chief complaint of pain in a lower-right back tooth region since one month. The pain aggravates on taking cold and hot. The pain subsides on taking medication. Clinically, a deep proximal carious lesion was seen distally #46. A radiograph revealed the radiolucency involving enamel, dentin and pulp. It also revealed the presence of an additional supernumerary root on distolingual side. Diagnosis of irreversible pulpitis was made for right mandibular molar #46.

Local anesthesia (2% lidocaine with 1:40,000 adrenaline) was administered. Under rubber dam, all carious tissue was removed and an adequate access cavity was prepared. The working length was determined radiographically (Figure 2 a) and all canals were cleaned with protaper NiTi rotary instruments (Dentsply-Maillefer, Ballaigues, Switzerland). Irrigation with 5.25% sodium hypochlorite, 17% EDTA (Prime Dental Products Pvt Ltd, Mumbai India) and saline was performed and canals were dried with sterile paper point. Mastercone radiograph was taken (Figure 2b) and obturation was done using single cone for tooth #46 (Figure 2c). The tooth was restored with composite resin.

4. Discussion

For the successful endodontic therapy three things are required:-

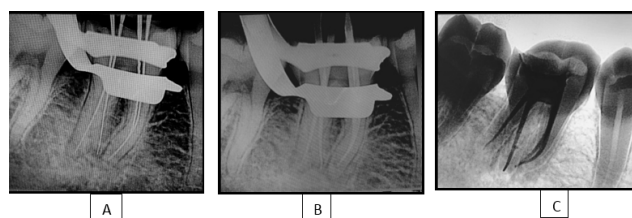


Fig. 1: Radiograph showing working length #46., b- Mastercone radiograph #46., c- Radiograph showing obturation of all the root canals #46.

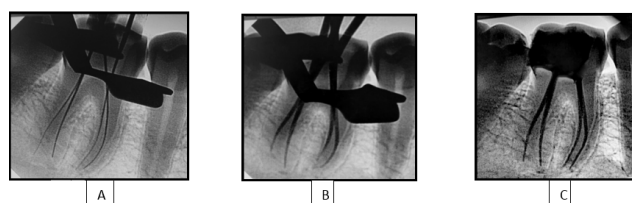


Fig. 2: Radiograph showing working length #46., b- Mastercone radiograph #46., c- Radiograph showing obturation #46.

1. Correct diagnosis
2. Appropriate Chemo-mechanical preparation
3. Three Dimensional Obturation

One of the most important steps in the direction of successful root canal treatment is an accurate diagnosis. Negligence in the complete removal of microbes and pulpal tissue can lead to the failure of an endodontic treatment.⁶

Anatomical variations may present with mandibular 1st molar, if these variations are not recognized then it may lead to the treatment failure. Therefore, it is essential to locate extra roots. Presence of an additional root can be indicated by extra cusp, prominent distolingual lobe or distal cusp, along with cervical convexity. If primary molars has an additional root than chances of presence of extra root in an adjacent molar is more than 94.3%. Therefore, we can say that primary molars with additional root could used to forecast the extra root present posterior to it.⁷

The etiology of radix entamolaris is still unknown. Radix entamolaris can be partially fused or separated. Generally, it is smaller than distobuccal or mesial root. According to the location, Carlsen and Alexander categorized radix entamolaris into four types; A, B, C and AC. Type A & B; the cervical portion is located distally and 2, 1 are the normal distal root components respectively. In Type C; cervical portion is present mesially. In Type AC; it is located lingually between mesial and distal root components.³

De Moor et al. categorized Radix entamolaris into three types:-

1. Type I- root/root canal are straight.
2. Type II- root/root canal are initially curved which continues as straight.

3. Type III- root/root canal are curved till coronal third, after middle second curve begins and continues to the apical third.³

In terms of configuration of canal, radix entomolaris is rounder and usually has Vertucci type I configuration.³ Generally, endodontic access cavity is triangular in shape for mandibular 1st and 2nd molars but present study is suggestive of trapezoidal shape for ease access to the location of canal orifices.⁵

Various methods like dentinal map, canal bleeding points, ultrasonic tips, staining of chamber with methylene (root) blue dye (1%). Champagne bubble test, CBCT can help in identifying the additional canal. Magnifying loupes, intraoral camera, radiographs and dental microscope are some aids to clinical examination of radix entomolaris. Chances of missed canals can be minimized by taking radiographs at different angulations.⁶

Third root or additional root could be evident in about 90% of cases, radiographically. Careful radiographic examination helps in revealing the presence of radix entomolaris.¹ Outline of root contour or unclear view of root canal on IOPA can indicate the presence of hidden additional root.² At least two angulated radiographs are required along with careful examination to avoid any iatrogenic mistake.⁶ CBCT is used often for study of morphology in endodontics.⁵

Dentists should be aware of possibilities for variations in root morphology in mandibular first molars, identification of additional roots, adequate clinical approach to manage the radix entomolaris cases.³

5. Conclusion

It has been reported that the radix entomolaris has a frequency of 0.2–32% occurrence in different populations. It is important to know the exact characteristic of the radix entomolaris in terms of curvature and conformation for a proper treatment plan. Hence, such cases require appropriate judgment for application of diagnostic tools and endodontic skills for the management of radix entomolaris. Careful interpretation of the radiograph, using different angulations, horizontal cone projections and advanced tools such as magnifying loupes, operating microscope, CBCT, may facilitate their recognition. Management of the extra

canal and root can be done using equipments such as magnification aids, orifice locators and flexible files, once diagnosed.

6. Source of Funding

No financial support was received for the work within this manuscript.

Conflicts of interest

The author declares that they do not have any conflict of interests.

References

- Attam K, Nawal RR, Utneja S, Talwar S. Radix entomolaris in mandibular first molars in Indian population: A review and case reports. *Case Rep Dent*. 2012;doi:10.1155/2012/595494.
- Patil A, Shigli A, Tamagond SB, Pushpalatha C. Missed canal...call from radix entomolaris. *Case Rep*. 2014;doi:10.1136/bcr-2013-202204..
- JSinha D, Mahesh S, Jaiswal N, Vasudeva A. Radix Entomolaris: A Report of Two Cases. *Bull Tokyo Dent Coll* . 2016;57(4):253–8. doi:10.2209/tdcpublication.2015-0027.
- Carlsen O, Alexandersen V. Radix paramolaris in permanent mandibular molars: identification and morphology. *Eur J Oral Sci*. 1991;99(3):189–95. doi:10.1111/j.1600-0722.1991.tb01884.x.
- Duman SB, Duman S, Bayrakdar IS, Yasa Y, Gumussoy I. Evaluation of radix entomolaris in mandibular first and second molars using cone-beam computed tomography and review of the literature. *Oral Radiol*. 2020;36(4):320–6. doi:10.1007/s11282-019-00406-0.
- Arora A, Arya A, Chauhan L, Thapak G. Radix Entomolaris: Case Report with Clinical Implication. *Int J Clin Pediatr Dent*. 2018;11(6):536–8. doi:10.5005/jp-journals-10005-1572.
- Jindal MK, Agrawal N, Garg AK, Tewari RK. Radix Entomolaris: A Clinical Challenge. *Int J Clin Pediatr Dent*. 2010;3(2):105–6. doi:10.5005/jp-journals-10005-1063.

Author biography

Varnika Yadav, Post Graduate Student

Praveen Singh Samant, Professor and Head

Ayush Razdan Singh, Professor

Cite this article: Yadav V, Samant PS, Singh AR. Radix entomolaris: An anatomical challenge. *IP Indian J Conserv Endod* 2021;6(1):41-43.