



Review Article

Preserved for endurance: Minimal invasive endodontics

Megha Chethan^{1,*}, Revathi K¹, Revathi Natesan¹, Rashmi M², Soubhagya M¹, Veena S Nair¹¹Dept. of Conservative & Endodontics, KGF College of Dental Sciences, Robertsonpet, Karnataka, India²Dept. of Public Health Dentistry, KGF College of Dental Sciences, Robertsonpet, Karnataka, India

ARTICLE INFO

Article history:

Received 19-04-2021

Accepted 22-05-2021

Available online 30-06-2021

Keywords:

Conservation

Endodontics

CBCT

Prognosis

Clinician

Treatment

ABSTRACT

In the modern era, inclination towards a more conservative approach is being advocated and this has become possible through various innovative machinery and techniques. A conservative tooth preparation helps in retaining more of a tooth structure which would determine the prognosis of the treatment and the fate of the tooth in the long run. Even though we have a high focus on the conservative approach, we should keep in mind that there is always a chance of errors which is caused due to inadequate access to the canals. It is ultimately the clinicians call to decide between the benefit to the risk ratio and also its feasibility, all of which should result in good prognosis as well as a fruitful qualitative treatment outcome for the patient.

© This is an open access article distributed under the terms of the Creative Commons Attribution License (<https://creativecommons.org/licenses/by/4.0/>) which permits unrestricted use, distribution, and reproduction in any medium, provided the original author and source are credited.

1. Introduction

A conservative approach has always been the motive of the treating clinician. Gone are the times wherein there was extensive preparation of the tooth structure to accomplish the treatment. Lots of advanced protocol along with supportive machinery has been invented over the century and the progress shall not be halted. It is the duty of the clinicians to remain up to date and make use of such equipment to increase their efficacy as well as produce qualitative treatment.

In the modern era, inclination towards a more conservative approach is being advocated and this has become possible through various innovative machinery and techniques. The importance of preservation as well as a conservative treatment approach is highly appreciable however hindrances like reduced accessibility as well as reduced vision with many other reasons have been cited.

In RCT, access to the canals requires a more accessible coronal as well as cervical preparation for better instrumentation and delivery of irrigants.¹ However, a compromised access would lead to difficulty in locating the canals as well as incomplete debridement, disinfection, and obturation may lead to root canal failure.²

A conservative tooth preparation helps in retaining more of a tooth structure which would determine the prognosis of the treatment and the fate of the tooth in the long run. Conservative approach with reduced removal of tooth structure helps to reduce the risk of tooth fracture as well as increased service life.

A study done to determine the impact of endodontic versus restorative procedures on tooth strength, have reported that endodontic access openings showed a 5% impact on tooth stiffness in comparison to any procedures involving removal of the tooth's marginal ridges, which in turn reduces the cuspal stiffness by 63%. This provided us with a conclusion that marginal ridges are a key factor in retaining the tooth strength. The most commonly cited reason for brittleness of teeth is due to loss of moisture,

* Corresponding author.

E-mail address: karthikyadavd@gmail.com (M. Chethan).

and also inconsequential variance in the moisture among endodontically treated teeth and vital teeth.^{3,4}

It is recommended to prepare the tooth structure with preservation of the Peri Cervical Dentin, 3D ferrule and 3D Soffit, all of which helps to enhance the prognosis and increase the longevity of the tooth.⁵

During a normal access cavity preparation for RCT, a straight line approach is made for better access to the canals, efficacious biomechanical preparation and diminished procedural slips. However such preparation can take place only when there is a proper knowledge of the anatomy, accurate diagnostic pre-image, guiding templates and a sound expertise to make use of the same.

The use of newer surgical operative microscope and newer vision-based mental model is Look, Groom, and Follow, which are all round-ended tapered burs made to escalate the radius of the gouges as well as the nicks that can act as stress concentration points. The flatter flanks aids to generate a slicker and flatter walls. It also helps to curtail the gouges and dings which are unavoidable during cavity preparation even with utmost care.⁶

Newer access designs include

1. Conservative Endodontic Access Cavity
2. Ninja Endodontic Access Cavity
3. Orifice-Directed Dentin Conservation Access Cavity
4. Incisal Access
5. Cala Lilly Enamel Preparation

1.1. Conservative Endodontic Access Cavity (CECs)

Herein, the traditional access cavity is modified into a more constrictive and definitive form to minimize the tooth damage and prolong the service life of the treated tooth. This technique was advocated by John Khademi and David Clark keeping in mind the longevity of the tooth by upholding the mechanical stability of the tooth.^{6,7} (Figure 1)

The approach for the cavity preparation begins at the central fossa and is comprehensively drawn out as to spot and access the canal orifices, all of which would help in the salvation of the pericervical dentin as well as the part of the floor of the chamber. (Figure 2)

1.2. Ninja endodontic access cavity (NECs)

The outline of the cavity is based on its name a ‘Ninja’, wherein there is an oblique projection headed in direction of the central fossa of the root orifices in an occlusal plane. It runs in a line which is parallel in direction with enamel cut of 90° or more in regard to the occlusal plane, providing better visualization of the root canal orifices when seen from capricious angulations.^{6,8,10}

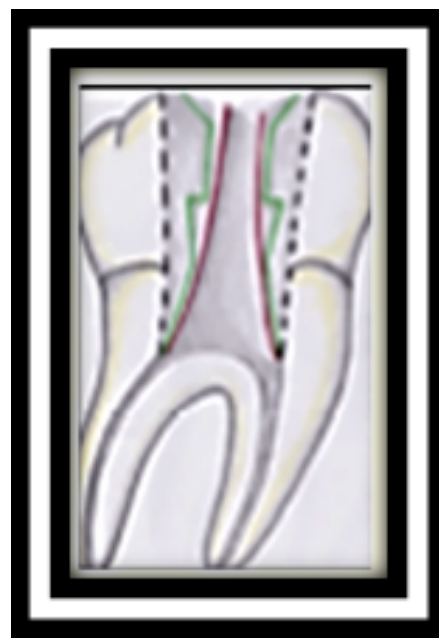

Fig. 1: Black line shows traditional access cavity VS green line shows contracted access cavityvs red line shows ninja access cavity.⁸

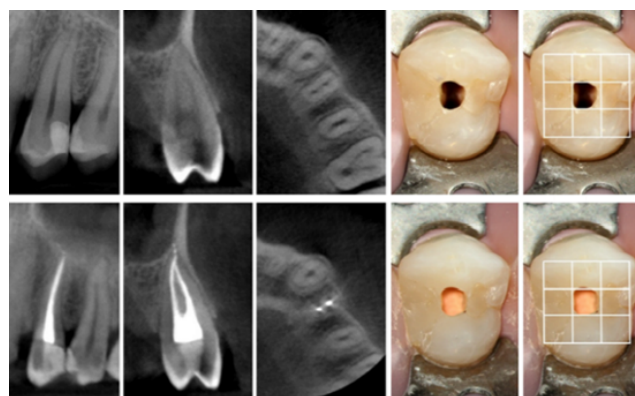

Fig. 2: Contracted Access Cavity along with CBCTsuperimposition⁹

1.3. Orifice-directed dentin conservation access cavity / ‘truss’ access cavity

This access cavity design is unique and requires a more diagnostic image as well as an experienced physician. This is said because here we will have multiple accesses into the coronal portion of the tooth which are in line with the root canal orifices. This helps to retain a significant amount of tooth structure which would help in preserving enamel as well as dentin, which is also called as a truss of dentin between the two prepared cavities that.⁷(Figure 3)

It aims at the removal of dentin just above the orifice, thereby maintaining the maximum amount of sound tooth structure.

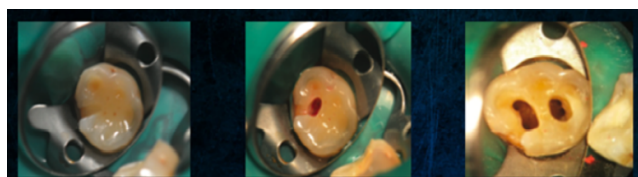


Fig. 3: Truss cavity design⁷

The approach for multi-rooted tooth is different and is as follows:

1. Mandibular molars - two distinct cavities in line with the mesial and the distal canals
2. Maxillary molars- mesiobuccal and distobuccal access is advanced through one cavity and palatal access is another separate cavity approach.^{8,9}

This technique has several disadvantages like

1. A very much high requirement of a straight line access.
2. Enhanced imaging techniques
3. Time-consuming
4. Not recommended when there is inadequate access
5. Difficulty in case of curved canals

1.4. Incisal access blind tunneling

Gouging is mostly seen when we use round burs with access from the cingulum. As the access grows internally, an inverse funnel is created.⁷ A continuous recurrent approach into the canal with the bur leads to the loss of peri-cervical dentin which reflects indirectly onto the tooth longevity.⁶

1.5. Cala lilly enamel preparation

In this technique enamel is cut back at 45 degree in the shape of the Cala Lilly.⁷ This altered preparation encompasses almost the complete occlusal surface during preparation. Even though this preparation may not be as favorable as the other preparations but still it is considered during preparations which have previous amalgam fillings and other large restorations.⁶

2. Advanced Access Techniques

These procedures unlike other normal procedure requires specialized equipment which would help the dentist as well as the guide the dentist to reduce any errors with a more favorable result with a better prognosis.

2.1. Advantages

1. Better idea of the anatomy
2. Reduced working time
3. Higher success rate

4. Less destruction of tooth structure
5. Reduced errors
6. Good/Favorable prognosis

2.2. Disadvantages

1. Requires specialized equipment
2. Higher cost
3. Technique sensitive
4. Not widely available
5. Requires four-handed dentistry
6. Needs more customization

2.3. Image guided endodontic access

This procedure requires additional pre imaging protocol, which are already available with the dentist or available at the nearest diagnostic center, which are easily accessible. These imaging procedures can be used for all patients and can be categorized into “one size fits all”. These diagnostic imaging procedures will help in determination of location as well as the size of the access cavity.

The objectives of this technique include

1. Smallest access cavity
2. Minimal dentin removal
3. Preservation of maximum tooth structure
4. Reduced operator error

2.4. Dynamically guided access

Introduced by Dr. Charles M and most commonly used to place dental implants. Patient CBCT volumetric data helps in determining the location of the access cavity. Further, overhead tracking cameras relate to the position of the patient’s jaw and the clinician’s bur in 3- dimensional space. At the same moment with the help of the software the clinician makes use of the software interface and with an active responsive feedback is about to get the precise location with a depth determination in respect to the planned access and the tooth

2.5. Microguided endodontic access

Special software which works in corrugation with CBCT and a surface scan provides us with a virtual outline of the access cavity.¹¹

Another technologically added feature to such a procedure is the printing of a template accomplished by the use of a 3D printer. It helps to direct a minimally invasive drill into the calcified root canal which is useful in conserving the tooth structure and avoid/reduce the errors possible.

Guided access cavity aims at combining CBCT and 3-D printer technology, a bur is specially designed according to the design of the tooth as seen by the CBCT image. A virtual bur is first made and then superimposed on the tooth, and

then the 3D printer is used to make the specific bur, which then helps in making the endodontic access. ¹²(Figure 4)

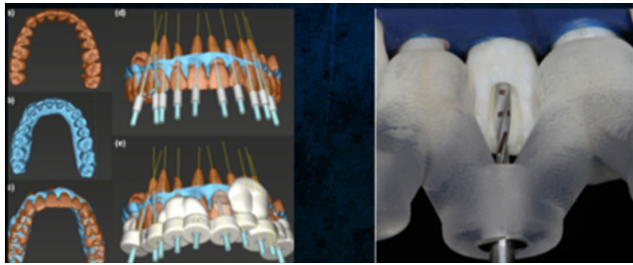


Fig. 4: Guided endodontic access cavity¹²

3. Conclusion

To provide the patient with the best possible treatment we should be well versed with the anatomy, the procedure, new addendums, latest machinery available, the costs involved, the feasibility, the experience and the required expertise. Even though we have a high focus on the conservative approach, we should keep in mind that there is always a chance of errors which is caused due to inadequate access to the canals. It is ultimately the clinicians call to decide between the benefit to the risk ratio and also its feasibility, all of which should result in good prognosis as well as a fruitful qualitative treatment outcome for the patient.

4. Conflict of Interest

The authors declare that there are no conflicts of interest in this paper.

5. Source of Funding

This research did not receive any specific grant from funding agencies in the public, commercial, or not-for-profit sectors.

References

1. Christie WH, Thompson GK. The importance of endodontic access in locating maxillary and mandibular molar canals". *J Can Dent Assoc.* 1994;60(6):527-32.
2. Patel S, Rhodes J. A practical guide to endodontic access cavity preparation in molar teeth. *Br Dent J.* 2007;203(3):133-40. doi:10.1038/bdj.2007.682.
3. Helfer AR, Melnick S, Schilder H. Determination of the moisture content of vital and pulpless teeth. *Oral Surg, Oral Med, Oral Pathol.* 1972;34(3):661-70. doi:10.1016/0030-4220(72)90351-9.
4. Papa J, Cain C, Messer HH. Moisture content of vital vs endodontically treated teeth. *Dent Traumatol.* 1994;10(2):91-3. doi:10.1111/j.1600-9657.1994.tb00067.x.
5. Clark D, Khademi J, Herbranson E. The new science of strong endo teeth. *Dent Today.* 2013;32(4):112-4.
6. Anjum SA, Hegde S, and SM. Minimally Invasive Endodontics-A Review. *JDOR.* 2019;15(2):77-88.
7. Clark D, Khademi J. Modern Molar Endodontic Access and Directed Dentin Conservation. *Dent Clin North Am.* 2010;54(2):249-73. doi:10.1016/j.cden.2010.01.001.
8. Plotino G. Fracture strength of endodontically treated teeth with different access cavity designs". *J Endod.* 2017;43(6):995-1000.
9. Bóveda C, Kishen A. Contracted endodontic cavities: the foundation for less invasive alternatives in the management of apical periodontitis. *Endoc Topics.* 2015;33(1):169-86. doi:10.1111/etp.12088.
10. Belograd M. The Genius 2 is coming. 2016;.
11. Connert T, Zehnder MS, Amato M, Weiger R, Kühl S, Krastl G. Microguided Endodontics: a method to achieve minimally invasive access cavity preparation and root canal location in mandibular incisors using a novel computer-guided technique. *Int Endod J.* 2018;51(2):247-55. doi:10.1111/iej.12809.
12. Zehnder MS. Guided endodontics: accuracy of a novel method for guided access cavity preparation and root canal location". *Int Endod J.* 2016;49(10):966-72.

Author biography

Megha Chethan, Professor and HOD

Revathi K, Professor

Revathi Natesan, Reader

Rashmi M, Professor

Soubhagya M, Reader

Veena S Nair, Reader

Cite this article: Chethan M, Revathi K, Natesan R, Rashmi M, Soubhagya M, Nair VS. Preserved for endurance: Minimal invasive endodontics. *IP Indian J Conserv Endod* 2021;6(2):88-91.