

Content available at: <https://www.ipinnovative.com/open-access-journals>

IP Indian Journal of Conservative and Endodontics

Journal homepage: <https://www.ijce.in/>

## Original Research Article

# Cryotherapy as an adjunct to inferior alveolar nerve block in Symptomatic Irreversible Pulpitis: A randomised controlled clinical trial

Richa Gupta<sup>1</sup>, Poonam Prakash<sup>2,\*</sup><sup>1</sup>Army Dental Centre (R&R), Dental Centre, Delhi, India<sup>2</sup>Dept of Dental Surgery & Oral Health Sciences, Armed Forces Medical College, Pune, Maharashtra, India

## ARTICLE INFO

## Article history:

Received 26-02-2022

Accepted 02-03-2022

Available online 31-03-2022

## Keywords:

Anesthesia

Cryotherapy

Ice pack

Endo-Ice

Mandibular molars

Symptomatic irreversible pulpitis.

## ABSTRACT

**Objective:** To evaluate and compare the effect of two approaches of cryotherapy for improving the success rate of Inferior alveolar nerve block and reduction of pain during access opening in mandibular molars with symptomatic irreversible pulpitis.

**Materials and Methods:** Thirty patients diagnosed with symptomatic irreversible pulpitis were selected based on inclusion and exclusion criteria to participate in the study. 3 groups were designed; Group 1(Control group) - inferior alveolar nerve block(IANB) with lignocaine (2%) adrenaline (1:80000), Group 2(IANB+ small ice pack)-inferior alveolar nerve block with lignocaine (2%) adrenaline (1:80000) + small ice packs (wrapped in sterile gauze); Group 3 (IANB+Endo Ice) -inferior alveolar nerve block with lignocaine (2%) adrenaline (1:80000) + Endo Ice application. Patients were randomly allocated to any one of the groups: The level of preoperative pain was recorded using the Numeric visual analogue scale (VAS). Endodontic therapy was done 15 minutes after the IANB injection. The level of intra operative pain during access opening was recorded again using the same scale. If the patients reported moderate or severe pain during the procedure, the IANB was defined as “unsuccessful,” and a supplementary injection was administered.

**Results:** There was statistically significant difference found in pain reduction among 3 groups ( $p=0.01$ ). Post hoc analysis revealed significant difference between Group 1(Control) and Group 2(IANB+ small ice pack) with ( $p=0.003$ ). Overall success rate of IANB was found to be 66.66 %.

**Conclusion:** Both the techniques of intraoral cryotherapy exhibited improved pain reduction as well as increased the success rate of IANBs in mandibular molar teeth with SIP. Hence based on the results obtained, it is suggested that cryotherapy can serve as a useful adjunct to anaesthesia during endodontic procedures.

This is an Open Access (OA) journal, and articles are distributed under the terms of the [Creative Commons Attribution-NonCommercial-ShareAlike 4.0 License](https://creativecommons.org/licenses/by-nc-sa/4.0/), which allows others to remix, tweak, and build upon the work non-commercially, as long as appropriate credit is given and the new creations are licensed under the identical terms.

For reprints contact: [reprint@ipinnovative.com](mailto:reprint@ipinnovative.com)

## 1. Introduction

Mandibular first molar is the most commonly affected with carious lesions as it is the earliest permanent tooth to erupt. So, Inferior alveolar nerve block is the most commonly used nerve block in endodontics, as it is used to anaesthetize mandibular molars for cavity preparation and

endodontic treatment. The success rate reported of Inferior alveolar nerve block is less i.e 19 to 22 %, especially in the cases of symptomatic irreversible pulpitis(SIP).<sup>1</sup> There are certain factors responsible for lower success rates such as difficulty in identifying anatomical landmarks, fear and anxiety of patient, volume and type of anesthetic solution administered, and presence of inflammation.<sup>2</sup> To overcome these factors certain other alternative techniques were recommended. One of those techniques is Gow-Gates

\* Corresponding author.

E-mail address: [pnmprakash@yahoo.co.in](mailto:pnmprakash@yahoo.co.in) (P. Prakash).

nerve block (GGNB)<sup>3</sup> which targets the main mandibular nerve division as it comes out of the foramen ovale, thus anesthetizing the whole of the mandibular nerve. Considerable advantages of the Gow-Gates technique over IANB, include its lower incidence of positive aspiration (approximately 2% vs. 10% to 15% with the IANB) and the absence of problems with accessory sensory innervation to the mandibular teeth therefore improving its higher success rate. Though the success rate improved to (95-96%) but still not 100%. Numerous studies have documented the use of supplementary anesthetic technique such as intrapulpal, intraosseous and intraligamentary, to improve the success of anesthesia.<sup>4</sup> As none of the technique promised 100 percent success rate, search is still on to look for an adjunct which is easy to use and could provide more profound anaesthesia. Cryotherapy is derived from the Greek words “cryos” denoting “cold” and “therapeia” denoting “cure”.<sup>5</sup> It is a long-standing technique that has frequently been applied in medicine for pain management and postoperative care.<sup>6</sup> In the field of endodontics, cryotherapy has been reported to be used after periradicular surgeries and during root canal treatment to minimize postoperative pain and inflammation.<sup>7</sup> Other implementation of cryotherapy in endodontics is deep cryotherapy of nickel-titanium (NiTi) endodontic files, which offered enhanced cyclic fatigue resistance, reducing potential file separation.<sup>8</sup> Very few studies have been done on evaluate the effect of cryotherapy as an adjunct in anesthesia. Recently a study done by Topçuoğlu et al where they concluded that use of Intraoral cryotherapy in the form of small ice pack increased the success rate of IANBs in mandibular molar teeth with SIP.<sup>9</sup> Another study with was done by Vishnupriya et al evaluated the efficacy of Endo-Ice as an adjunct to inferior alveolar nerve block and they concluded that cold is a simple, supplementary technique in reducing pain during pulp extirpation.<sup>10</sup> However, to date, there are no clinical trials evaluating and comparing the effect of vestibular intraoral ice pack therapy with endo ice application on the success rate of IANBs in mandibular molars with SIP. Based on this information, we evaluated and compared the effect of preoperative intraoral small ice packs (wrapped in sterile gauze) therapy versus application of endo ice as an adjunct on the success rate of IANBs in mandibular molars with SIP.

## 2. Materials and Methods

This study was a randomized controlled clinical trial. It was designed and reported by adhering to consolidated standards of reporting trials statement and approval was obtained from institutional ethical committee (Figure 1)

### 2.1. Study design

Sixty patients fitting the inclusion criteria were included in the study. Oral and written consent forms were obtained from all patients who participated in the trial. Baseline parameters such as age, gender, tooth nomenclature, preoperative pain were recorded prior to treatment. The inclusion criteria were, patients in good health between 18–50 years of age, mandibular molars diagnosed with SIP, preoperative pain > 4 on a visual analog scale (Moderate to severe pain). The exclusion criteria were patients not willing to participate in the study, allergic to lignocaine, age not falling between 18-50 years, non vital teeth, teeth with apical periodontitis, medically compromised patients, Immature young permanent teeth and patients with history of intake of analgesics, steroids, and/or antibiotics in the recent past 48 hrs.

### 2.2. Study protocol

Pulp sensitivity was confirmed by a positive response to electric pulp testing and a prolonged response to cold testing. Also, the periapical status of the tooth in the radiograph was normal. For each tooth, a diagnosis of SIP was made based on clinical and radiographic findings. Patients were also given adequate information regarding the required treatment.

### 2.3. Randomization

Computer-generated randomization sequence was carried out by the statistician who was not involved in the study. The randomized order of interventions was concealed in sequentially numbered, opaque, individual tamper-proof sealed envelopes, opened by the operator at the time of treatment. The outcome assessor was a senior endodontist with minimum 10 years of experience and was unaware of the assigned treatment. In short, the design used in this study was a randomized single-blind controlled trial.

All the patients were asked to rate their preoperative pain on a 0-10 Numeric Visual Analog Scale (VAS).(Figure 2)

### 2.4. Study groups

Group 1 (Control,n=10) - A standard IANB was administered using 3.6 mL 2% lidocaine with 1:100,000 epinephrine. The block was administered with a 27-G, long (31-mm) needle inserted slightly laterally at the middle portion of the pterygomandibular raphe to contact bone with the needle bevel directed toward the bone, slightly withdrawn, and aspirated, and solution was deposited.(Figure 3)

Group 2 (IANB+ small ice pack, n=10) – A standard IANBs was given in the same way as was given in the control group. After anesthesia, small ice packs (wrapped in sterile gauze) were placed intraorally in the mouth on the vestibular surface of the treated tooth. Patients were instructed to keep the ice pack in the mouth for 5 minutes. Patients were instructed to remove the ice pack for 1 minute if they felt extreme cold or a burning sensation. (Figure 4)

Group 2 (IANB+ Endo Ice, n=10) - Standard IANB was administered as described previously, then EndoIce (1,1,1,2 tetrafluoroethane; Hygenic Corp, Akron, OH) was applied on the buccal, lingual (3 s/surface), and occlusal surfaces (4s) for a total of 10 s. (Figures 5 and 6)

The endodontic procedure in all the groups began 15 minutes after the IANB if the patient had lip numbness and negative response to the electric pulp test. All operators involved in the study had at least 10 years of experience. Standardization of the protocol was done by choosing the same operator, material, technique and clinical settings. Tooth was isolated using rubber dam. The pulp was exposed and deroofing was done. (Figure 7) The working length was confirmed using an electronic apex locator (PropEx Pixi; Dentsply Maillefer, Ballaigues, Switzerland) and periapical radiographs. A glide path was established with K-files up to a size #15, and the canals were instrumented with nickel titanium rotary files (Protaper universal; Dentsply Maillefer, Ballaigues, Switzerland). The established working length was checked repeatedly throughout the procedure. Depending on the individual tooth, the final apical preparation size was determined as being 3 sizes larger than the first file binding at the working length. During the endodontic procedure, the patients were instructed to report their pain again on the scale of 0-10 according to numeric Visual analog scale. (Figure 8) If the patient recorded no pain or mild pain, the IANB injection was considered a success and treatment continued. If the patient had moderate to severe pain (VAS rating > 4), the IANB was considered a failure. Supplemental anesthesia (periodontal ligament injection or intrapulpal anesthesia) was performed to provide patient comfort throughout the treatment. During the instrumentation process, each canal was irrigated with 5 mL 3% sodium hypochlorite using a syringe with a 31-G double side-port needle (NaviTip; Ultradent, South Jordan, UT) placed 1 mm short of the working length. The final irrigation after the completion of the canal preparation was performed with 5 mL 3% sodium hypochlorite using a syringe and a 31-G double side-port needle (NaviTip) placed 1 mm short of the working length for 1 minute in each canal. Each canal was then irrigated with 2 mL 17% EDTA for 1 minute. The final irrigation was completed with 5 mL distilled water. After the final irrigation, all teeth were obturated in the same session with guttapercha and resin-based sealer.

## 2.5. Evaluation

The level of pre- and intra operative pain was recorded as a continuous data using simple numeric Visual Analogue Scale (VAS). The VAS consisted of a line of 10 cm length anchored by two extremes with 0 signifying no pain and 10 representing the worst pain imaginable. Whereas, 1-3 denotes mild pain, 4-6 moderate pain and 7-9 denotes severe pain.

## 2.6. Statistical analysis

Data was described using mean (SD) for quantitative variables and percentages for qualitative variables. The difference between the groups with respect to reduction in pain was assessed using ANOVA. The post Hoc difference was analysed using Tukey's test. The success rates between the groups was assessed using chi square test. Association of pain reduction and success rate with age, sex, tooth number and number of canals was analysed using chi square test. Significance was assumed at 0.05 level. Statistical analysis was carried out using SPSS 23.0 software.

## 3. Results

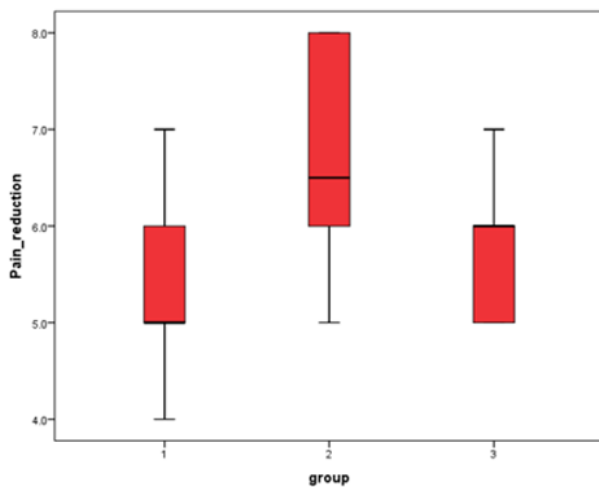
There was statistically significant difference found in the reduction of pain in 3 groups ( $p=0.01$ ). Post hoc analysis revealed significant difference between Group 1 and Group 2 with ( $p=0.003$ ). No differences were found between Group 1 and 3 and Group 2 and 3. Maximum reduction was seen in Group 2 with mean score of 6.6 (SD=1.17) [Table 1, Graph 1]. Overall success rate of IANB was found to be 66.6%. The success rate in Groups 1, 2 and 3 were 50%, 80% and 70% respectively [Graph 2]. However, no statistical significance was obtained in the success rates in the three groups ( $p=0.35$ ). No association of age, sex, tooth nomenclature and number of canals was seen with reduction in pain nor with success rate in the three groups.

**Table 1:** Difference between reduction of pain in different Groups

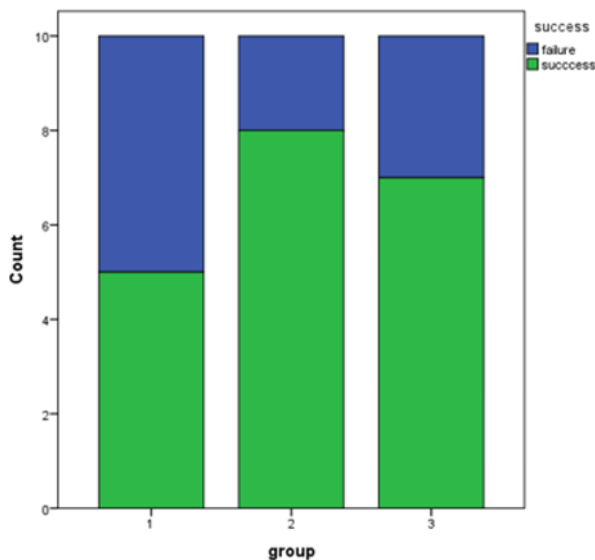
Groups	N	Mean	Std. Deviation
1	10	5.200	.9189
2	10	6.600	1.1738
3	10	5.800	.7888
Total	30	5.867	1.1059

## 4. Discussion

Mandibular molars are most susceptible to develop dental caries because of their early eruption pattern. Macek et



Graph 1: Difference between reduction of pain in different groups



Graph 2: Depicting the success rate in different groups

al. confirmed that the lower molars are the most severely affected teeth in the entire dentition.<sup>11</sup> An inferior alveolar nerve block (IANB) is the standardized injection technique used for anesthetizing mandibular molars. Predictable anesthesia is an essential requirement for both the patient and dentist. The patient's opinion about his dental treatment is closely related to the local anesthesia experiences he has had. However, an IANB does not always result in successful pulpal anesthesia, especially in patients with symptomatic irreversible pulpitis (SIP).<sup>12</sup> Because during inflammation specific inflammatory mediators like Bradykinin, Prostaglandin E2 gets activated and they alter the functional activity of nerves by reducing their firing

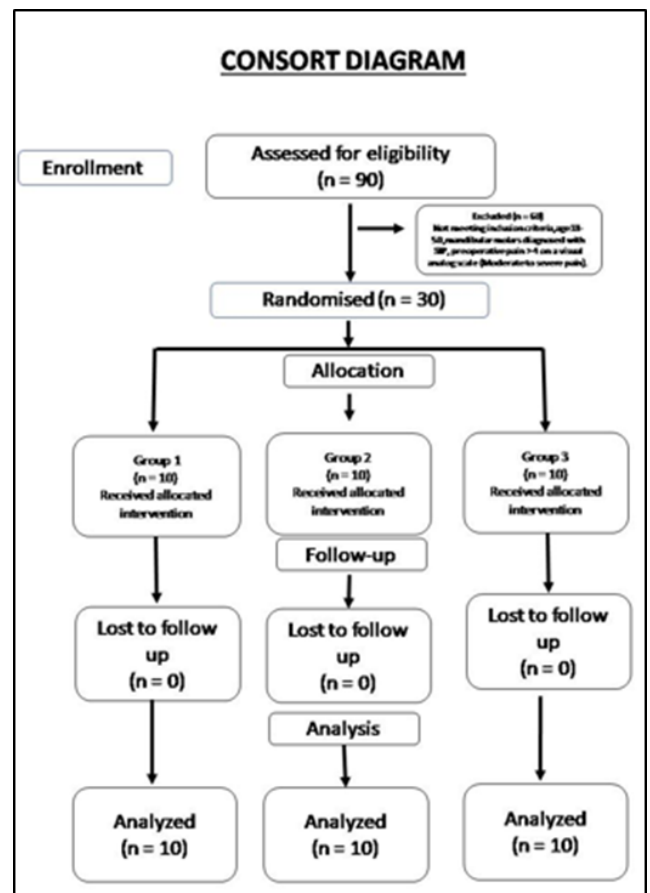
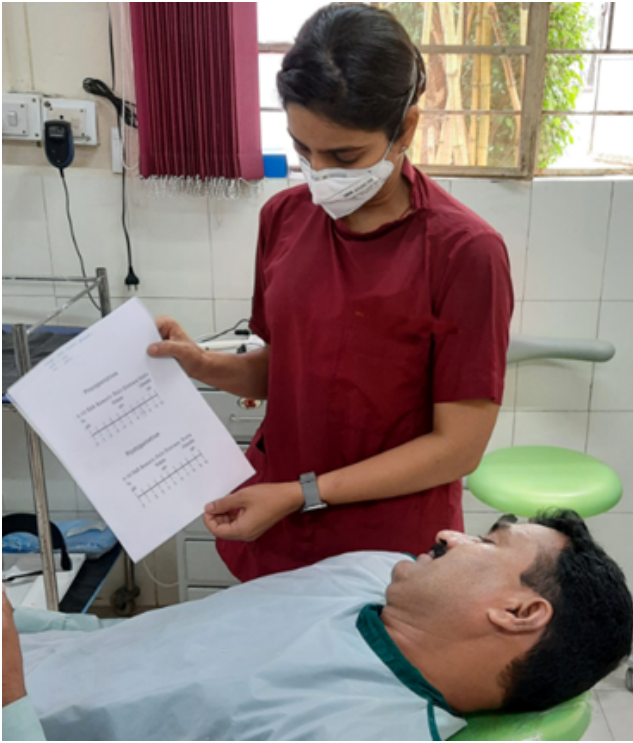
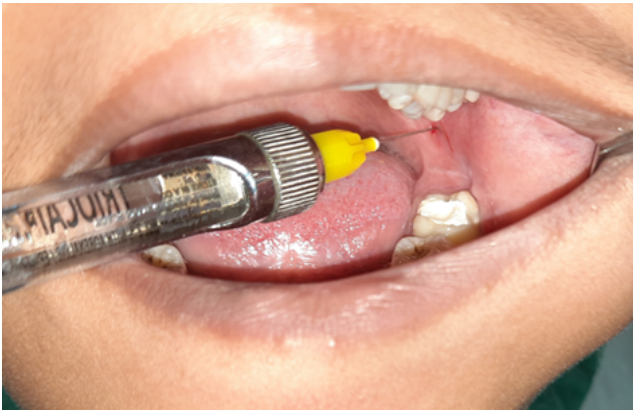
Fig. 1: Consort

threshold.<sup>13</sup> Various techniques are in current use to anesthetize the Inferior alveolar nerve. Each technique has its own advantages and disadvantages. Apart from conventional technique one of the other recognized technique is Gow-Gates technique. Though it is reported to have higher success rates, the onset of anesthesia is very slow. Agren and Danielson stated that the latency can be from 10 to 20, even to 30 min, and in rare cases to 45 min.<sup>14</sup> Malamed reported when the Gow-Gates technique is administered by inexperienced dental surgeons, it can produce more number of failures and complications than conventional techniques.<sup>15</sup> Manifold approaches have been tried to enhance the success rate of IANBs but none of these approaches could provide 100 % success rate especially in cases with SIP. Aggarwal et al compared the efficacy of 1.8 mL and 3.6 mL 2% lidocaine with 1:200,000 epinephrine for IANBs in patients with SIP and reported that increasing the volume of 2% lidocaine to 3.6 mL improved the success rate compared with 1.8 mL.<sup>16</sup> So in the present study 3.6 ml was the chosen volume. Various clinical and experimental studies have highlighted the role of cryo-irrigation in controlling post-operative pain after endodontic therapy. Keskin et al. evaluated the effect of

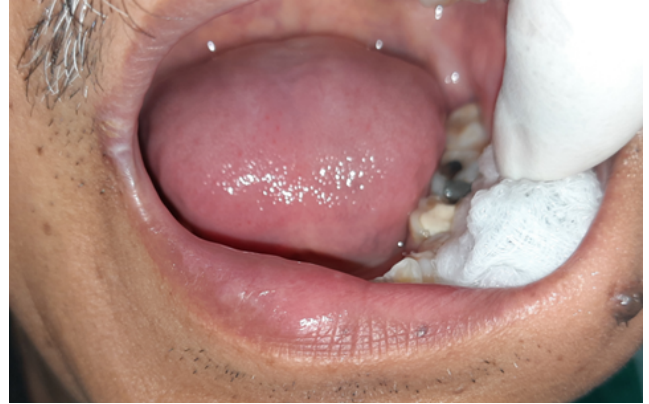

**Fig. 2:** Recording preoperative pain on a 0-10 Numeric visual analog scale



**Fig. 3:** Standard IANB procedure

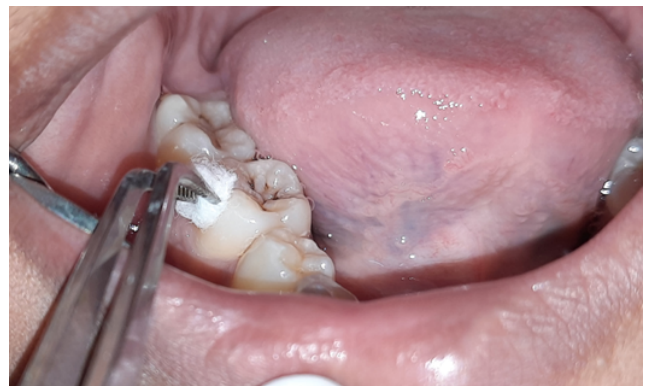using cold saline solution ( $2.5\text{ }^{\circ}\text{C}$ ) as a final irrigant on postoperative pain and found it to be extremely effective.<sup>17</sup> In a study by Emad et al the effect of different irrigation protocols on interleukin 6 expression was evaluated, the results showed all irrigation protocols that used 2–5 mL cold irrigant resulted in a significant reduction of pain score and the lowest expression of interleukin 6.<sup>18</sup> Although the effect of cryotherapy was evaluated on postoperative pain, very few studies in the literature evaluated the effect of cryotherapy on the reduction in pain and success rate of IANBs. Based on this information, the present randomized



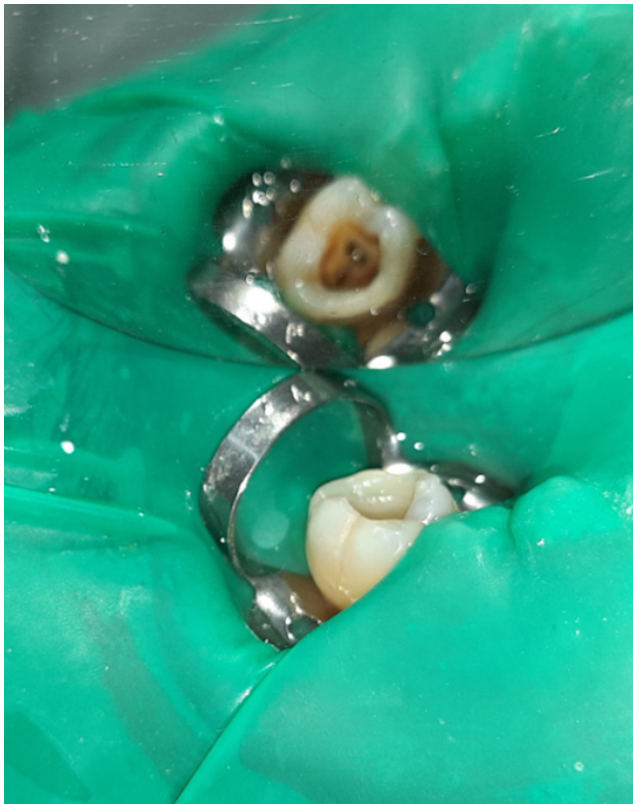**Fig. 4:** Applying cryotherapy with small ice packs (wrapped in sterile gauze)



**Fig. 5:** Endo ice

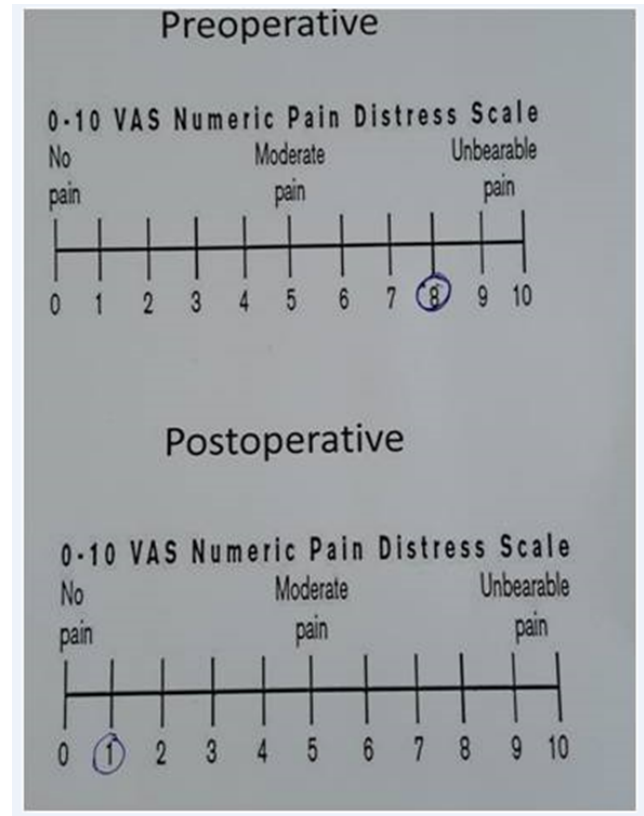


**Fig. 6:** Applying Endo ice with #2 cotton pellet



**Fig. 7:** Deroofing of pulp chamber after rubber dam application

controlled trial was conducted. Cryotherapy in endodontics has also been used as a diagnostic tool for pulp vitality testing by means of an easily available device called Endo ice which reaches very low temperatures, even lower than those produced by dry ice and ethyl chloride.<sup>19</sup> Jones reported that the type of carrier used with Endo ice may also affect the results of thermal test. He concluded that a #2 cotton pellet (approx. 6 mm in diameter) is the most effective way to deliver the refrigerant to the test site.<sup>20</sup> So, in the present study we delivered the refrigerant to the test site with the help of a cotton pellet. In a study by C. A. Herrero de Morais et al. tetrafluoroethane (Endo-Ice Green) and the propane-butane mixture (Endo-Frost) presented the lowest temperatures among the refrigerant sprays tested when measured immediately after application on a cotton swab.<sup>21</sup> Most recently, Topçuoğlu et al studied the effect of preoperative intraoral cryotherapy application on the success rate of inferior alveolar nerve blocks. They found that use of intraoral cryotherapy increased the potency of inferior alveolar nerve blocks, especially in teeth with symptomatic irreversible pulpitis.<sup>9</sup> Vera et al stated that the optimal application time of cryotherapy depends on the nature of the tissue. However, when minimal fat and muscle are present, a cryotherapy application for 5 minutes is recommended.<sup>22</sup> So in accordance with above mentioned study the sterile gauze packs were applied for



**Fig. 8:** Recording Numeric Visual Analog Scale score intraoperatively

only 5 minutes. Cryotherapy slows down neural signals and reduces the release of the chemical mediators that are responsible for pain conduction.<sup>23</sup> These effects could explain the increased effectiveness of the IANB in Group 2 in the present study. Morais et al. evaluated the temperature drop in human coronal dental pulp in incisor teeth treated with different refrigerant sprays and found that treating the tooth surface with Endo-Ice for 10s resulted in drop of pulpal temperature by 9.6 °C. Perhaps in our study, the increased residual dentin thickness of the molars could have contributed to the reduced thermal conductivity of dentin resulting in inadequate cooling.<sup>21</sup> hence not much reduction in pain. Pantera et al. pointed out that the exposure time in cold testing is only a few seconds until the patient complains and then it is removed, and that this period is not enough to produce hypothermia-associated anesthesia.<sup>24</sup> For the hypothermia associated anesthesia to occur the temperature drop should reach the pulp-dentin complex. So that's why in the present study Endo ice refrigerant spray was used for 10 seconds. There are many Instruments for pain-intensity assessment like Visual Analogue Scale/Graphic Rating Scale, verbal rating scale, Numerical rating scale, Pain-O-meter. In several investigations, VAS has shown to be valid and sensitive to treatment effects and to have ratio

scales qualities.<sup>25</sup> Moreover, VAS is a simple, chairside, subjective way of assessing pain and has been used in many previous studies for evaluating endodontic pain. The demographic data (sex, age, and preoperative pain) did not differ between the groups. Therefore, it could be said that these factors had no effect on the findings of the current study.

## 5. Strength and Limitations

Strength of this study is the standardization of the procedure which was done and the bias was eliminated by performing blinding of assessor to the intervention performed. Limitations of present study includes a small sample size and a subjective pain assessment criteria. Moreover, different pain thresholds among the patients may affect VAS values.

## 6. Clinical Significance

Based on the results obtained, it can be concluded that ice pack wrapped in sterile gauze can serve as an adjunct to Inferior alveolar nerve block in patients with symptomatic irreversible pulpitis.

## 7. Conclusion

Both the techniques of intraoral cryotherapy showed more reduction in pain and increased success rate of IANB in patients with symptomatic irreversible pulpitis. Better results were obtained with ice packs wrapped in sterile gauze. However, Supplemental anesthesia techniques may still be required to achieve profound pulpal anesthesia in many cases.

## 8. Conflict of Interest

The authors declare that there is no conflict of interest.

## 9. Source of Funding

None.

## References

1. Quinn CL. Injection techniques to anesthetize the difficult tooth. *J Calif Dent Assoc.* 1998;26(9):665–7.
2. Subbiya A, Vikash R, Anuradha B, Mitthra S. Failure Of Inferior Alveolar Nerve Block And How To Overcome It: A Review. *Eur J Mol Clin Med.* 2020;7(5):1266–69.
3. Dunbar D, Reader A, Nist R, Beck M, Meyers WJ. Anesthetic efficacy of the intraosseous injection after an inferior alveolar nerve block. *J Endod.* 1996;22(9):481–6.
4. Nusstein J, Claffey E, Reader A, Beck M, Weaver J. Anesthetic effectiveness of the supplemental intraligamentary injection, administered with a computer-controlled local anesthetic delivery system, in patients with irreversible pulpitis. *J Endod.* 2005;31(5):354–8.
5. Modabber A, Rana M, Ghassemi A, Gerressen M, Gellrich NC, Hölzle F, et al. Three-dimensional evaluation of postoperative swelling in treatment of zygomatic bone fractures using two different cooling therapy methods: a randomized, observer-blind, prospective study. *Trials.* 2013;14:238. doi:10.1186/1745-6215-14-238.
6. Watkins AA, Johnson TV, Shrewsbury AB, Nourparvar P, Madni T, Watkins CJ, et al. Ice packs reduce postoperative midline incision pain and narcotic use: a randomized controlled trial. *J Am Coll Surg.* 2014;219(3):511–7.
7. Nadler SF, Weingand K, Kruse RJ. The physiologic basis and clinical applications of cryotherapy and thermotherapy for the pain practitioner. *Pain Physician.* 2004;7(3):395–9.
8. George GK, Sanjeev K, Sekar M. An in vitro evaluation of the effect of deep dry cryotreatment on the cutting efficiency of three rotary nickel titanium instruments. *J Conserv Dent.* 2011;14(2):169–72.
9. Topçuoğlu HS, Arslan H, Topçuoğlu G, Demirbuga S. The Effect of Cryotherapy Application on the Success Rate of Inferior Alveolar Nerve Block in Patients with Symptomatic Irreversible Pulpitis. *J Endod.* 2019;45(8):965–9.
10. Koteeswaran V, Ballal S, Natanasabapathy V, Kowsky D. Efficacy of Endo-Ice followed by intrapulpal ice application as an adjunct to inferior alveolar nerve block in patients with symptomatic irreversible pulpitis—a randomized controlled trial. *Clin Oral Investig.* 2019;23(9):3501–7.
11. Macek MD, Beltrán-Aguilar ED, Lockwood SA, Malvitz DM. Updated comparison of various morphological types of permanent teeth. *J Public Health Dent.* 2003;63(3):174–82. doi:10.1111/j.1752-7325.2003.tb03496.x.
12. Gade V, Barfiwala D, Asani R, Gawande R, Gade J. Cryotherapy: An Emerging Trend in the Field of Endodontics. *Int J Drug Res Dent Sci.* 2020;2(3):70–6.
13. Suda H, Ikeda H. The circulation of the pulp. Chicago: Quintessence Publications; 2002.
14. Agren E, Danielsson K. Conduction block analgesia in the mandible. A comparative investigation of the techniques of fischer and gow-gates. *Swed Dent J.* 1981;5(3):81–90.
15. Malamed SF. The gow-gates mandibular block. Evaluation after 4,275 cases. *Oral Surg Oral Med Oral Pathol.* 1981;51(5):463–7.
16. Aggarwal V, Singla M, Miglani S, Kohli S, Singh S. Comparative evaluation of 1.8 mL and 3.6 mL of 2% lidocaine with 1:200,000 epinephrine for inferior alveolar nerve block in patients with irreversible pulpitis: a prospective, randomized single-blind study. *J Endod.* 2012;38(6):753–6.
17. Keskin C, Özdemir Ö, Uzun İ, Güler B. Effect of intracanal cryotherapy on pain after single-visit root canal treatment. *Aust Endod J.* 2017;43(2):83–8.
18. Emad A, Abdelsalam N, Fayyad DM. Influence of intracanal cryotherapy on postendodontic pain and interleukin-6 expression using different irrigation protocols: A randomized clinical trial. *Saudi Endod J.* 2021;11(2):246–51. doi:10.4103/sej.sej\_203\_20.
19. Hsiao-Wu GW, Susarla SM, White RR. Use of the cold test as a measure of pulpal anesthesia during endodontic therapy: a randomized, blinded, placebo-controlled clinical trial. *J Endod.* 2007;33(4):406–10.
20. Jones DM. Effect of the type carrier used on the results of dichlorodifluoromethane to teeth. *J Endod.* 1999;25(10):692–4. doi:10.1016/S0099-2399(99)80358-6.
21. de Morais C, Bernardineli N, Lima WM, Cupertino RR, Guerisoli DZ, Guerisoli DM. Evaluation of the temperature of different refrigerant sprays used as a pulpal test. *Aust Endod J.* 2008;34(3):86–8. doi:10.1111/j.1747-4477.2007.00077.x.
22. Vera J, Ochoa J, Romero M. Intracanal cryotherapy reduces postoperative pain in teeth with symptomatic apical periodontitis: a randomized multicenter clinical trial. *J Endod.* 2018;44(1):4–8. doi:10.1016/j.joen.2017.08.038.
23. Bleakley K, Mcdonough S, Macauley D. The use of ice in the treatment of acute soft tissue injury: a systematic review of randomized controlled trials. *Am J Sports Med.* 2004;32(1):251–61. doi:10.1177/0363546503260757.

24. Pantera EA, Anderson RW, Pantera CT. Reliability of electric pulp testing after pulpal testing with dichlorodifluoromethane. *J Endod.* 1993;19(6):312–4.
25. Korff MV, Jensen MP, Karoly P. Assessing global pain severity by self-report in clinical and health services research. *Spine (Phila Pa 1976).* 2000;25(24):3140–51. doi:10.1097/00007632-200012150-00009.

**Poonam Prakash**, Associate Professor

**Cite this article:** Gupta R, Prakash P. Cryotherapy as an adjunct to inferior alveolar nerve block in Symptomatic Irreversible Pulpitis: A randomised controlled clinical trial. *IP Indian J Conserv Endod* 2022;7(1):16-23.

### **Author biography**

**Richa Gupta**, Assistant Professor