

Content available at: <https://www.ipinnovative.com/open-access-journals>

IP Indian Journal of Conservative and Endodontics

Journal homepage: <https://www.ijce.in/>

Case Report

Endodontic management of a case of radix entomolaris: A case report

Priyanka Shorey^{1,*}, Kitty Sidhu¹

¹Dept. of Conservative Dentistry and Endodontics, Dr. Harvansh Singh Judge Institute of Dental Sciences and Hospital, Panjab University, Chandigarh, India



ARTICLE INFO

Article history:

Received 03-03-2022

Accepted 05-03-2022

Available online 31-03-2022

Keywords:

Entomolaris

Distolingual

Endodontics

ABSTRACT

Mandibular molars can have an additional root which can be located lingually (the radix entomolaris) or buccally (the radix paramolaris). An awareness and thorough understanding of this unusual anatomical feature can lead to a successful endodontic treatment of a tooth. This case report describes the case of a radix entomolaris found in a mandibular first molar and discusses its diagnosis and further endodontic management.

This is an Open Access (OA) journal, and articles are distributed under the terms of the [Creative Commons Attribution-NonCommercial-ShareAlike 4.0 License](https://creativecommons.org/licenses/by-nc-sa/4.0/), which allows others to remix, tweak, and build upon the work non-commercially, as long as appropriate credit is given and the new creations are licensed under the identical terms.

For reprints contact: reprint@ipinnovative.com

1. Introduction

Understanding of the anatomy and morphology of root canal system is of great significance for successful root canal treatment of teeth.¹ The complexity of the root canal system is the major cause of failure of endodontic treatment.² The failure of the operator to recognize the presence of the root canals, especially in teeth exhibiting anatomic irregularities or accessory or aberrant root canals, leads to the canals left untreated many times.¹ An awareness and understanding of the existence of unusual root canal morphology can lead to a successful endodontic treatment.³

Anatomical variations are an acknowledged characteristic of mandibular permanent molars. There are usually 2 roots one mesial and the other distal and 3 root canals in a permanent mandibular first molar, but the number of these roots and canals found can also vary.⁴ The most common variation is the presence of a distolingual supernumerary root called radix entomolaris (RE) in the mandibular first molar, mentioned first by Carabelli.⁵ This extra distolingual root is generally smaller than the

distobuccal root and is usually curved.⁴

Endodontic literatures report that the incidence of Radix entomolaris in permanent mandibular first molars range from 0%-43.7%, with highest prevalence among Mongolian and Eskimo traits. Even though it has high prevalence in these traits, its incidence among the Indian population is found to be 0.2% which is quite low.⁴ Hence, identification and treatment of RE is important because a missed canal serves as a source of infection and can compromise the treatment outcome.² This is a case report of diagnosis and endodontic treatment of a mandibular first molar with radix entomolaris.

2. Case Report

A 20-year-old male patient was referred to the Department of Conservative Dentistry and Endodontics, Dr. Harvansh Singh Judge Institute of Dental Sciences and Hospital, Panjab University, Chandigarh with the chief complaint of spontaneous pain in the lower right back region for 5 days. The pain aggravated on taking cold and hot food items and upon mastication. There was no significant medical history. Clinical examination revealed a deep occlusal carious lesion in relation to mandibular right first molar (tooth #46).

* Corresponding author.

E-mail address: shoreypriyanka@gmail.com (P. Shorey).

The tooth was tender to percussion and palpation. There was no mobility, and periodontal probing was within the physiological limits. An intense and prolonged response was seen on performing thermal and electric pulp tests. The preoperative intraoral periapical radiograph revealed deep occlusal caries approximating the pulp space. Apart from this, the radiograph also showed the presence of an additional distal root in relation to tooth #46. Buccal object rule (SLOB technique) confirmed the additional root as distolingual root (RADIX ENTOMOLARIS) (Figure 1). Based on clinical and radiographic findings, the diagnosis of symptomatic irreversible pulpitis of tooth#46 was made and root canal treatment was planned for the involved tooth.

An inferior alveolar nerve block was performed with 1.8 mL of 2% lidocaine containing 1: 200,000 epinephrine followed by buccal infiltration (1.8 mL) of the same anesthetic solution. Access cavity was prepared after isolating the tooth under rubber dam. Modification of access cavity was done from triangular to trapezoidal form to locate the fourth canal present. DG16 endodontic explorer was used to locate the canal orifices, which revealed two mesial and two distal orifices, hence confirming the presence of an additional distal canal. (Figure 5) The pulpal tissue remnants were extirpated from the canals using K- files no.10 & no.15. Coronal flaring was accomplished with Gates Glidden drills. And then apex locator was used to determine the working length. To verify the working length a radiograph is taken with a mesial angulation to confirm the presence of extra distolingual root (Figure 2). Both the mesial and distal canals were cleaned and shaped with the use of rotary Nickle-Titanium instruments in a crown-down manner till size 25/04. Irrigation was done with 3% sodium hypochlorite solution, 17% EDTA, and 2% chlorhexidine gluconate solution as the final irrigant. A calcium hydroxide dressing was placed inside the canals. Zinc oxide eugenol restoration was given to restore the access cavity and the patient was scheduled for appointment after one week.

After one week, the patient was asymptomatic. Master cone radiograph was taken. (Figure 3) The canals were dried with paper points and obturated using lateral condensation technique with 25/04 gutta percha cones and AH Plus resin sealer.

After that composite resin was used to restore the access cavity and post obturation radiograph was taken. (Figure 4)

3. Discussion

Radix entomolaris (RE), in this patient, characterized by the presence of an additional distolingual root was reported in the preoperative periapical radiograph. This emphasizes the significance of preoperative radiograph in endodontic treatment.⁶In this case, 1 mesial root with 2 canals and 2 distal roots with one canal each was present in the mandibular first molar. The roots and canals of mandibular

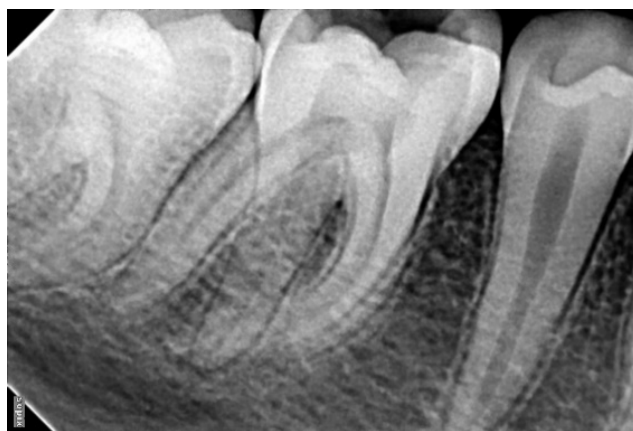

Fig. 1:

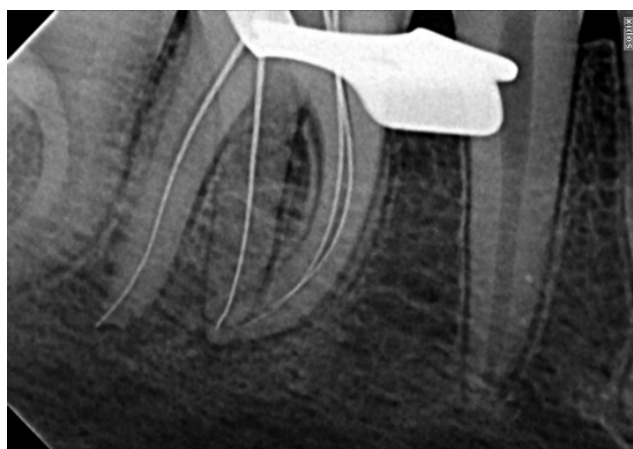


Fig. 2:

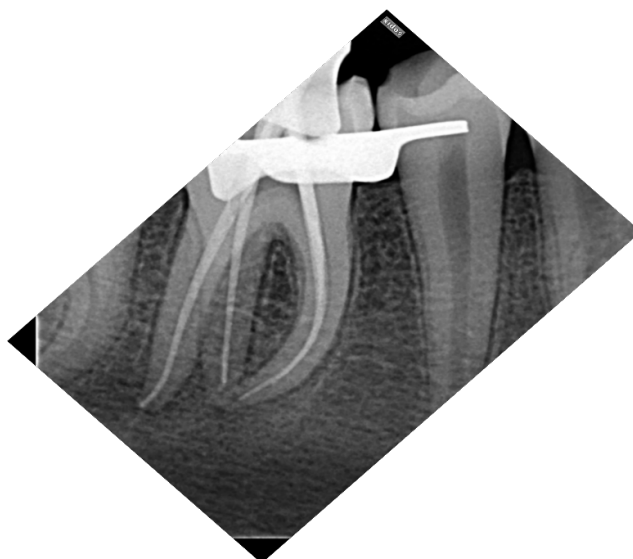

Fig. 3:

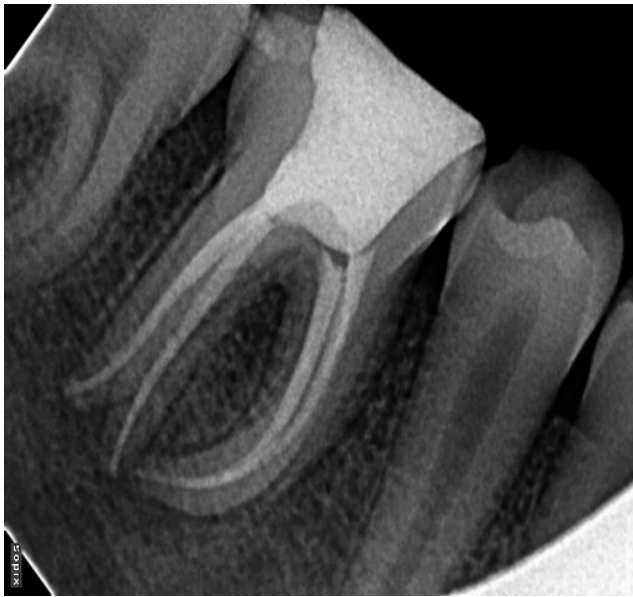

Fig. 4:

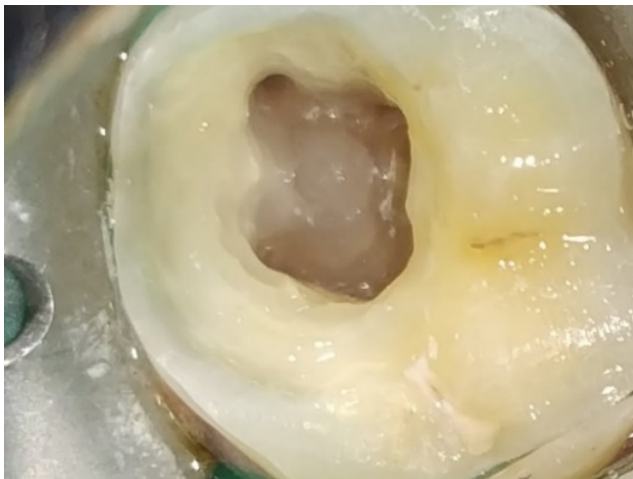

Fig. 5:

permanent first molars have several typical anatomical features, as well as a great number of anomalies.⁴ Radix entomolaris characterized by the presence of 2 distal roots, with an additional distolingual root, is not a usual morphologic variant.⁷ A maximum frequency of 3% is found in African populations,⁸ whereas the frequency is less than 5% Eurasian and Indian populations.⁹ In populations with Mongoloid traits, RE occurs with a frequency ranging from 5% to more than 30%.¹⁰⁻¹³

Based on the curvature in the bucco-lingual orientation, Radix entomolaris was classified by De Moor et al¹⁴ into three types:

Type I: A straight root/root canal.

Type II: A root canal with initial curvature that continues as a straight root.

Type III: A root canal with a curvature in the coronal third followed by a second curve from the middle third to the apical third.

Carlsen and Alexandersen¹⁵ classified RE according to the location of the cervical part: Types A, B, C, and AC.

Type A: The distal part of the root has three cone-shaped macrostructures, a lingual, a medial, and a facial. Either the lingual structure is separate while the medial and facial structures are nonseparate, or all three macrostructures are non-separate.

Type B: The distal part of the root has two cone-shaped macrostructures, lingual and facial ones of nearly the same size. The structures are either separate or non-separate.

Type C: The cervical part is located mesially.

Type AC: The cervical part is located centrally.

It has been reported that RCT in mandibular first molars have a significantly lower success rate than the other teeth.

Examining the radiograph carefully helps to identify the presence of hidden extra root.¹⁶ Taking a second radiograph from a mesial or a distal angle (30°) can help visualize the radix entomolaris. Different methods can also be used during clinical examination to identify the extra canal present. These include visualization of the dentinal map and bleeding points in the canal, using DG-16 explorer, micro-opener, toughing of the grooves with ultrasonic tips, use of 1% methylene blue dye to stain the pulp chamber, performing champagne bubble test and using magnifying loupes and microscopes. Magnetic resonance microscopy and micro computed tomography can also be done if unable to locate the canal by above methods.¹

This extra root is smaller than the distobuccal (DB) root and is usually curved, so requires special attention during root canal treatment.⁷ Chances of iatrogenic errors such as ledge formation, straightening of the canal leading to loss of working length, zipping, transportation or even perforation are there in these cases. Using nickel-titanium rotary endodontic files allows a more centered canal preparation shape in these cases.¹⁷ After relocation and orifice enlargement of the RE, exploration of the canals with small size files (size 10 or less) along with measurement of root canal length radiographically and determination of the root curvature, as well as glide path creation before preparation, are steps that should be followed to avoid procedural errors.³

4. Conclusion

Proper diagnosis of a radix entomolaris or paramolaris before initiating endodontic treatment is paramount in order to avoid 'missed' canals. The additional root present in such cases can be identified with the help of preoperative periapical radiographs taken at two different angulations. Application of the proper knowledge can help us to perform root canal treatment in a radix entomolaris accordingly and decreases the chances of iatrogenic errors.

5. Conflict of Interest

The authors declare that there is no conflict of interest.

6. Source of Funding

None.

References

1. Arafath MY, Subair KA, Shashikala K. Radix entomolaris: an endodontic challenge—case reports. *Int J Oral Care Res.* 2014;2(1):35–8.
2. Hannah R, Kandaswamy D, Jayaprakash N. Endodontic management of a mandibular second molar with radix entomolaris: a case report. *Restor Dent Endod.* 2014;39(2):132–6. doi:10.5395/rde.2014.39.2.132.
3. Calberson FL, De Moor R, Deroose CA. The radix entomolaris and paramolaris: clinical approach in endodontics. *J Endod.* 2007;33(1):58–63.
4. Pai V, Singh V, Vaitheeswaran MB, Thapa A, Kundabala M. Radix entomolaris: A case report. *J Nepal Dent Assoc.* 2010;11(2):162–5.
5. Carabelli G. Systematisches Handbuch der Zahnheilkunde, 2nd Edn. Wien : Bei Braumüller und Seidel; 1844. Available from: <http://resource.nlm.nih.gov/67610740RX1>.
6. Segura-Egea JJ, Jiménez-Pinzón A, Jv RS. Endodontic therapy in a 3-rooted mandibular first molar: importance of a thorough radiographic examination. *J-Can Dent Assoc.* 2002;68(9):541–5.
7. Tu MG, Huang HL, Hsue SS, Hsu JT, Chen SY, Jou MJ, et al. Detection of permanent three-rooted mandibular first molars by cone-beam computed tomography imaging in Taiwanese individuals. *J Endod.* 2009;35(4):503–7.
8. Sperber GH, Moreau JL. Study of the number of roots and canals in Senegalese first permanent mandibular molars. *Int Endod J.* 1998;31(2):117–22.
9. Tratman EK. Three-rooted lower molars in man and their racial distribution. *Br Dent J.* 1938;64:264–74.
10. Curzon ME. Three-rooted mandibular permanent molars in English Caucasians. *J Dent Res.* 1973;52(1):181. doi:10.1177/00220345730520011901.
11. Turner CG. Three-rooted mandibular first permanent molars and the question of American Indian origins. *Am J Phys Anthropol.* 1971;34(2):229–41.
12. Yew SC, Chan K. A retrospective study of endodontically treated mandibular first molars in a Chinese population. *J Endod.* 1993;19(9):471–3.
13. Reichart PA, Metah D. Three-rooted permanent mandibular first molars in the Thai. *Community Dent Oral Epidemiol.* 1981;9(4):191–3.
14. De Moor R, Deroose CA, Calberson FL. The radix entomolaris in mandibular first molars: an endodontic challenge. *Int Endod J.* 2004;37(11):789–99.
15. Carlsen OL, Alexandersen V. Radix entomolaris: identification and morphology. *Eur J Oral Sci.* 1990;98(5):363–73.
16. Kamath U, Sheth H, Mohan N, Reddy D. Endodontic management of radix entomolaris. *IJADS.* 2015;2(1):15–9.
17. Bolla N, Naik BD, Kavuri SR, Sriram SK. Radix entomolaris: a case report. *Endodontology.* 2013;25:121–4.

Author biography

Priyanka Shorey, Post Graduate Student

Kitty Sidhu, Associate Professor

Cite this article: Shorey P, Sidhu K. Endodontic management of a case of radix entomolaris: A case report. *IP Indian J Conserv Endod* 2022;7(1):39–42.