

Content available at: <https://www.ipinnovative.com/open-access-journals>

IP Indian Journal of Conservative and Endodontics

Journal homepage: <https://www.ijce.in/>

Case Report

Esthetic and functional rehabilitation of mutilated maxillary anterior teeth: A case series

Tushar Kanti Majumdar^{1,*}, Moumita Khatua¹, Paromita Mazumdar¹, Sayantan Mukherjee¹

¹Dept. of Conservative Dentistry and Endodontics, Guru Nanak Institute of Dental Sciences and Research, Kolkata, West Bengal, India



ARTICLE INFO

Article history:

Received 28-02-2022

Accepted 02-03-2022

Available online 31-03-2022

Keywords:

Laser

Gingivectomy

Cast post and Core

Aesthetics

Porcelain fused to metal

ABSTRACT

An endodontically treated anterior tooth requires extracoronary restoration when the tooth structure is weakened or lost due to caries, placement of previous restorations and/or discoloured. The reduced tooth structure makes retention of extracoronary restoration difficult. The purpose of post is to provide retention for the core restoration, which replaces lost coronal structure. This article describes restoration of mutilated maxillary anterior teeth by using cast post and core, followed by porcelain fused to metal restorations.

This is an Open Access (OA) journal, and articles are distributed under the terms of the [Creative Commons Attribution-NonCommercial-ShareAlike 4.0 License](https://creativecommons.org/licenses/by-nc-sa/4.0/), which allows others to remix, tweak, and build upon the work non-commercially, as long as appropriate credit is given and the new creations are licensed under the identical terms.

For reprints contact: reprint@ipinnovative.com

1. Introduction

An endodontically treated tooth structure has considerable tooth loss because of carious decay and fractured coronal structure which makes retention of subsequent restorations more challenging.¹ When substantial amount of coronal structure is missing, a post and core restoration is indicated. The main purpose of this procedure is to provide retention for the core restoration, which replaces lost coronal structure.² Anterior teeth with more than 50% tooth structure loss, post and core followed by full coverage restoration is mandatory.³ A wide variety of post systems are available ranging from traditional cast metal posts to newer fiber posts. This case series describes restoration of mutilated maxillary anterior teeth by using cast post and core, followed by porcelain fused to metal restorations. Signed informed consent was taken from each patient and oral prophylaxis was carried out.

2. Case Report I

A 34-year-old female patient reported to the Department of Conservative Dentistry and Endodontics, Guru Nanak Institute of Dental Sciences and Research, Kolkata with the chief complaint of broken upper anterior teeth and wanted to get restored. Patient gave a history of undergoing endodontic treatment with respect to 23 one week back. Intra oral clinical examination revealed that tooth 23 had subgingival fracture of crown, with significant destruction of hard tissue on distal aspect after endodontic treatment (Figure 1). Medical and personal history was non-contributory. Radiograph revealed well obturated root canal with 23. The treatment plan included:

1. Laser gingivectomy to increase the length of the crown with respect to 23.
2. Followed by cast post and core with respect to 23.
3. Porcelain fused to metal crown with respect to 23.

To increase the clinical height of the crown, gingivectomy was done by Denlase diode laser (650nm diode laser, 110~220V AC,) with output power 1mW

* Corresponding author.

E-mail address: tkmajumdar12@gmail.com (T. K. Majumdar).

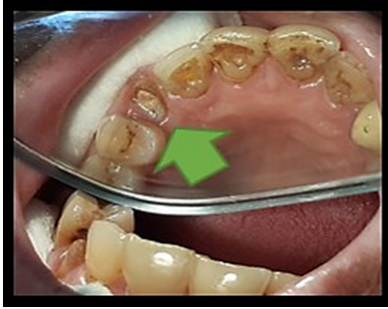

Fig. 1: Pre-operative clinical picture of root canal treated tooth-23

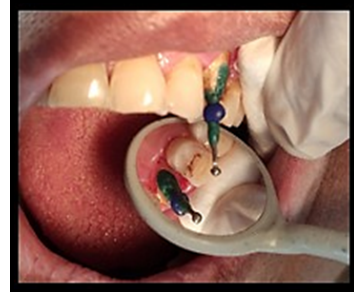

Fig. 5: Wax pattern taken-23

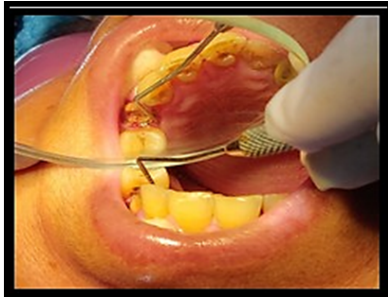

Fig. 2: Measurement of probing depth with periodontal probe-23.

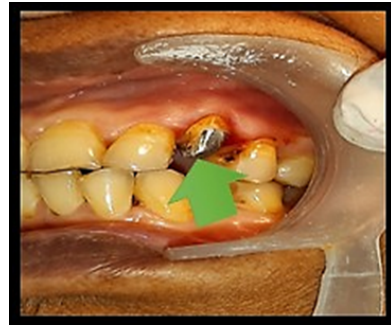

Fig. 6: Cementation of the cast post done-23.

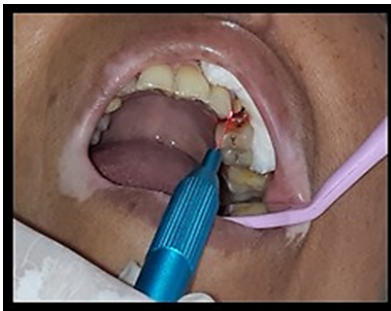

Fig. 3: Crown lengthening procedure done with Denlase diode laser-23.

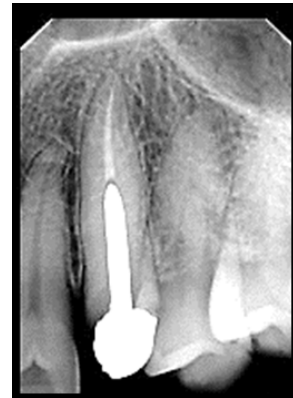


Fig. 7: Radiograph of custom cast post -23

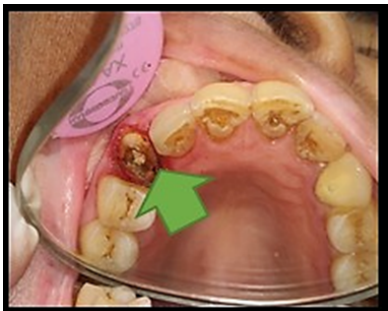

Fig. 4: Clinical picture of crown structure after laser treatment.

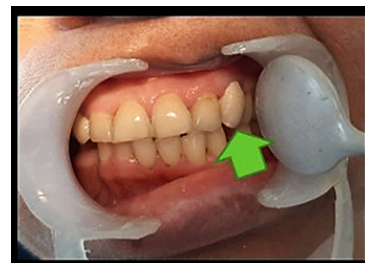

Fig. 8: Post-operative clinical image- 23

50/60Hz, 20% water/30% air, pulse duration of 140 μ s (Figures 2, 3 and 4).

The area was covered with surgical pack for 1 week. Patient was provided with 0.2% chlorhexidine gluconate oral rinse. After 1 week, post space was prepared using peeso-reamer no. 1-2-3 in a sequential manner, leaving 5 mm of apical gutta-percha to maintain the apical seal with respect to 23. Core ferrule was prepared and post space wax pattern was fabricated using Type II inlay wax (GC Corp., Tokyo, Japan) (Figure 5). Cast metal post and core was prepared and was luted with Glass Ionomer cement (Type 1) with respect to 23 followed by crown preparation (Figures 6 and 7). Rubber base impression was made with heavy body (putty material) and light body (3M ESPE) soft putty. Before proceeding for tooth preparation, shade was selected using Vitapan Classical shade guide (Vita Zahnfabrik, Germany). Thereafter, porcelain fused to metal crown was cemented in 23 (Figure 8). The patient reported with no discomfort on six months and one year follow-up.

3. Case Report II

A 45-year-old female patient reported to the Department of Conservative Dentistry and Endodontics, Guru Nanak Institute of Dental Sciences and Research, Kolkata with the complaint of broken and unesthetic appearance of upper anterior teeth. Intra oral clinical examination revealed Ellis class III fracture with respect to 22 with short clinical crown with more than 50% loss of crown structure (Figures 9 and 10). She had sustained trauma to her anterior teeth 6 years back. Medical and personal history was non-contributory. Canine Guided occlusion was present with adequate overjet and overbite. Radiograph revealed fractured tooth with 22. The treatment plan included:

1. Endodontic treatment with respect to 22, followed by
2. Laser gingivectomy to increase the length of the clinical crown.
3. Followed by cast post and core with respect to 22.
4. Porcelain fused to metal crown with respect to 22.

The working length of 15mm for 22 was determined using a radiograph for better resolution (Figure 11). Cleaning and shaping was done using ISO standardised K files in a step back technique, master apical file size was 50 and copious irrigation was done with 3% sodium hypochlorite, 0.9% normal saline alternatively throughout the procedure. Obturation was completed using gutta percha by cold lateral compaction technique (Figures 12 and 13). To increase the clinical height of the crown, gingivectomy was done by Denlase diode laser (650nm diode laser, 110 ~ 220V AC,) with output power 1mW 50/60Hz, 20% water/ 30% air, pulse duration of 140 μ s (Figures 14 and 15). The area was covered with surgical pack for 1 week. Patient was provided with 0.2% chlorhexidine gluconate oral rinse.

After 1 week, in 22 post space was prepared using peeso-reamer no. 1-2 in a sequential manner, leaving 4 mm of apical gutta-percha to maintain the apical seal. The apical seal and remaining endodontic obturation was confirmed on radiograph (Figure 16). Core ferrule was prepared and post space wax pattern was fabricated using Type II inlay wax (GC Corp., Tokyo, Japan) (Figure 17). Cast metal post and core was prepared and luted with Glass Ionomer cement (Type I) with respect to 22 followed by crown preparation (Figure 18). Rubber base impression was made with heavy body (putty material) and light body (3M ESPE) soft putty. Before proceeding for tooth preparation, shade was selected using Vitapan Classical shade guide (Vita Zahnfabrik, Germany). Thereafter, porcelain fused to metal crown was cemented with respect to 22 (Figures 19 and 20). The patient reported no discomfort on six months and one year follow-up.

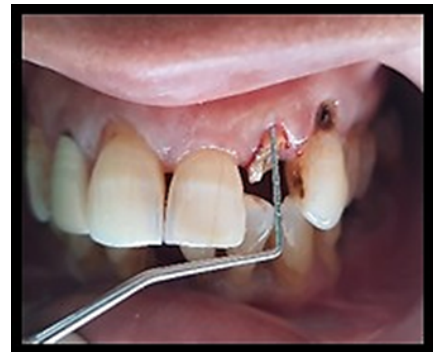

Fig. 9: Pre-operative clinical picture with respect to 22 with 2mm of crown structure.

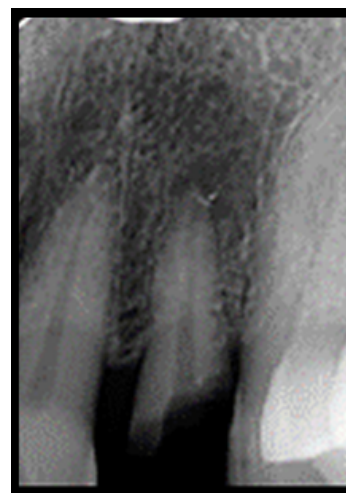

Fig. 10: Pre-operative radiograph- 22.

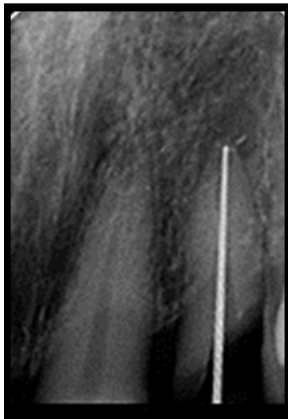


Fig. 11: Working length determination-22.

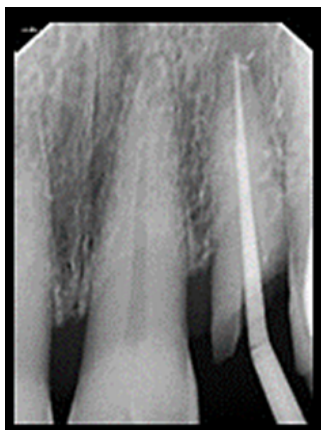

Fig. 12: Master cone gutta percha-22.

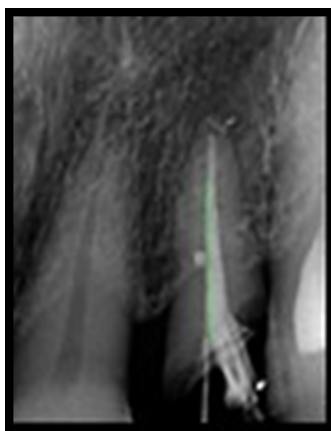

Fig. 13: Obturation by cold lateral compaction-22.

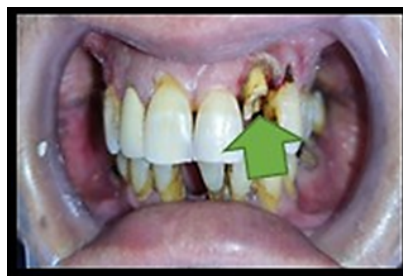

Fig. 14: Labial aspect after laser gingivectomy.

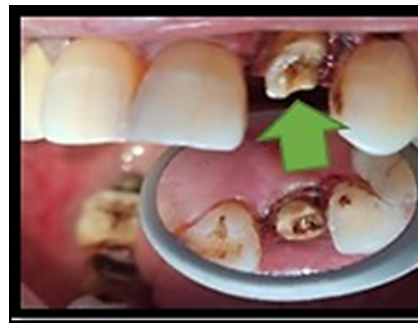

Fig. 15: Palatal aspect after laser gingivectomy.

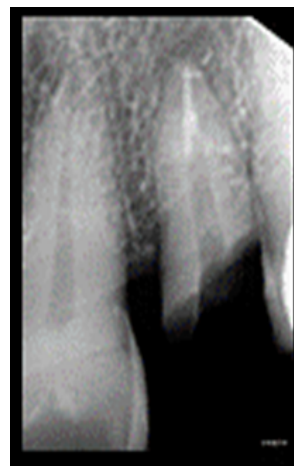


Fig. 16: Post space preparation-22

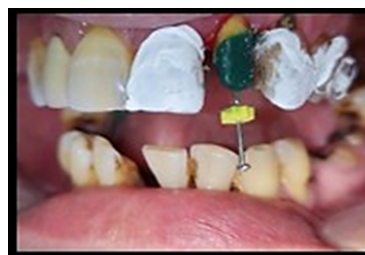

Fig. 17: Wax pattern fabrication-22

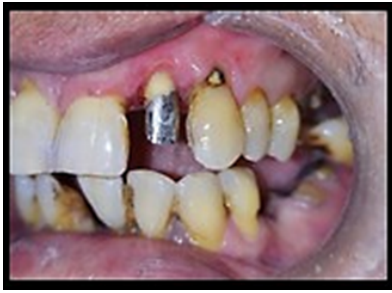

Fig. 18: Cementation of custom cast post -22.

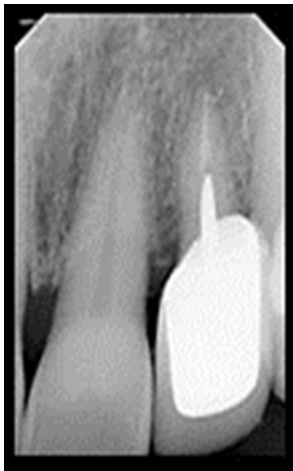

Fig. 19: Radiograph of custom post with PFM crown- 22.

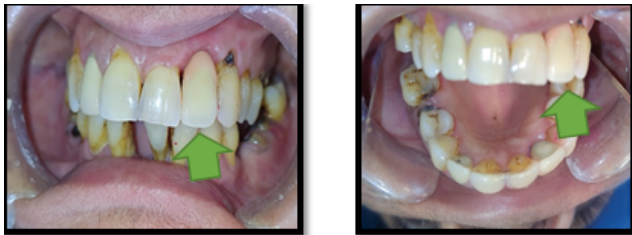

Fig. 20: Post-operative clinical image 22- Labial and palatal aspect.

4. Discussion

Grossly decayed, fractured endodontically treated tooth with less coronal tooth structure often poses a challenge while choosing an appropriate post-endodontic restorative material. For rehabilitation of traumatised anterior teeth, both aesthetic and mechanical aspects should be considered. Post and core is considered as the foundation restoration for such endodontically treated anterior fractured teeth followed by complete coverage crown. The main purpose of this procedure is to provide retention for the core restoration, which replaces lost coronal structure. Since patient had compromised tooth structure off less than 50% so custom post and core was planned along with laser gingivectomy to

increase the length of the crown. Moreover, in teeth with ovoid, elliptical or conical canal, as in the present case, custom cast post core restoration offer advantage in the form of precise fit with minimal luting cement interface and inherent antirotation mechanism.⁴ According to a study done by Gegauff AG, a 2 mm ferrule obtained by crown lengthening resulted in a reduction of static load fracture.⁵ The custom cast posts also have advantage of higher strength and minimal reduction of tooth material during root canal and crown preparation. Amount of remaining tooth structure is directly related to the strength of tooth. Therefore, the preservation of tooth structure is important for successful post and core restoration.⁶ The prefabricated posts like stainless steel, titanium, fiber posts (carbon, glass) and ceramic posts (Zirconia) are round in cross-section and may have different surface characteristics (serrated, smooth, threaded and roughened) with shapes as parallel and tapered and are provided with matching drills for post space creation. Hence, obtaining precise fit with these posts result in removal of more tooth material as compared to custom cast post and core. Moreover, an antirotation feature needs to be provided along with approximation and adaption to the morphology of the prepared canal.⁷

5. Conclusion

As there are several post and core options available, the treatment plan should be based on each individual's tooth condition, amount of coronal tooth structure present, success of endodontic treatment, root length and cross-section, tooth angulation, should be taken into account before selecting a particular post and core restoration. In this case series, considering the age and aesthetic concerns of the patient, a treatment was planned which was cost effective, had long lasting results and provided desirable aesthetics.

6. Conflict of Interest

The authors declare that there is no conflict of interest.

7. Source of Funding

None.

References

1. Rosenstiel SF, Land MF, Fujimoto J, Schrefler J. Contemporary Fixed Prosthodontics. 3rd Edn. USA: Missouri: Mosby; 2001.
2. Shillingburg HT, Hobo S, Whitsett LD, Jacobi R, Brackett SE. Fundamentals of Fixed Prosthodontics. 3rd Edn. Chicago: Quintessence Publishing; 1997.
3. Bonfante G. Fracture strength of teeth with flared root canals restored with glass fibre posts. *Int Dent J.* 2007;57(3):153–60.
4. Torbjörner A. A literature review on the prosthetic treatment of structurally compromised teeth. *Int J Prosthodont.* 2004;17(3):369–76.
5. Gegauff AG. Effect of crown lengthening and ferrule placement on static load failure of cemented cast post-cores and crowns. *J Prosthet Dent.* 2000;84(2):169–79.

6. Assif D, Bitenski A, Pilo R, Oren E. Effect of post design on resistance to fracture of endodontically treated teeth with complete crowns. *J Prosthet Dent.* 1993;69(1):36–40.
7. Goerig AC, Mueninghoff LA. Management of the endodontically treated tooth. Part I: concept for restorative designs. *J Prosthet Dent.* 1983;49(3):340–5.

Moumita Khatua, Post Graduate Trainee

Paromita Mazumdar, Professor and HOD

Sayantana Mukherjee, Professor

Author biography

Tushar Kanti Majumdar, Post Graduate Scholar

Cite this article: Majumdar TK, Khatua M, Mazumdar P, Mukherjee S. Esthetic and functional rehabilitation of mutilated maxillary anterior teeth: A case series. *IP Indian J Conserv Endod* 2022;7(1):43–48.