

Content available at: <https://www.ipinnovative.com/open-access-journals>

IP Indian Journal of Conservative and Endodontics

Journal homepage: <https://www.ijce.in/>

Review Article

Restoring non-restorable with the help of customized digital solutions: A review

Gaurav Gupta^{1,*}, D.K Gupta², Priyanka Gupta³, Kuldeep Singh Rana⁴,
Neeraj Chandra⁵, Parth Shah⁶¹Dept. of Pedodontics and Preventive Dentistry, Wisdom Dental Clinics, Jaipur, Rajasthan, India²Dept. of Oral and Maxillofacial Surgery, Wisdom Dental Clinics, Jaipur, Rajasthan, India³Dept. of Pedodontics and Preventive Dentistry, RUHSCDS Govt. Dental College, Jaipur, Rajasthan, India⁴Dept. of Conservative Dentistry and Endodontics, Govt. College of Dentistry, Indore, Madhya Pradesh, India⁵Dept. of Periodontics, Institute of Dental Sciences, Bareilly, Uttar Pradesh, India⁶Saachi Pediatric Hospital, Surat, Gujarat, India

ARTICLE INFO

Article history:

Received 22-04-2022

Accepted 24-05-2022

Available online 13-06-2022

Keywords:

Endodontically treated teeth

CAD/CAM

Crowns

Customized digital restoration

ABSTRACT

This article aims to provide a comprehensive literate review on endocrown / customized digital restoration and how they might be a better option for hopeless decayed tooth. Dentist might be hesitant to apply such a successful treatment option for grossly decayed /fractured /traumatic teeth in their clinical practice because it's not as widely used as other conventional methods. Here we review about innovative treatment approach for endodontically treated teeth, using a digital workflow with IOS and computer-aided design/computer-assisted manufacturing (CAD/CAM) fabrication of restoration. Endocrowns/ customized digital restoration constitutes a reliable approach for restoring severely damaged tooth as they are more precise, aesthetic and time saving.

This is an Open Access (OA) journal, and articles are distributed under the terms of the [Creative Commons Attribution-NonCommercial-ShareAlike 4.0 License](https://creativecommons.org/licenses/by-nc-sa/4.0/), which allows others to remix, tweak, and build upon the work non-commercially, as long as appropriate credit is given and the new creations are licensed under the identical terms.

For reprints contact: reprint@ipinnovative.com

1. Introduction

Restoration of endodontically treated teeth that are grossly destructed has been a challenge for many clinicians over years. Endodontically treated teeth exhibit various physiological alterations in dentin composition and microstructure which predispose tooth to multiple risk factors such as reduced retention/stability, increased tooth fragility, compromised substrate adhesion and eventually leading to failure of prosthesis.¹ Further studies reported and linked access preparation with decreased structural integrity which led to a higher occurrence of fractures in endodontically treated teeth compared with vital teeth.²

Need for replacement of crown /bridge /implant in grossly mutilated endodontically treated tooth is

challenging task for all clinical practitioners. This might be attributed to various physiological alterations in root canal treated tooth.³ Most commonly recommended treatment option for such cases associated with significant loss of two or more dentin walls is the placement of conventional post and core followed by a crown.⁴

However, there is need for definite core filling, particularly in cases of posterior teeth where masticatory forces are directed parallel to long axis of tooth. This is due to fact that use of intraradicular posts alone might not contribute to an increased retention of restoration, as stated in various studies.⁵ Yet, endocrowns/ customized restorations can replace need for post and core retention.⁶

Moreover, systematic review showed 94%–100% success rate of endocrowns/ customized restoration and higher fracture strength than with conventional treatments.⁷

* Corresponding author.

E-mail address: dr.gauravgupta99@gmail.com (G. Gupta).

Authors suggested that endocrowns/customized restoration may perform similarly or better than conventional treatments that use intraarticular posts, direct composite resin, or inlay/onlay restorations.

Endocrown/customized restoration is made from zirconia blocks material which is applied with resin cement to post endodontic teeth. This restoration is full occlusal coverage and takes advantage of pulp chamber to increase adhesive surface area. Materials used for manufacture of endocrown are feldspathic and glass-ceramic, hybrid composite resins, and computer-aided design and computer-aided manufacturing (CAD/CAM) zirconia.^{8,9} Computer-aided design (CAD) and computer-aided manufacturing (CAM) are digital technologies used to design, plan and ultimately create dental prosthodontics with 3D printing technology. With CAD/CAM, dentists can efficiently create dental crowns, teeth bridges, veneers, onlays, inlays, dentures, and dental implant-supported prostheses.

Endocrown/ customized restoration indications include loss of extensive tooth structure, small intermaxillary spaces where rehabilitation using pegs and crowns is not possible because of insufficient thickness of ceramic material, and cases where post use is contraindicated because there are anatomic variations of the roots.^{10,11}

In this article, we review for an innovative approach for treating endodontic treated tooth using a digital workflow with IOS and computer-aided design/computer-assisted manufacturing (CAD/CAM) fabrication of restoration.

2. Discussion

In today's adhesive dentistry era, endocrown/customized restoration can be considered as viable, conservative, and feasible alternative to conventional post and core restorations. It is fixed to a depulped posterior tooth, which is anchored to the internal portion of the pulp chamber and to cavity margins, thus obtaining micromechanical retention (provided by the pulpal walls), and micro retention (by adhesive cementation).^{12,13}

In addition, its easier technique, less clinical time, and better acceptance make it a superior option among the various treatment alternatives.¹⁴ The overall success rate of the endocrowns/customized restoration is very good, and clinical concept also appears to be simple and feasible, as stated by Bindl et al. In another 2-year evaluation clinical study, Bernhart et al¹⁵ concluded that endocrowns represent very promising treatment alternative for endodontically treated teeth.¹⁶ The endocrown/customized restoration fits perfectly with concept of biointegration and can be preferred choice for restoring posterior endodontically treated and badly destructed teeth. Endocrowns are especially indicated in cases of tooth with short, obliterated, dilacerated, fragile roots, and severely mutilated tooth.¹⁷

CAD-CAM system, with an estimated success of 90.5% for molars and 75% for premolars in 55 patients^{16,18}. According to Belleflamme et al., even in presence of extensive coronal tissue loss or occlusal risk factors, such as bruxism or unfavorable occlusal relationships, endocrowns could be a reliable approach to restore severely damaged teeth.¹⁹

2.1. An overview of dental CAD/CAM

All CAD/CAM systems have three functional components: data capture or scanning to capture and record data about oral environment (tooth preparation, adjacent teeth and occluding tooth geometry); CAD to design restoration to fit preparation and to perform according to conventional dental requirements; and CAM to fabricate restoration. The first and so far, only, commercially available in-office system is CEREC system (SIRONA). With this system, all three steps involved in automated production of restorations can be accomplished in a dental office. The dentist can prepare a tooth and, by selecting appropriate materials, can fabricate restoration (in house manufacturing) and seat it within single appointment all done chairside.²⁰ In a matter of less than 45 minutes, compliant, enjoyable, and acceptable results are achieved.

Conventional impression technique requires full mouth impression whereas, in digital impression, we need to take an impression of the particular arch /segment /quadrant we need to treat. The use of the digital intraoral impression technique eliminates need for conventional alginate impression. Conventional impressions are considered an unpleasant experience because they cause gagging due to which impression has to be repeated to get accurate result, thus switching to digital impression procedure, have long-term positive impact on patient perceptions of dental procedures.²¹ (Figure 1a,b,c,d,e)

It has been shown that endocrowns/customized restoration made of lithium disilicate-based zirconia are considered among the best restorative materials because of their adhesive properties also, they promoted micromechanical interlocking with resin cement^{22,23}. (Figure 2)

Customized digital approach is preparation of restoration uses minimally invasive technique only occlusal preparation is required with no labio-lingual and mesio-distal extensions. Customized digital restoration perfectly fit on endodontically treated tooth and occlusion is achieved with no adjustments required to be done on antagonist tooth.

2.2. Advantages and disadvantages of CAD CAM

CAD CAM restorations are on top if we compare CAD CAM restorations over conventional one. Because CAD CAM a) provide us quality restorations with quick and

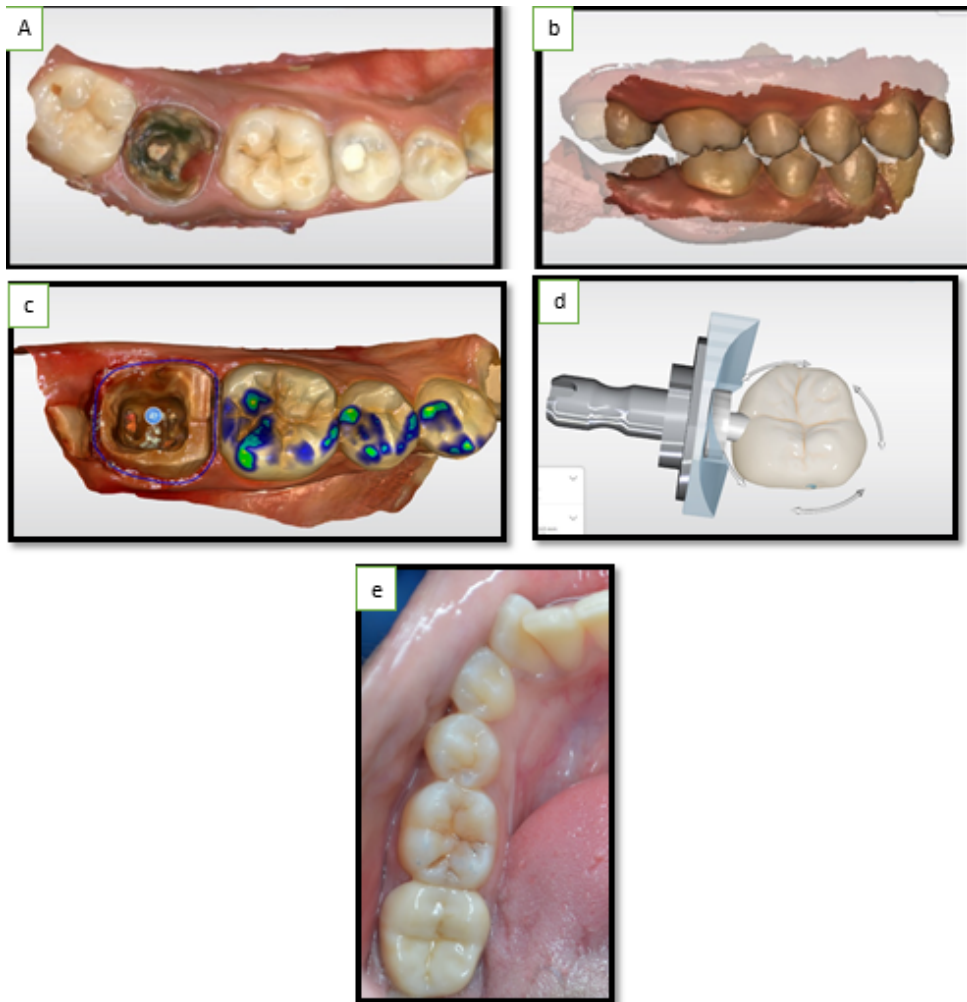


Fig. 1: a,b: Digital scanning of prepared tooth and bite scanning; c: Designing of restoration; d: Manufacturing; e: Final cemented restoration on molar

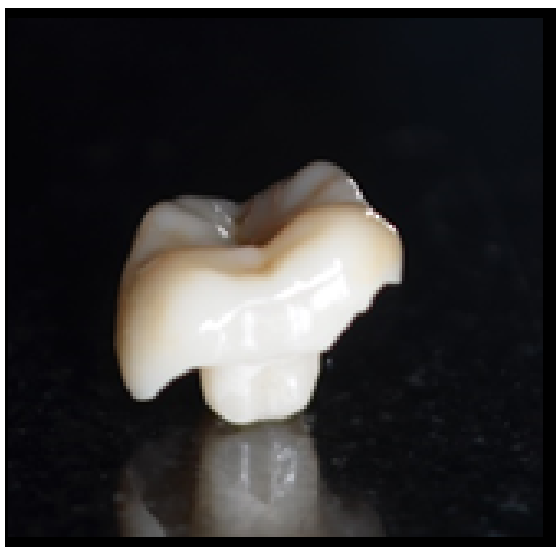

Fig. 2: Customized zirconium restoration

easy fabrication b) Scanning of intra oral tissues takes less time than conventional impression c) if chair side system is available, patients can get their restorations in one appointment.

CAD CAM has changed concept of modern world dentistry. Different specialties of dentistry are being successfully because of CAD CAM. Either orthodontics or endodontics, quality treatment is possible with accuracy and effectiveness. But cost of these treatments is still a problem for the patients and the dentists, especially in the developing countries. We are hopeful that in the near future, CAD CAM will be started using widely in the developing countries as well.²⁴

3. Conclusion

Endocrowns have been used as an alternative to conventional post-core and fixed partial dentures in restoration of ETT (endodontically treated teeth) with

extensive coronal tissue loss. Compared to traditional methods, better aesthetics and mechanical performance, and short clinical times, less tooth reduction, highly précised are the advantages of endocrowns/ customized restorations. CAD/CAM systems have evolved dentistry by providing high-quality restorations. With introduction of new systems demonstrate increasing user friendliness, expanded capabilities, and improved quality, and range in complexity and application.

4. Conflict of Interest

The authors declare no relevant conflicts of interest.

5. Source of Funding

None.

References

- Hargreaves KM. Cohen's pathways of the pulp. St. Louis: Mosby; 2011.
- Reeh ES, Messer HH, wH Douglas. Reduction in tooth stiffness as a result of endodontic and restorative procedures. *J Endod.* 1989;15(11):512–6.
- Mathew MG, Roopa KB, Soni AJ, Khan MM, Kauser A. Evaluation of Clinical Success, Parental and Child Satisfaction of Stainless-Steel Crowns and Zirconia Crowns in Primary Molars. *J Family Med Prim Care.* 2020;9(3):1418–23.
- Seale NS. The use of stainless-steel crowns. *Pediatr Dent.* 2002;24(5):501–5.
- Ma PS, Nicholls JI, Junge T, Philips KM. Load fatigue of teeth with different ferrule lengths, restored with fiber posts, composite resin cores, and all-ceramic crowns. *J Prosthet Dent.* 2009;102(4):229–34.
- Dejak B, Mlotkowski A. 3D-finite element analysis of molars restored with endocrowns and posts during masticatory simulation. *Dent Mater.* 2013;29(12):309–17. doi:10.1016/j.dental.2013.09.014.
- Belleflamme MM, Geerts SO, Louwette MM, Grenade CH, Vanheusden AJ, Mainjot AK, et al. No post-no core approach to restore severely damaged posterior teeth: An up to 10-year retrospective study of documented endocrown cases. *J Dent.* 2017;63:1–7. doi:10.1016/j.jdent.2017.04.009.
- Göhring TN, Peters OA. Restoration of endodontically treated teeth without posts. *Am J Dent.* 2003;16(5):313–7.
- Dietschi D, Duc O, Krejci I, Sadan A. Biomechanical considerations for the restoration of endodontically treated teeth: A systematic review of the literature - part 1. Composition and micro- and macrostructure alterations. *Quintessence Int.* 2007;38(9):733–43.
- Hargreaves M, Berman L. Cohen's Pathways of the Pulp. 11th Edn. St. Louis, Missouri: Mosby Elsevier; 2016.
- Biacchi GR, Basting RT. Comparison of fracture strength of endocrowns and glass fiber post-retained conventional crowns. *Oper Dent.* 2012;37(2):130–6. doi:10.2341/11-105-L.
- Bindl A, Mörmann WH. Clinical evaluation of adhesively placed Cerec endo-crowns after 2 years - preliminary results. *J Adhes Dent.* 1999;1(3):255–65.
- Valentina V, Aleksandar T, Dejan L, Vojkan L. Restoring endodontically treated teeth with all-ceramic endo-crowns: case report. *Serbian Dent J.* 2008;55(1):54–64.
- Lander E, Dietschi D. Endocrowns: A clinical report. *Quintessence Int.* 2008;39(2):99–106.
- Bernhart J, Bräuning A, Altenburger MJ, Wrbas KT. Cerec3D endocrowns-two-year clinical examination of CAD/CAM crowns for restoring endodontically treated molars. *Int J Comput Dent.* 2009;13(2):141–54.
- Otto T, Mörmann WH. Clinical performance of chair- side CAD/CAM feldspathic ceramic posterior shoulder crowns and endocrowns up to 12 years. *Int J Computerized Dent.* 2015;18(2):147–61.
- Amal S, Nair MG, Sreeja J, Babu A, Ajas A. Endocrown - an overlooked alternative. *Arch Dent Med Res.* 2016;2(1):34–8.
- Ploumaki A, Bilkhair A, Tuna T, Stampf S, Strub JR. Success rates of prosthetic restorations on endodontically treated teeth; a systematic review after 6 years. *J Oral Rehabil.* 2013;40(8):618–30.
- Belleflamme MM, Geerts SO, Louwette MM, Grenade CF, Vanheusden AJ, Mainjot AK, et al. No post-no core approach to restore severely damaged posterior teeth: an up to 10-year retrospective study of documented endocrown cases. *J Dent.* 2017;63:1–7. doi:10.1016/j.jdent.2017.04.009.
- Uzun G. An Overview of Dental CAD/CAM Systems. *Biotechnol Biotechnological Equipment.* 2008;22(1):530–5. doi:10.1080/13102818.2008.10817506.
- Dalstra M, Melsen B. From alginate impressions to digital virtual models: accuracy and reproducibility. *J Orthod.* 2009;36(1):36–41.
- Biacchi GR, Basting RT. Comparison of fracture strength of endocrowns and glass fiber post-retained conventional crowns. *Operative Dent.* 2012;37(2):130–6. doi:10.2341/11-105-L.
- Gresnigt MMM, Özcan M, Van Den Houten M, Schipper L, Cune M. Fracture strength, failure type and Weibull characteristics of lithium disilicate and multiphase resin composite endocrowns under axial and lateral forces. *Dent Mater.* 2016;32(5):607–14. doi:10.1016/j.dental.2016.01.004.
- Irfan UB, Aslam K, Nadim R. A review on cad cam in dentistry. *J Pak Dent Assoc.* 2015;24(3).

Author biography

Gaurav Gupta, Private Practice  <https://orcid.org/0000-0003-3895-059X>

D.K Gupta, Senior Consultant

Priyanka Gupta, Senior Demonstrator

Kuldeep Singh Rana, Assistant Professor

Neeraj Chandra, Senior Lecturer

Parth Shah, Senior Consultant

Cite this article: Gupta G, Gupta DK, Gupta P, Rana KS, Chandra N, Shah P. Restoring non-restorable with the help of customized digital solutions: A review. *IP Indian J Conserv Endod* 2022;7(2):57-60.