

Content available at: <https://www.ipinnovative.com/open-access-journals>

IP Indian Journal of Conservative and Endodontics

Journal homepage: <https://www.ijce.in/>

Case Report

Customized esthetic restoration in endodontically treated young permanent 1st molar

Gaurav Gupta^{1,*}, D.K Gupta², Priyanka Gupta³, Abhishek Khairwa⁴,
Kuldeep Singh Rana⁵

¹Dept. of Pedodontics and Preventive Dentistry, Wisdom Dental Clinics, Jaipur, Rajasthan, India

²Dept. of Oral and Maxillofacial Surgery, Wisdom Dental Clinics, Jaipur, Rajasthan, India

³Dept. of Pedodontics and Preventive Dentistry, RUHSCDS Govt. Dental College, Jaipur, Rajasthan, India

⁴Dept. of Pedodontics and Preventive Dentistry, Jaipur Dental College, Jaipur, Rajasthan, India

⁵Dept. of Conservative Dentistry and Endodontics, Government college of Dentistry, Indore, Madhya Pradesh, India



ARTICLE INFO

Article history:

Received 12-04-2022

Accepted 04-05-2022

Available online 13-06-2022

Keywords:

Grossly decayed young permanent molar

Customized zirconia crown

CEREC workflow

ABSTRACT

Early caries involvement and gross destruction of permanent first molars result in reduced masticatory efficiency and later may lead to malocclusion, aesthetic and psychological problems for a smaller extent. This case highlights the importance on management of grossly decayed young permanent molar by conservative approach in children followed by placement of customized zirconia crown using CEREC workflow, thus restoring the form, function, and occlusion.

This is an Open Access (OA) journal, and articles are distributed under the terms of the [Creative Commons Attribution-NonCommercial-ShareAlike 4.0 License](https://creativecommons.org/licenses/by-nc-sa/4.0/), which allows others to remix, tweak, and build upon the work non-commercially, as long as appropriate credit is given and the new creations are licensed under the identical terms.

For reprints contact: reprint@ipinnovative.com

1. Introduction

Dental caries is one of the most widespread medical conditions both in adults and children.¹ According to WHO, more than 530 million children suffer from dental caries.² First permanent molar (FPM) is considered as most important tooth for dentition and dental development with a key role in occlusion. It participates in maxillary growth and physiology of mandibular system. However, it is considered to be most and earliest affected tooth by cavities. Indeed, early time of its eruption when hygiene is difficult and poorly controlled makes it particularly vulnerable for carious disease.³

Treatment of carious permanent molars has always been a challenge for clinician. Various materials have been used over years such as amalgam, composites, and stainless-steel crowns (SSC) to restore such teeth with varying success rates.¹

Over the past 70 years, SSCs have been placed on primary and permanent molars to restore teeth with multi surface caries, in patients with high caries risk, after pulp therapy, restore teeth with developmental defects, teeth that are brittle and prone to fracture. For more than half century, SSCs have outperformed other materials like amalgam and composite in terms of durability and longevity. In past, no restorative material has been able to offer advantages of low cost, durability, and reliability when interim full-coronal coverage is required.^{4,5} In spite of these benefits, notable pitfall to the SSC is compromised esthetics, due to metallic appearance which has been poorly received by patients, parents, and practitioners alike.⁴ One of biggest disadvantage of preformed SSC of 1st permanent molars is that they are supposed to be replaced after the occlusion has stabilized/settled from mixed to permanent dentition because they interfere with eruption of adjacent tooth but customized restoration is a long term solution, which doesn't need to be changed both esthetically and

* Corresponding author.

E-mail address: dr.gauravgupta99@gmail.com (G. Gupta).

functionally.

The increasing demand from parents for esthetic restorations led to the introduction of customized zirconia crowns. Zirconia crowns are recently been used in permanent 1st molar. Zirconia crowns are introduced as new full-coverage restoration which combines excellent esthetics with superior mechanical properties.⁶

Customized zirconia crowns are possible because of CAD/CAM (Computer-aided design and manufacturing) technology. Technology had a major impact on the practice of dentistry. It has changed the way the dental office communicates with patients, keeps their records, and controls its finances, as well as the way the patient receives treatment. Digital technologies now have applications in orthodontics, prosthodontics, and restorative dentistry.⁷

Here we present a case with conservative approach for the management of grossly decayed young permanent molar followed by fabrication of customized zirconia restoration using digital CEREC workflow in order to restore its form function and occlusion.

2. Case Report

A 10-year-old boy came to clinic with decayed tooth and pain in mandibular left and right permanent back region. A medical, as well as clinical history, was taken along with the radiographic examination, which showed the presence of deep dentinal caries with pulpal exposure and extensive loss of tooth structure in the right and left young permanent mandibular 1st molar. The tooth was found to be tender on percussion. (Figure 1)

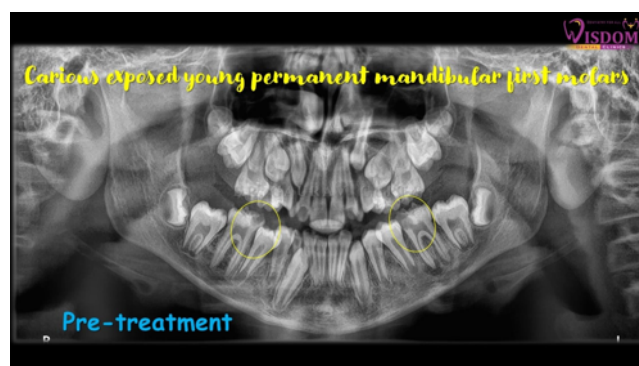

Fig. 1: Pre-operative OPG

Looking at the intraoral condition of the tooth endodontic treatment of right and left mandibular 1st molar was planned. Patient and parents were explained about the treatment.

After administering local anaesthesia single visit root canal treatment (RCT) was performed on right and left young permanent 1st molar. Access was achieved using a round diamond bur. Orifices were located and working length was established. A 5.25% solution of sodium

hypochlorite and 17% was used as irrigants at every change of instrument. The apical preparation was done. Calcium hydroxide was placed as an intracanal medicament and obturation done using RH Fill sealer.(Figure 2)

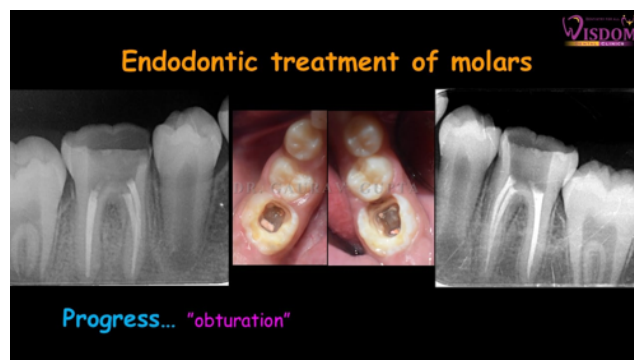

Fig. 2: RCT done in left and right side mandibular 1st molar

Scanning was done by intraoral scanner (Dentsply Sirona Omnicam) after minimal tooth preparation only occlusal to capture a digital impression for further processing in CEREC software (Figure 3). A Digital record of the segment with opposing arch was also recorded. Scanning provides easier, more intuitive, and precise 3D models in natural colours in less than 2 minutes.

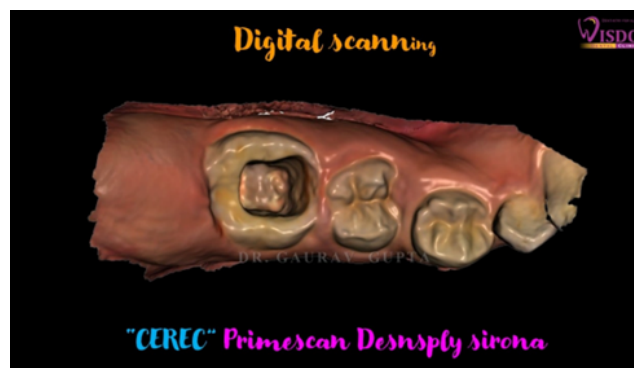

Fig. 3: Intraoral scan

Designing was done in 5 minutes followed by milling in the prime mill which took around 11 minutes. [Figure 4a,b,c]

Wet milling was carried out on CAD/CAM block (Ivoclar Vivadent IPSe.max ZirCAD – Yttrium-stabilized zirconium oxide block). The milling process was extremely precise, definitive and created smooth surfaces and margins compared to the lab process. This is INDIA first house latest generation CEREC Prime mill.

After milling the sprue detachment was done from the block followed by sintering and glazing. Sintering was done for strength which took around 12-15 minutes. Both sintering and glazing were simultaneously done in speed fire. Glazing was done to provide aesthetic and gloss in speed fire which took around 8-10 minutes.[Figure 5a,b]

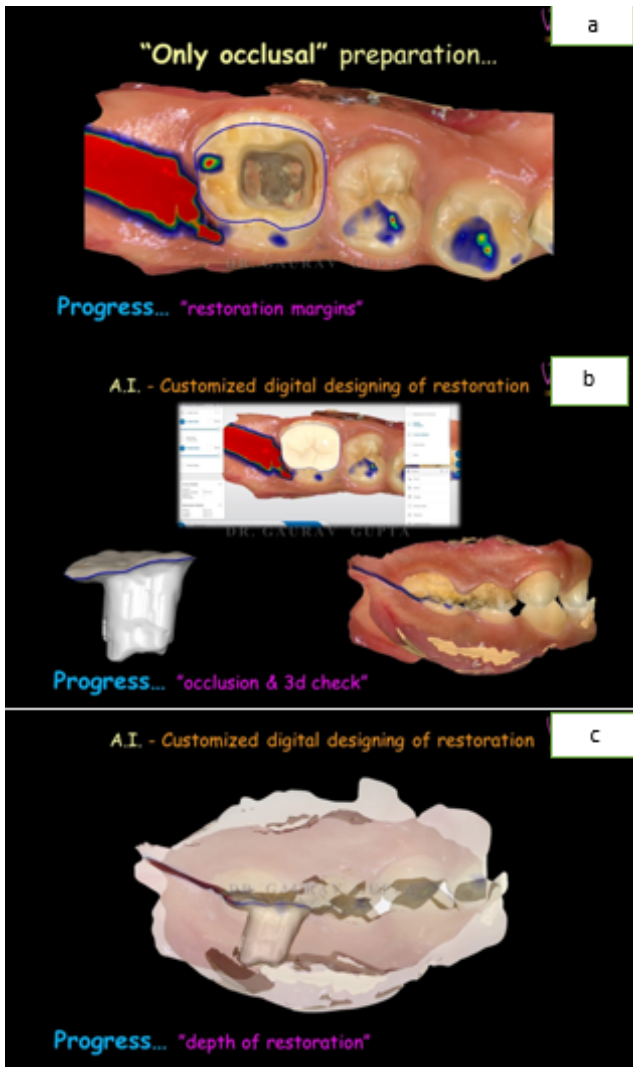


Fig. 4: a,b,c: Customized CAD designing

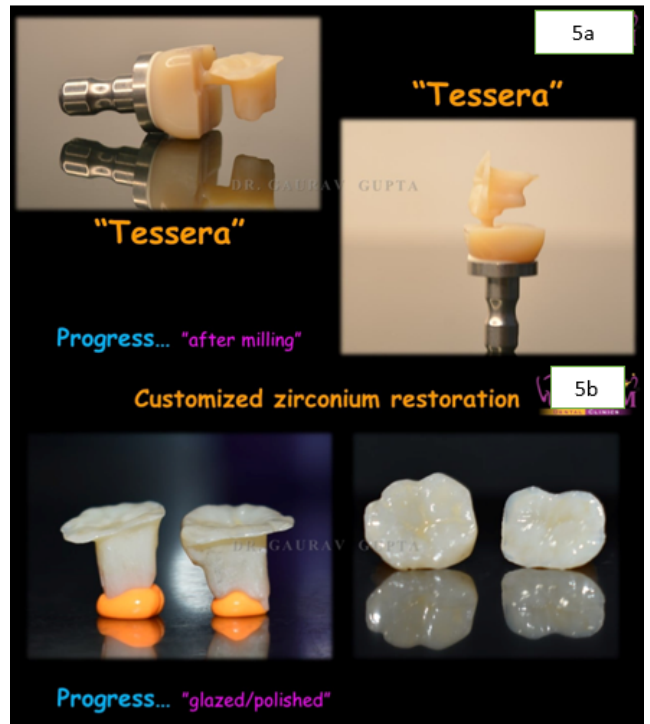


Fig. 5: a,b: Customized zirconia restoration -milling ,glazed /polished

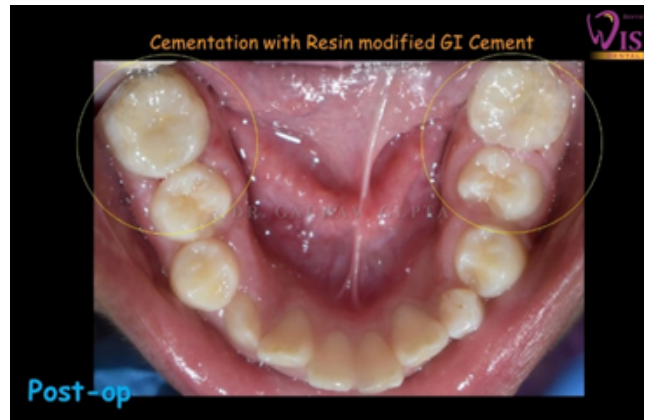

Fig. 6: Cementation with Resin modified GIC

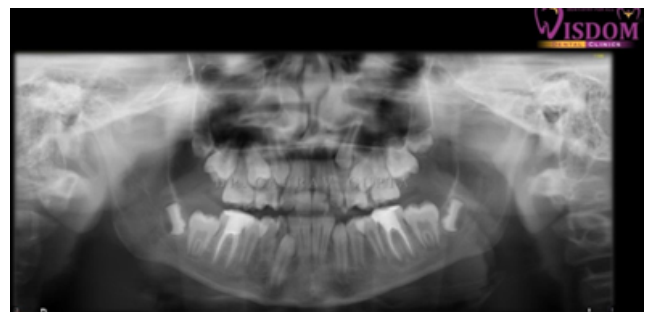

Fig. 7: Post-operative OPG

Fitting, aesthetics, and characterization were checked in the patient’s mouth. Then, the tooth was cleaned and prepared for luting with resin modified GI cement. Excess cement was removed from interdental spaces and occlusion was checked. The patient was given post-operative instruction.[Figures 6 and 7]

In a matter of less than 45 minutes, complacent, enjoyable and acceptable results were achieved. As shown in this case, we reconstituted not only the form and function of permanent teeth but also the aesthetics with minimally invasive dentistry in a single sitting with the help of the CEREC workflow

3. Discussion

Use of stainless-steel crowns (SSCs) in paediatric dentistry is a common practice for management of heavily decayed and deformed permanent 1st molar.^{8,9} These crowns

provide solution for restoration with highest success rate, without causing secondary caries and are cost effective.¹⁰ The biggest disadvantage of using SSCs is that they show aesthetically unattractive result. To overcome the poor aesthetics, new materials are developed, such as customized zirconia crowns.

Customized zirconia restoration are manufactured through CEREC workflow with help of zirconia CAD CAM block. Digital impression for restoration fabrication is done using CEREC. CEREC (Chairside Economical Restoration of Aesthetic Ceramic) is the method of manufacturing dental restorations in the dental office. The digital workflow is integrated by the intraoral scanners which take the impression. These are powerful devices that can easily send the models to the laboratory using e-mail, thus reducing expense and time. Until now this technology was used only in adults but now it's use is extending in Paediatric Dentistry also.¹¹ Moreover, it involves a shorter clinical working time, less wear of the opposite dentition, and there is choice of more biocompatible material.¹²

Advantages of using customized digital approach is preparation of restoration is minimally invasive only occlusal preparation done is required with no labio-lingual and mesio-distal extensions. So, this restoration won't interfere with eruption of adjacent permanent teeth and doesn't need to be changed later with eruption of adjacent tooth. Secondly it perfectly fit on endodontically treated tooth and occlusion is achieved with no adjustments required to be done on antagonist tooth.

Various studies are done to compare the time efficiency of digital 3D scanning over conventional impression methods but only a few are done yet to compare the entire workflow.¹³ There is a requirement of new comparative studies in this field with introduction of latest CEREC software's. The aim of our article was to portray the time efficiency and specificity of chairside workflow to fabricate customised hybrid restoration as per the need in young permanent molars.

A milling machine installation in clinic allows the insertion of customized final restoration within hours in single sitting after RCT (Endodontic treatment). CEREC Prime mill detains next step forward and offered a highly calibrated chairside dentistry. It manufactures extravagant chair side restoration easily and meticulously in few minutes due to the advanced digital technology.

The digital impression technique is also helpful to solve behavioural issues of the uncooperative patient as compared to the conventional impression technique. Conventional impression technique requires full mouth impression whereas, in digital impression, we need to take an impression of the particular arch /segment /quadrant we need to treat. The use of the digital intraoral impression technique eliminates the need for a conventional alginate impression. Conventional impressions are considered an unpleasant experience by some children because they cause

gaging due to which impression has to be repeated to get the accurate result, thus switching to digital impression procedure have a long-term positive impact on patient perceptions of dental procedures.¹⁴

This case report emphasises on conservative management of grossly decayed permanent 1st molar followed with placement of digital customized restoration using CEREC workflow in single sitting. This in turn will save time, is easy for non-compliance children, precise, and conservative approach to preserve grossly decayed young permanent molars. As discussed in various studies prefabricated crowns were available for endodontically treated permanent molars in children but customized and aesthetic restorative options were lacking. This approach is highly esthetic, and customized comfortable restorative approach that could be easily carried on young children chair side.

4. Conclusion

This case report suggests that CEREC chairside system is a useful tool for the clinician. The digital 3D impression, software design and milling unit in same office allow to produce highly aesthetic, customized and reliable restorations in a single visit, while improving patient acceptance and comfort for the procedures. We can assert that restorative treatment with digital CAD/CAM chairside workflow represents a valid alternative to rehabilitate pediatric patients, because it is a safe, predictable and personalized procedure but also it is easier, and faster than traditional protocol in long run.

5. Conflict of Interest

The authors declare no relevant conflicts of interest.

6. Source of Funding

None.

References

1. Pitts NB, Zero DT, Marsh PD, Ekstrand K, Weintraub JA, Ramos-Gomez F, et al. Dental caries. *Nat Rev Dis Primers*. 2017;3:17030. doi:10.1038/nrdp.2017.30.
2. World Health Organization. Oral Health. (accessed on 25 March 2020). Available from: <https://www.who.int/news-room/fact-sheets/detail/oral-health>.
3. Hamza M, Chlyah A, Bousfiha B, Badre B, Mtalsi M, Saih H, et al. Pathology And Abnormality Of The First Permanent Molar Among Children. *Human Teeth - Key Skills Clin Illustrations*. 2022;doi:10.5772/intechopen.89725.
4. Randall RC. Preformed metal crowns for primary and permanent molar teeth: Review of the literature. *Pediatr Dent*. 2002;24(5):489-500.
5. Seale NS. The use of stainless-steel crowns. *Pediatr Dent*. 2001;24(5):501-5.
6. Holsinger DM, Wells MH, Scarbecz M, Donaldson M. Clinical evaluation and parental satisfaction with pediatric zirconia anterior crowns. *Pediatr Dent*. 2016;38(3):192-7.

7. Fasbinder DJ. Computerized technology for restorative dentistry. *Am J Dent.* 2013;26(3):115-20.
8. Kindelan SA, Day P. UK national clinical guidelines in Pediatric Dentistry: stainless steel preformed crowns for primary molars. *Int J Paediatr Dent.* 2008;18(1):20-8. doi:10.1111/j.1365-263X.2008.00935.x.
9. Randall RC. Preformed metal crowns for primary and permanent molar teeth: review of the literature. *Pediatr Dent.* 2000;24(5):489-500.
10. Seale NS. The use of stainless-steel crowns. *Pediatr Dent.* 2002;24(5):501-5.
11. Joda T, Brägger U. Digital vs. conventional implant prosthetic workflows: A cost/time analysis. *Clin Oral Implant Res.* 2015;26(12):1430-5. doi:10.1111/clr.12476.
12. Simsek H, Derelioglu S. In vitro comparative analysis of fracture resistance in inlay restoration prepared with CAD-CAM and different systems in the primary teeth. *Biomed Res Int.* 2016;p. 4292761. doi:10.1155/2016/4292761.
13. Joda T, Brägger U. Digital vs. conventional implant prosthetic workflows: A cost/time analysis. *Clin Oral Implant Res.* 2015;26(12):1430-5. doi:10.1111/clr.12476.
14. Dalstra M, Melsen B. From alginate impressions to digital virtual models: accuracy and reproducibility. *J Orthod.* 2009;36(1):36-41.

Author biography

Gaurav Gupta, Private Practitioner  <https://orcid.org/0000-0003-3895-059X>

D.K Gupta, Senior Consultant

Priyanka Gupta, Senior Demonstrator

Abhishek Khairwa, Professor

Kuldeep Singh Rana, Assistant Professor

Cite this article: Gupta G, Gupta DK, Gupta P, Khairwa A, Rana KS. Customized esthetic restoration in endodontically treated young permanent 1st molar. *IP Indian J Conserv Endod* 2022;7(2):67-71.