

Content available at: <https://www.ipinnovative.com/open-access-journals>

IP Indian Journal of Conservative and Endodontics

Journal homepage: <https://www.ijce.in/>

## Case Report

# Non-surgical management of a periapical lesion with bioceramic sealer – A case report

Sankkesh Jain<sup>1,\*</sup>, Lalitagauri Mandke<sup>1</sup>

<sup>1</sup>Dept. of Conservative Dentistry and Endodontics, DY Patil University-School of Dentistry, Navi Mumbai, Maharashtra, India



### ARTICLE INFO

#### Article history:

Received 10-05-2022

Accepted 11-05-2022

Available online 13-06-2022

#### Keywords:

Nonsurgical endodontic therapy

Periapical cyst

Bioceramic sealer

Calcium hydroxide

### ABSTRACT

This case report describes the non-surgical management of a large cyst-like periapical lesion involving 12,13,14 in a 20 years old female patient who came with a chief complaint of swelling and pus discharge with no history of pain and traumatic accident in that area. Root canal therapy was done in the same with use of calcium hydroxide intracanal medicament and obturation using bioceramic sealer. Clinical and radiographic re-evaluations at 2, 6 and 12 months revealed progressing bone healing. This case report shows that appropriate diagnosis in combination with root canal treatment and use of bioceramic sealers as a conservative non-surgical approach can lead to complete healing of large lesions without invasive treatments.

This is an Open Access (OA) journal, and articles are distributed under the terms of the [Creative Commons Attribution-NonCommercial-ShareAlike 4.0 License](https://creativecommons.org/licenses/by-nc-sa/4.0/), which allows others to remix, tweak, and build upon the work non-commercially, as long as appropriate credit is given and the new creations are licensed under the identical terms.

For reprints contact: [reprint@ipinnovative.com](mailto:reprint@ipinnovative.com)

## 1. Introduction

The ultimate goal of endodontic therapy should be to restore the health and function of the affected teeth without the need for surgery. Conservative nonsurgical methods should be used to treat all inflammatory periapical lesions first.<sup>1</sup> Treatment approaches to manage large periapical lesions range from non-surgical endodontic therapy with or without endodontic surgery to tooth extraction. Because most periapical lesions are the consequence of an inflammatory reaction within the root canal, a conservative approach should always be preferred over surgery.<sup>1</sup>

Pulpal necrosis can occur due to caries, trauma and various other factors. At the interface of the periodontal membrane and infected pulpal tissue, a dynamic encounter between the host's immune response and microbial infective agents results in varied periapical pathologies.<sup>2</sup> These periradicular lesions are not self-healing, despite their protective and preventative character against microbial

invasion.<sup>2</sup> The prevalence of radicular cysts in these lesions has been estimated to be between 6% and 55%. Furthermore, the prevalence of periapical granuloma and periapical abscess varies from 9.3% to 87.1% and 28.7% to 70.7%, respectively.<sup>3,4</sup> When the radiographic size of the lesion exceeds 200 mm<sup>2</sup>, cysts appear to be present in more than 92 percent of cases.<sup>5,6</sup>

Endodontic sealers, regardless of type, should meet the following criteria, according to Grossman (1958): biocompatibility, ease of insertion into and removal from root canals, viscosity while handling, adhesion to root canal walls, acceptable handling time, promotion of a three dimensional seal, dimensional stability, good flow, good radiopacity, lack of colour change, insolubility to tissue fluids and saliva, solubility to common solvents when required, impermeability and antimicrobial properties.<sup>7</sup>

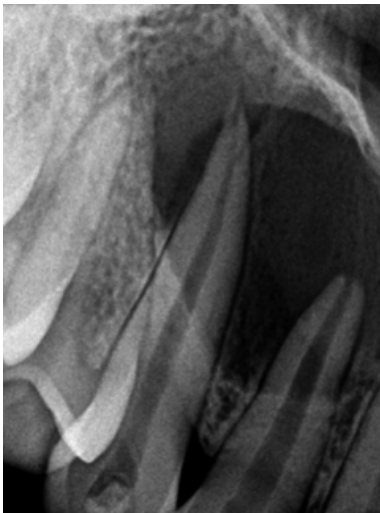
Calcium silicate-based bioactive sealers are becoming more popular due to their improved mechanical, chemical and cytocompatible properties.<sup>8</sup> The following case report describes the non-surgical management of a periapical infection by using Bioceramic sealer.

\* Corresponding author.

E-mail address: [sanky.usm@gmail.com](mailto:sanky.usm@gmail.com) (S. Jain).

## 2. Case Report

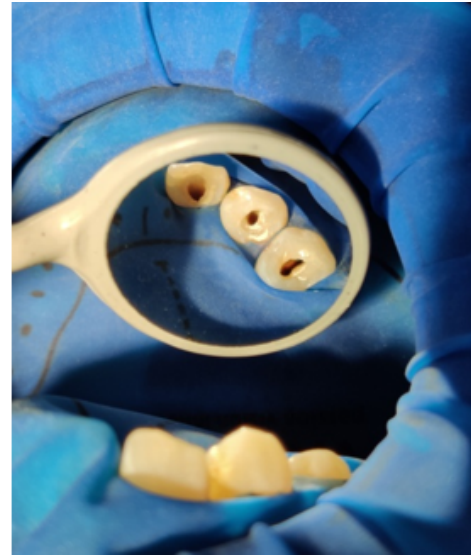
A 20 years old female patient reported to the Department of Conservative Dentistry and Endodontics, D.Y Patil University – School of Dentistry, Nerul, Navi Mumbai, India with a chief complaint of swelling in the upper right front teeth region and occasional pus discharge since 6 months. She experienced occasional dull aching pain and couldn't recall any traumatic accident in this area. Her past medical history was not contributory. Extra-oral examination showed non-palpable lymph nodes and no facial swelling. Intra-oral examination showed no evident caries or fractured tooth structure. Tooth #12 showed few horizontal fracture lines in the incisal and middle third region indicative of a previous trauma. A palatal swelling involving #12, #13, #14 was seen. There were no periodontal pockets present and thermal tests elicited a negative response in #12, #13 and #14. Grade I mobility was seen with #12 and #13. Also, tenderness on percussion was seen in #12 and #13. Radiographically, a radiolucent lesion involving #12, #13 and #14 was seen, extending approximately 20x15 mm in length and width respectively. (Figure 1) Tooth #12 showed some amount of root resorption as well.



**Fig. 1:** Preoperative radiograph showing radiolucent lesion extending from #12 to #14

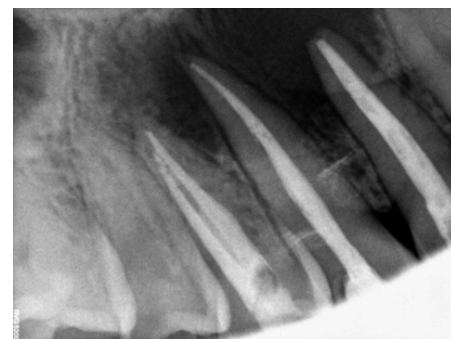The patient was explained the treatment modalities like root canal therapy following apicoectomy and also the non surgical approach. Root canal therapy for the teeth involved was decided with a non surgical approach. Local anaesthesia (Lidocaine 2% with Adrenaline 1:80000) was administered and Optradam (Ivoclar Vivadent) was placed exposing the teeth to be treated. Access opening was done and the working length was determined using Dentaport ZX apex locator (J Morita). (Figure 2) Cleaning and shaping was done along with copious irrigation using saline and 3% sodium hypochlorite. Tooth #12 was prepared at the apex till

60.02 with Hand K file (MANI) and a step back procedure was carried out. Teeth #13 and #14 were prepared till 30.04 using E3 Azure Ratory System (Endostar Poldent). The canals were dried with paper points and Calcium Hydroxide (Prime Dental) was placed as an intra-canal medicament and temporary restoration was done with Zinc oxide Eugenol cement. The patient was recalled at an interval of 7-10 days, thrice, and the canals were irrigated with saline, dried and a dressing of calcium hydroxide was placed again in all three visits.

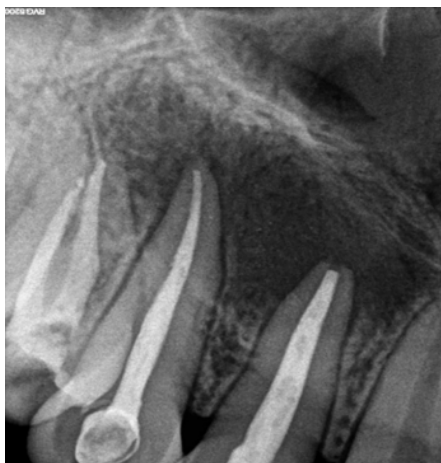

**Fig. 2:** Access Opening (12,13,14)

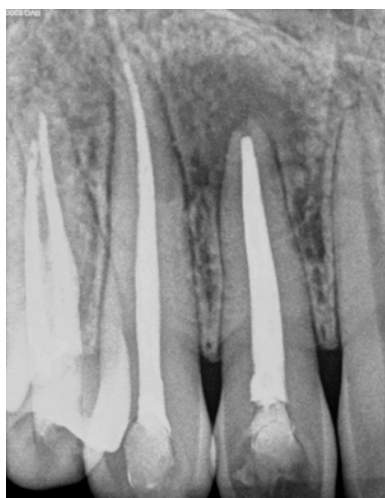On the fourth visit, tenderness on percussion, mobility and the intraoral swelling was assessed. All pre-op signs and symptoms had regressed, following which master cone selection and obturation was done using Ceraseal (Meta Biomed) as sealer using the single cone technique. (Figure 3) The patient was recalled after 2, 6 and 12 months for evaluation. Healing of the periapical lesion radiographically was seen with reduction in mobility.



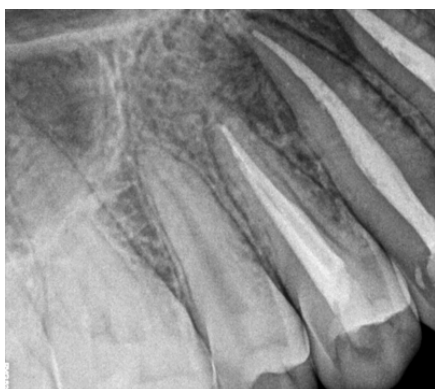**Fig. 3:** Immediate Post-Op (12,13,14)



**Fig. 4:** 6 Months follow up (12,13,14)



**Fig. 5:** 12 Months follow up (12,13,14)



**Fig. 6:** 12 Months follow up (13,14)

### 3. Discussion

The management of large periapical lesions is the subject of prolonged debate. The treatment options range from RCT or NSRCT with long-term  $\text{Ca}(\text{OH})_2$  therapy to various surgical interventions, including marsupialisation, decompression with a tube and surgical removal of the lesion. These treatment options can also be combined.<sup>9</sup>

Bhaskar suggested that if instrumentation is exceeded 1 mm beyond the apex, the resulting inflammatory reaction destroys the cyst lining and transforms the lesion into granuloma.<sup>10</sup> Furthermore, once the causative factors are removed, the granuloma cures on its own. Extending beyond the apical zone and into the radiolucent area aids healing by establishing drainage and providing pressure relief, as well as by causing epithelial cell degeneration through strangulation as a result of fibroblast and collagen proliferation – putting pressure on the cyst wall capillary supply.<sup>11</sup> On the other hand, increased epithelial proliferation and cyst growth can obstruct the healing process.<sup>12</sup> In this case instrumentation was done 1mm short of apical foramen so as to avoid any additional trauma and following Weine's modification of determining working length.

For successful neutralization and elimination of infection from the root canal system, irrigation with sodium hypochlorite and proper biomechanical preparation is required, followed by calcium hydroxide intracanal medication.<sup>13</sup> The ionic dissociation of calcium ion and hydroxyl ion occurs in all biological effects of calcium hydroxide. Calcium hydroxide's antimicrobial activity is linked to the release of hydroxyl ions in an aqueous environment. Hydroxyl ions are highly reactive oxidant-free radicals that cause damage to the bacterial cytoplasmic membrane, protein denaturation, and bacterial DNA damage.<sup>14</sup>

Periradicular tissue healing and repair is a complex regeneration process involving bone, periodontal ligament, and cementum.<sup>15</sup> Changes in lesion density, trabecular development, and the establishment of lamina dura are all radiological indicators of healing, especially when they are related with asymptomatic teeth and healthy soft tissues. Healing begins with the regrowth of the external cortical plate and progresses from the outside of the lesion to the interior in situations of cortical plate perforation.<sup>16,17</sup> Due to the presence of a more extensive circulatory network in the maxilla, which helps resolution, maxillary lesions cure faster than mandibular lesions. Due to the close vicinity of the buccal and lingual plates in the anterior segments, anterior lesions of the maxilla and mandible heal faster than posterior lesions.<sup>15</sup>

Due to their biocompatibility and the presence of calcium phosphate, which improves bioceramics' setting properties and results in a chemical and crystalline structure similar to tooth and bone apatite components,

bioceramic-based sealers have surpassed other sealers in the era of adhesive dentistry, thereby improving sealer-to-root dentin bonding.<sup>1</sup> Alumina, zirconia, bioactive glass, glass ceramics, calcium silicates, coatings and composites, hydroxyapatite, resorbable calcium phosphates, and radiotherapy glasses are all examples of bioceramics.<sup>1</sup> Another benefit of the material is its capacity to generate hydroxyapatite during the setting process, resulting in a chemical link between dentin and the corresponding filling.

The fact that it does not shrink or resorb (which is crucial for a single-cone technique), its high pH (12.8) during the initial 24 hours of the setting process (which is strongly anti-bacterial), extremely good sealing ability, rapid setting action (3 to 4 hours) are some of the other benefits. The particle size of this material is so small (less than 2  $\mu\text{m}$ ) that it can be used in a syringe, thus making it easy to use.<sup>18</sup> Hence a single cone technique was used during obturation to accommodate as much sealer in the radicular space as possible without compromising on the apical seal.

Celikten et al used a bioceramic sealer to test the sealing ability of a single cone, lateral compaction, and the thermafill technique. The fraction of sections with voids did not differ significantly depending on the obturation procedure.<sup>19</sup>

In this case, a relatively complete healing of the lesion was observed over a period of 12 months. The benefits of less invasive nonsurgical treatment of extensive periapical lesions includes minimum psychological trauma and is more acceptable for patients.

#### 4. Conclusion

Root canal therapy with bioceramic sealer was used to treat an extensive periradicular lesion with clinical and radiological characteristics of a radicular cyst. Over the course of a year, the lesion in this case appeared to heal fairly complete. Under comprehensive cleaning and disinfection procedures, the use of calcium hydroxide paste was shown to be prudent.

#### 5. Conflict of Interest

The authors declare no relevant conflicts of interest.

#### 6. Source of Funding

None.

#### References

1. Nagar N, Kumar N. A Comparative Clinical Evaluation Of A Bioceramic Root Canal Sealer With MTA Based Sealer, Resin Based Sealer And Zinc Oxide Based Sealer -An In Vivo Study. *IOSR J Dent Med Sci.* 2018;17(5):81–5. doi:10.9790/0853-1705108185.

2. Ghorbanzadeh S, Ashraf H, Hosseinpour S, Ghorbanzadeh F. Nonsurgical Management of a Large Periapical Lesion: A Case Report. *Iran Endod J.* 2017;12(2):253–6.
3. Moshari A, Vatanpour M, Ashari EE, Zakershahrok M, Ara JA. Nonsurgical Management of an Extensive Endodontic Periapical Lesion: A Case Report. *Iran Endod J.* 2017;12(1):116–9. doi:10.22037/iej.2017.24.
4. Kimmelmann BB. Teaching two tooth brushing techniques: Observations and comparisons. *J Periodontol.* 1968;39(2):96–100.
5. Podshadley AG, Haley JV. A method for evaluating oral hygiene performance. *Public Health Rep.* 1968;83(3):259–64.
6. Natkin E, Oswald RJ, Carnes LI. The relationship of lesion size to diagnosis, incidence, and treatment of periapical cysts and granulomas. *Oral Surg Oral Med Oral Pathol.* 1984;57(1):82–94.
7. Grossman LI. An improved root canal cement. *J Am Dent Assoc.* 1958;56(3):381–5.
8. Rodríguez-Lozano FJ, García-Bernal D, Oñate-Sánchez RE, Ortolani-Seltenerich PS, Forner L, Moraleda JM, et al. Evaluation of cytocompatibility of calcium silicate-based endodontic sealers and their effects on the biological responses of mesenchymal dental stem cells. *Int Endod J.* 2017;50(1):67–76. doi:10.1111/iej.12596.
9. Campo N. Large periapical lesion management Decompression combined with root-canal treatment. *Roots.* 2012;1:6–9.
10. Bhaskar SN. Periapical lesions-types, incidence, and clinical features. *Oral Surg Oral Med Oral Pathol.* 1996;21(5):657–71. doi:10.1016/0030-4220(66)90044-2.
11. Bender IB. A commentary on General Bhaskar's hypothesis. *Oral Surg Oral Med Oral Pathol.* 1972;34(3):469–76. doi:10.1016/0030-4220(72)90326-x.
12. Seltzer S. Endodontology-biologic considerations in endodontic procedures. 2nd Edn. Philadelphia, PA: Lea and Febiger; 1998.
13. Mendoza-Mendoza A, Caleza-Jimenez C, Iglesias-Linares A, Solano-Mendoza B, Yanez-Vico RM. Endodontic treatment of large periapical lesions: An alternative to surgery. *Edorium J Dent.* 2015;2:1–6. doi:10.5348/D01-2015-3-CS-1.
14. Estrela C, Sydney GB, Bammann LL, Felipe O. Estudo do efeito biológico do pH na atividade enzimática de bactérias anaeróbias. *Rev Fac Odontologia Bauru.* 1994;2(4):31–8.
15. Fernandes M, De AI. Nonsurgical management of periapical lesions. *J Conserv Dent.* 2010;13(4):240–5. doi:10.4103/0972-0707.73384.
16. Ørstavik D. Radiographic evaluation of apical periodontitis and endodontic treatment results: A computer approach. *Int Endod J.* 1991;41(2):89–98.
17. Huuomonen S, Ørstavik D. Radiological aspects of apical periodontitis. *Endod Topics.* 2002;1(1):3–25. doi:10.1034/j.1601-1546.2002.10102.x.
18. Koch K, Brave D, Nasseh A. Bioceramic Technology : Closing the Endo-Restorative Circle, Part I. *Dent Today.* 2010;29(2):100–5.
19. Celikten B, Uzuntas CF, Orhanai AI, Tufenkci P, Misirli M, Demiralp KO, et al. CT assessment of the sealing ability of three root canal filling techniques. *J Oral Sci.* 2015;57(4):361–6. doi:10.2334/josnusd.57.361.

#### Author biography

Sankesh Jain, Post Graduate Student

Lalitagauri Mandke, Professor

**Cite this article:** Jain S, Mandke L. Non-surgical management of a periapical lesion with bioceramic sealer – A case report. *IP Indian J Conserv Endod* 2022;7(2):85–88.