

Content available at: <https://www.ipinnovative.com/open-access-journals>

IP Indian Journal of Conservative and Endodontics

Journal homepage: <https://www.ijce.in/>

## Case Report

# Endo-Aesthetic rehabilitation of complicated crown-root fracture of maxillary lateral incisor by fragment reattachment: A case report

Shaili Mehta<sup>1,\*</sup>, Manoj Ramugade<sup>1</sup>, Abrar Sayed<sup>1</sup>, Kishor Sapkale<sup>1</sup>, Sapna Sonkurla<sup>1</sup>, Sangeeta Ambhore<sup>1</sup>

<sup>1</sup>Dept. of Conservative Dentistry and Endodontics, Govt. Dental College and Hospital, Mumbai, Maharashtra, India



### ARTICLE INFO

#### Article history:

Received 13-04-2022

Accepted 27-04-2022

Available online 13-06-2022

#### Keywords:

Crown-root fracture

Dental trauma

Dental bonding

Internal groove technique

Fragment reattachment

Fiber post

Minimally invasive

Traumatic injuries

### ABSTRACT

In case of traumatic injuries to the anterior teeth, fragment reattachment is considered a minimally invasive technique. Re-attaching the same tooth fragment, possesses the advantage of biomimicry by complete restoration of form, function, texture, lustre, and translucency. Due to advancements in adhesive dentistry, simple re-attachment to complex fragment rehabilitation have become predictable and reliable. Various techniques have been proposed for fragment reattachment based on the extent of injury, type of injury, condition of the fragment, and time- lapse. This case report demonstrates the endo-aesthetic rehabilitation of a complicated crown root fracture using a fiber post on lateral incisor with fracture line on the cervical 1/3rd of the labial aspect, running obliquely and apically towards the palatal surface after 1 year follow-up.

This is an Open Access (OA) journal, and articles are distributed under the terms of the [Creative Commons Attribution-NonCommercial-ShareAlike 4.0 License](https://creativecommons.org/licenses/by-nc-sa/4.0/), which allows others to remix, tweak, and build upon the work non-commercially, as long as appropriate credit is given and the new creations are licensed under the identical terms.

For reprints contact: [reprint@ipinnovative.com](mailto:reprint@ipinnovative.com)

## 1. Introduction

Crown root fractures (CRF) are fractures that originate in the crown and extend towards the root, which are further divided into uncomplicated and complicated fractures based on pulpal involvement.<sup>1</sup> The prevalence of CRF being more in younger age group, the treatment modalities include both direct and indirect restorative techniques. In cases of CRF where a tooth fragment is detached, reattaching the fractured fragment is the treatment of choice as it is a minimally invasive procedure.<sup>2</sup> Reattaching the fragment possesses several advantages, like reinstatement of the natural form, function, and aesthetics of the tooth.<sup>3–5</sup> Fragment reattachment for rehabilitation of anterior traumatic cases has become more predictable, enduring, and reliable due to the advancement in adhesive dentistry. Fragment reattachment techniques vary from simple attachment with adhesive cement to using core material to strengthen the

remaining tooth structure. The prognosis of such cases depends on the type of injury, location of injury, and time period. This case report demonstrates the endo-aesthetic rehabilitation of a complicated CRF using fiber post.

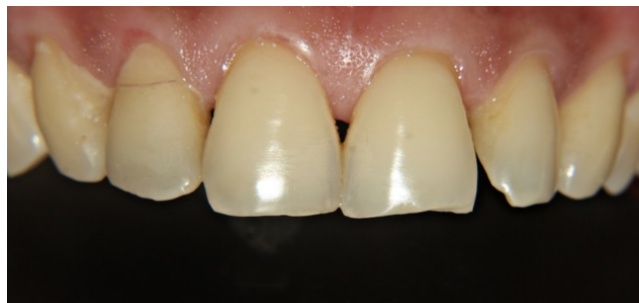## 2. Case Report

A 37-year-old healthy female patient reported to the Department of Conservative Dentistry and Endodontics with a chief complaint of pain due to a broken upper front tooth. The patient gave history of her front teeth being struck with her mobile phone the previous night. Clinical examination of tooth number 12 revealed a horizontal fracture line on the cervical 1/3rd of the facial aspect running obliquely and apically on the palatal surface. (Figure 1) The fracture line was not visible clinically on the palatal surface, but probing revealed a catch 2 mm below the gingival margin. The fractured segment showed mobility and elicited pain on palpation. Radiograph revealed a radiolucent line on the cervical third of the crown.

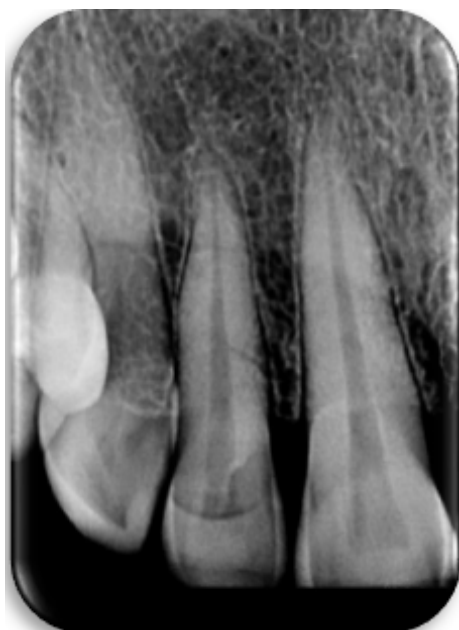\* Corresponding author.

E-mail address: [drshailimehta@gmail.com](mailto:drshailimehta@gmail.com) (S. Mehta).

(Figure 2). Considering various treatment modalities, the minimally invasive approach of fragment reattachment was chosen as the line of management.

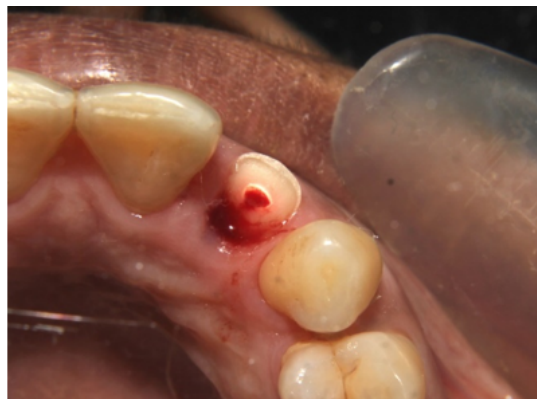

**Fig. 1:** Preoperative labial photograph demonstrating a fracture with tooth # 12.

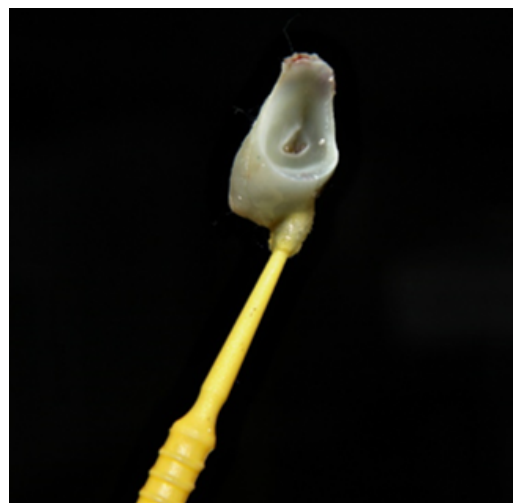

**Fig. 2:** Preoperative radiograph of tooth #12 fracture.

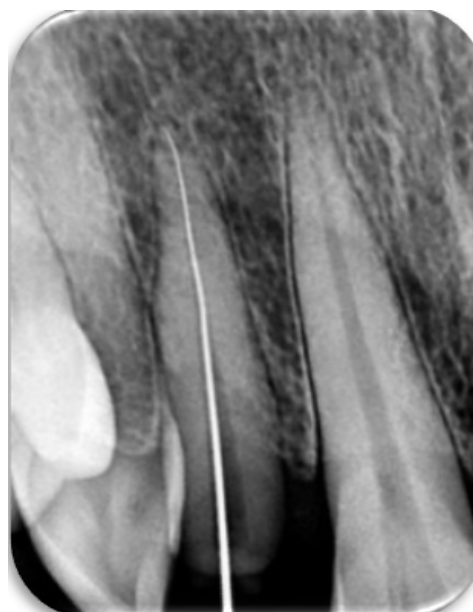The crown fragment of the tooth was atraumatically removed under local anaesthesia and stored in normal saline until reattached. (Figures 3 and 4) Traumatic pulpal exposure was refined for straight line access using a long-tapered fissure TF-12 bur (Mani Inc, Japan). Working length was determined using the Apex locator (AI Endomotor, Guilin Woodpecker Medical Instrument Co Ltd) and confirmed using an intraoral periapical radiograph (IOPA) (Figure 5). Biomechanical preparation was done using hand files (Mani Inc, Japan) with 5.25% sodium hypochlorite and saline irrigation. Tooth # 12 was obturated using the Sectional (Chicago) technique with Touch and heat (Sybron Endo) (Figure 6).



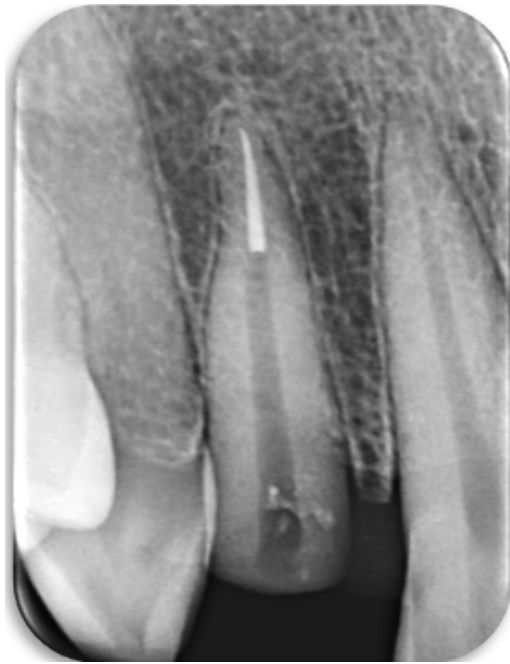
**Fig. 3:** Atraumatic extraction of tooth #12.



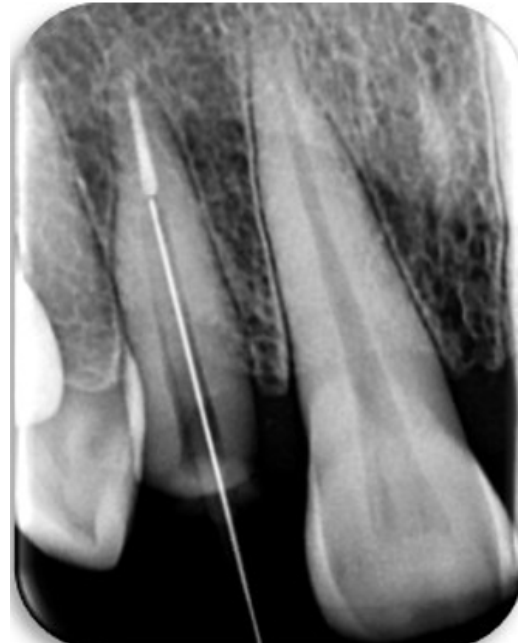**Fig. 4:** Tooth fragment.



**Fig. 5:** Working length radiograph of tooth #12

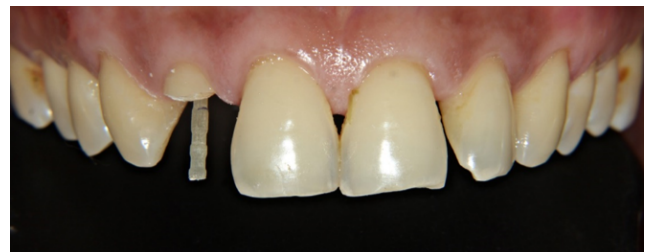

**Fig. 6:** Sectional obturation in tooth #12

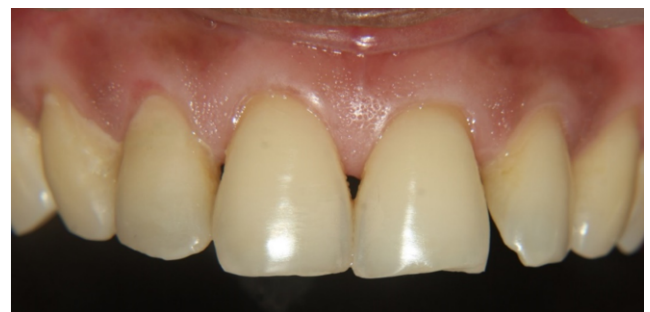

**Fig. 7:** Fiber post seating verification

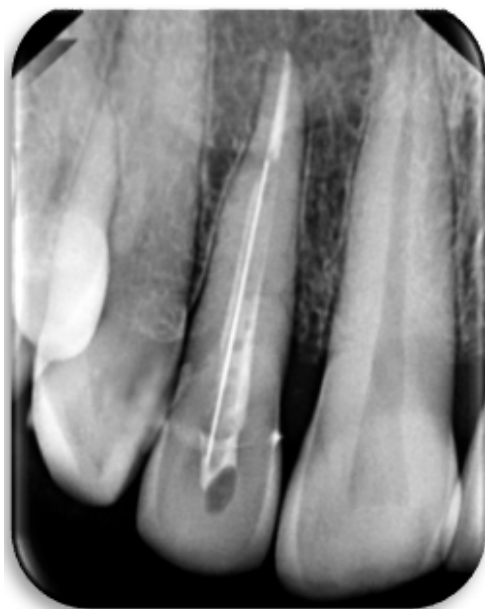Immediate post-space preparation was performed using Pecho reamer number 2 and 3 (Mani Inc. Japan) to the designated length, followed by radiographic confirmation of seating of fiber post no. 2 (Reforpost Angelus). (Figure 7). After confirming the fit of the post, an excess of 2mm of the post was trimmed (Figure 8). The tooth fragment was then prepared accordingly to receive the selected core portion of the post. Then the post, and the tooth fragment, were approximated to the tooth to check for any discrepancies. The post space, fiber post, and tooth fragment were etched using 37% phosphoric acid (Ivoclar N Etchant) for 20 seconds, followed by the application of a universal bonding agent (Tetric N-Bond Universal Ivoclar Vivadent) for 30 seconds, and light-cured for 20 seconds (i-LED plus, Guilin Woodpecker Medical Instrument Co Ltd). Silane was then applied to the fiber post. The fiber post was cemented into the post space using dual-cure resin cement (Calibra Universal, Dentsply Sirona). A radiograph was taken to confirm the cementation of the post to the determined length. The tooth fragment was then cemented using the same dual-cure cement. The final position of the fragment in centric and lateral occlusion was checked and light-cured immediately (Figure 9). The flash was removed and a confirmatory radiograph was taken to verify its position. Finishing and polishing were done as per the standard protocol for composite finishing. The patient was asymptomatic with no mobility, or tenderness, after a follow-up of 6 month and 1 year.(Figures 9, 10 and 11)



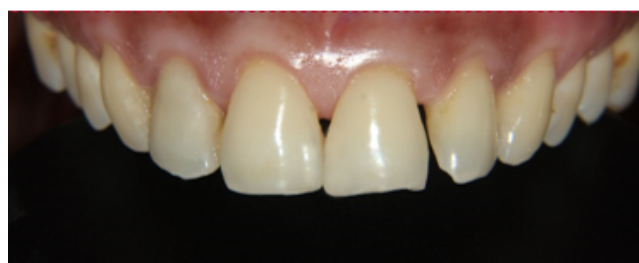**Fig. 8:** Cementation of Fiber post



**Fig. 9:** Photograph of a 6-month follow-up labial view



**Fig. 10:** Six-month follow-up radiograph



**Fig. 11:** Photograph of a 1-year follow-up labial view.

### 3. Discussion

Trauma to the anterior teeth may cause disturbance not only in aesthetics, phonetics, and function, but also has a profoundly negative psychological impact on the patient. Thus, making immediate restoration of the fractured tooth imperative. In the literature various treatment modalities for rehabilitation of CRF like direct composite, indirect composite, crown, fiber post, cast post, and fragment reattachment have been advocated.<sup>6–9</sup> The first case of fragment reattachment was reported by Chosack for a complicated crown root fracture.<sup>10</sup> Fragment reattachment is considered a viable option for management of crown-root fracture because of its ease of operation, less chairside time, natural aesthetics, and predictable outcome.<sup>2,5,9,11,12</sup>

The current case presented with a complete oblique and complicated crown root fracture. The coronal fragment was anchored to the tooth solely due to soft tissue attachment. For this reported case, three treatment modalities were available: orthodontic extrusion, gingivectomy, and fragment reattachment. Orthodontic or surgical extrusion of the tooth with or without gingivectomy has been suggested

in the literature for fractures extending sub-gingivally.<sup>9,13,14</sup> In the reported case, the fractured margin was below the gingival contour but above the alveolar crest and accessible; therefore, immediate reattachment without gingivectomy was planned.

The fiber post serves as an anchor and allows the reattachment by preparing an internal dentinal groove through the displaced fragment.<sup>9</sup> Fiber post has dentin-like properties and creates a monobloc effect when cemented with dual-cure resin cement. It also reinforces the tooth and ultimately increases the fracture resistance of the tooth.<sup>15</sup> Literature recommends a minimum follow-up of 1–5 years to judge the outcome of any traumatic injuries.<sup>16,17</sup> After a follow-up of 1 year the patient was clinically asymptomatic and the radiographs showed promising results. The patient has been kept under observation and will require further follow-up.

### 4. Conclusion

Fragment reattachment is a minimally invasive technique to restore tooth contact, contours, texture, and lustre. Re-attached tooth fragment has wear rates comparable to adjacent natural teeth in contrast to other treatment modalities. Thus, weighing the risk-benefit ratio, fragment reattachment with an intermediate anchor material is the treatment of choice in cases of such traumatic injuries.

### 5. Conflict of Interest

The authors declare no relevant conflicts of interest.

### 6. Source of Funding

None.

### References

1. Andreasen JO. Etiology and pathogenesis of traumatic dental injuries. A clinical study of 1,298 cases. *Scand J Dent Res.* 1970;78(4):329–42.
2. Garcia FCP, Poubel DLN, Almeida JCF, Toledo IP, Poi WR, Guerra ENS, et al. Tooth fragment reattachment techniques-A systematic review. *Dent Traumatol.* 2018;34(3):135–43.
3. Diangelis AJ, Andreasen JO, Ebeleseder KA, Kenny DJ, Trope M, Sigurdsson A, et al. International Association of Dental Traumatology guidelines for the management of traumatic dental injuries: 1. Fractures and luxations of permanent teeth. *Dent Traumatol.* 2012;28(1):2–12.
4. Bruschi-Alonso RC, Alonso RCB, Correr GM, Alves MC, Lewgoy HR, Sinhorette MAC, et al. Reattachment of anterior fractured teeth: Effect of materials and techniques on impact strength. *Dent Traumatol.* 2010;26(4):315–22.
5. Andreasen FM, Norén JG, Andreasen JO, Engelhardtson S, Lindh-Strömberg U. Long-term survival of fragment bonding in the treatment of fractured crowns: a multicenter clinical study. *Quintessence Int.* 1995;26(10):669–81.
6. Arhun N, Ungor M. Re-attachment of a fractured tooth: a case report. *Dent Traumatol.* 2007;23(5):322–6.
7. Szmidi M, Górski M, Barczak K, Buczkowska-Radlińska J. Direct Resin Composite Restoration of Maxillary Central Incisors with Fractured Tooth Fragment Reattachment: Case Report. *Int J Periodontics Restor Dent.* 2017;37(2):249–53.

8. Ulusoy AT, Tunc ES, Cil F, Isci D, Lutfioglu M. Multidisciplinary treatment of a subgingivally fractured tooth with indirect composite restoration: a case report. *J Dent Child.* 2012;79(2):79-83.
9. Zorba YO, Özcan E. Reattachment of Coronal Fragment Using Fiber-Reinforced Post: A Case Report. *Eur J Dent.* 2007;01(03):174-78.
10. Chosack A, Eidelman E. Rehabilitation of a fractured incisor using the patient's natural crown. Case report. *J Dent Child.* 1964;31:19-21.
11. Khandelwal P, Srinivasan S, Arul B, Natanasabapathy V. Fragment reattachment after complicated crown-root fractures of anterior teeth: A systematic review. *Dental Traumatology.* 2021;37(1):37-52.
12. Deepa VL, Reddy SN, Garapati VC, Sudhamashetty SR, Yadla P. Fracture fragment reattachment using projectors and anatomic everstick postTM: An ultraconservative approach. *J Int Soc Prevent Communit Dent.* 2017;7(S1):52-4.
13. Caliskan MK, Gomel M, Turkun M. Surgical extrusion of intruded immature permanent incisors: case report and review of the literature. *Oral Surg Oral Med Oral Pathol Oral Radiol Endod.* 1998;86(4):461-4. doi:10.1016/s1079-2104(98)90374-2.
14. Johnson RH. Lengthening clinical crowns. *J Am Dent Assoc.* 1990;121(4):473-6. doi:10.14219/jada.archive.1990.0207.
15. Deepak B, Sophia T, Deepa J, Mallikarjun G. The concept of monobloc in Endodontic - A review. *CODS J Dent.* 2014;6(2):83-9.
16. Mehta S, Verma J. Systematic Review on Relation Between Surface Treatment and Outcome of Delayed Replantation of Permanent Anterior Avulsed Teeth. *J Clin Diagn Res.* 2021;15(6):1-4.
17. Mendes L, Laxe L, Passos L. Ten-Year Follow-Up of a Fragment Reattachment to an Anterior Tooth: A Conservative Approach. *Case*

*Rep Dent.* 2017;p. 2106245. doi:10.1155/2017/2106245.

## Author biography

**Shaili Mehta**, Post Graduate Student

**Manoj Ramugade**, Associate Professor

**Abrar Sayed**, Professor (Academic) and HOD

**Kishor Sapkale**, Associate Professor

**Sapna Sonkurla**, Associate Professor (Academic)

**Sangeeta Ambhore**, Assistant Professor

**Cite this article:** Mehta S, Ramugade M, Sayed A, Sapkale K, Sonkurla S, Ambhore S. Endo-Aesthetic rehabilitation of complicated crown-root fracture of maxillary lateral incisor by fragment reattachment: A case report. *IP Indian J Conserv Endod* 2022;7(2):89-93.