

Content available at: <https://www.ipinnovative.com/open-access-journals>

IP Indian Journal of Conservative and Endodontics

Journal homepage: <https://www.ijce.in/>

## Case Report

# Management of intrinsic discoloration in maxillary incisors with the walking bleach: A case report

Rahul Grover<sup>1</sup>, Ruchi Singla<sup>2,\*</sup>

<sup>1</sup>Dept. of Conservative Dentistry & Endodontics, Dentamax Dental Clinic, Faridabad, Haryana, India

<sup>2</sup>Dept. of Conservative Dentistry & Endodontics, Dr. Harvansh Singh Judge Institute of Dental Sciences & Hospital, Panjab University, Chandigarh, India



### ARTICLE INFO

#### Article history:

Received 02-05-2022

Accepted 24-05-2022

Available online 13-06-2022

#### Keywords:

Discolored teeth

Hydrogen peroxide

Walking bleach

### ABSTRACT

**Background:** In the age of minimally invasive dentistry and increasing aesthetic demands, walking bleach is the most effective and conservative method. Hydrogen peroxide is one of the commonly used bleaching agent. This case report illustrates the walking bleach technique in maxillary incisors with hydrogen peroxide.

**Case Report:** A 35 years old female reported with discoloured endodontically treated maxillary incisors. Retreatment of maxillary incisors followed by walking bleach was planned. Glass ionomer cement was used as a barrier material. 35% hydrogen peroxide was placed in the pulp chamber with intermediate restorative material. The procedure was repeated after 5 days to achieve the desired results.

**Conclusion:** 35% hydrogen peroxide can successfully bleach discolored endodontically treated teeth.

**Key message:** Walking bleach technique is an incredibly effective approach for discolored intact non-vital teeth. It is rapid and easy to obtain desired results as well as economical to patients as compared to crowns and veneers.

This is an Open Access (OA) journal, and articles are distributed under the terms of the [Creative Commons Attribution-NonCommercial-ShareAlike 4.0 License](https://creativecommons.org/licenses/by-nc-sa/4.0/), which allows others to remix, tweak, and build upon the work non-commercially, as long as appropriate credit is given and the new creations are licensed under the identical terms.

For reprints contact: [reprint@ipinnovative.com](mailto:reprint@ipinnovative.com)

## 1. Introduction

Tooth discoloration can be caused by several intrinsic and extrinsic factors.<sup>1</sup> Extrinsic factors (external) that create surface stains can induce tooth discoloration. Smoking, red wine, coffee, and tea are some of the things that cause these stains.<sup>2</sup> By deep cleaning the teeth, many over-the-counter solutions can help with tooth discoloration. To remove stains, a peroxide solution or simply abrasive materials could be used.

Heredity, ageing, dental decay, trauma, loss of vitality or some medications can cause intrinsic stains that are more difficult to remove.<sup>3,4</sup> Even the most powerful whiteners will have no impact in these situations. For such discoloured

teeth, treatment options include tooth bleaching, veneering, or the placement of a full coverage crown.

When it comes to the treatment of anterior non-vital discoloured teeth, intra-coronal bleaching with the Walking Bleach technique is a widely accepted method.<sup>5,6</sup> It was presented by Spasser<sup>7</sup> and later changed by Nutting and Poe.<sup>8</sup> It is done in an endodontically treated tooth and is a non-invasive conservative procedure as compared to veneers and crowns.

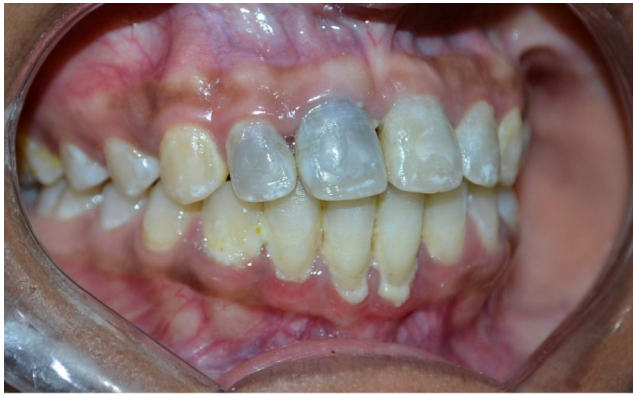This article presents the successful management of intrinsic stains in non-vital maxillary incisors by walking bleach.

\* Corresponding author.

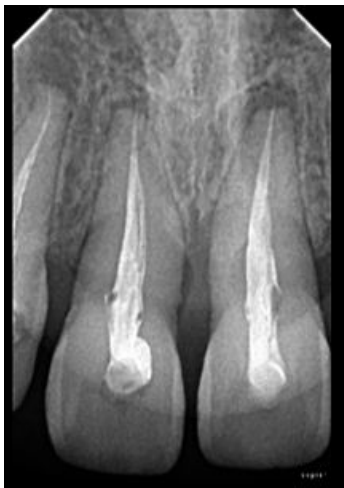E-mail address: [dr.ruchisingla@gmail.com](mailto:dr.ruchisingla@gmail.com) (R. Singla).

## 2. Case Report

A 35yrs old female presented with chief complain of discoloured upper anterior teeth. Patient gave history of orthodontic treatment 5yrs ago and root canal treatment of maxillary incisors. On intraoral examination, tooth #11, #12 found black discoloration and #21, #22 mildly discoloured Figure 1. Intraoral radiograph revealed #11, #21, #22, #12 was root canal treated Figure 2. Patient was dissatisfied from her orthodontic treatment also. A treatment plan was made and discussed with her.

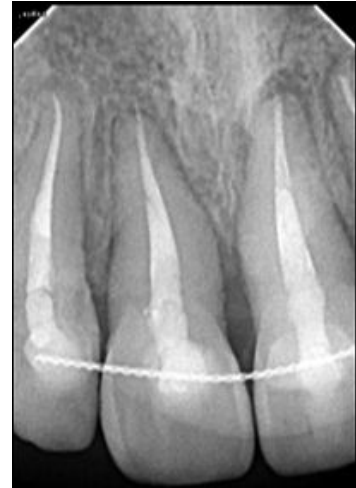

**Fig. 1:** Preoperative Intraoral photograph showing discolored maxillary incisors

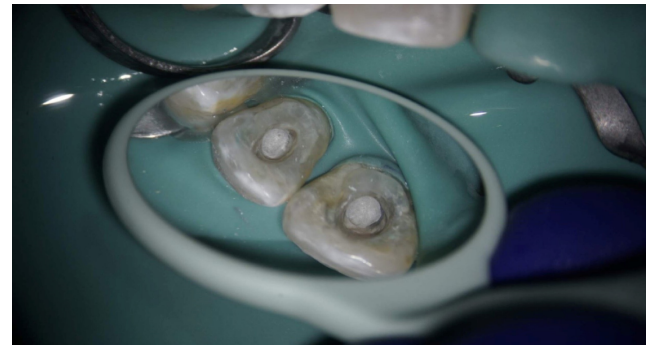

**Fig. 2:** Intraoral radiograph showing root canal treated maxillary incisors

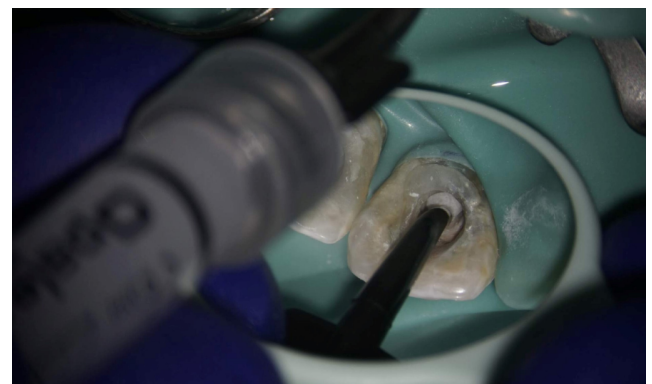
Orthodontic retreatment and retreatment of #11, #12 followed by intracoronal bleaching was planned. After completion of orthodontic treatment, we started with endodontic treatment. #11, #12 were isolated with rubber dam. Gutta percha was removed. Biomechanical preparation of canals was done with Protaper next F2. Canals were irrigated with saline and sodium hypochlorite while



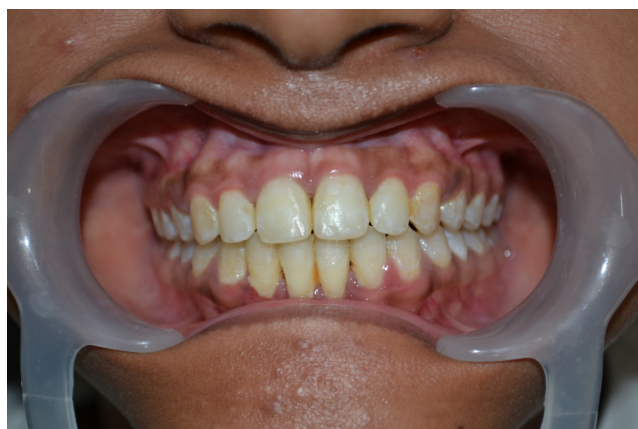**Fig. 3:** Intraoral radiograph showing obturated maxillary incisors



**Fig. 4:** Placement of Glass Ionomer Cement as barrier



**Fig. 5:** Placement of Opalescence Endo in pulp chamber



**Fig. 6:** Photograph showing bleached maxillary incisors

preparation. Canals were dried with absorbent points and obturated with corresponding gutta percha Figure 3. Cavity was sealed with Coltisol F (Coltene Whaledent, Alstatten, Switzerland).

In next visit, baseline tooth shade was recorded and photographs were taken as reference for measuring the color change. Teeth were isolated with rubber dam. Temporary restoration was removed. 2mm of gutta percha was removed beyond cemento-enamel junction. 2mm of glass ionomer cement (3M ESPE, USA) was placed over gutta percha as barrier Figure 4. Opalescence Endo (Ultradent, South Jordan) was placed in the pulp chamber Figure 5. The excess was removed with cotton and cavity was sealed with Coltisol F.

Patient was recalled after 5 days and showed improvement in discoloration. After 3 days, the patient was recalled and the bleaching procedure was repeated. The discoloration was completely removed, and the patient's shade was improved. With plenty of saline, Opalescence Endo was removed. Abrasion was used to clean the access cavity, and Coltisol F was used to seal it. Patient was recalled after 15 days. Access was acid etch and restored with nanohybrid composite.

Patient was satisfied with results and requested for bleaching of #21, #22. As for #11, #12 bleaching procedure was followed for #21, #22 and obtained desired results Figure 6. 1yr follow up showed no recurrence of discoloration.

### 3. Discussion

Walking bleach is the minimally invasive procedure for esthetic rehabilitation of discolored non vital teeth. We used Opalescence Endo whitening gel it contains 35% hydrogen peroxide and is available in convenient ready-to-use syringes.

Any chemical with two oxygen atoms is referred to as a peroxide. The addition of hydrogen produces hydrogen

peroxide, an oxidising agent. This means it has the potential to produce a chemical process in which the oxygen atoms lose electrons, changing the substance to which it is applied. When it comes to teeth whitening, hydrogen peroxide causes a chemical reaction that dissolves stains on the teeth. It is an effective bleaching agent as it can break the organic structures into shorter lighter in color molecules.<sup>9</sup> Nowadays, most commonly and active agent used in whitening products is hydrogen peroxide.

Carbamide peroxide is a mixture of hydrogen peroxide and carbamide or urea, a chemical molecule. While carbamide peroxide has a somewhat different chemical makeup than hydrogen peroxide, it is an oxidising agent that works in the same way on stains.

Both hydrogen peroxide and carbamide peroxide affect the chemical composition of stains when applied to teeth. As a result, they're sometimes called bleaching agents rather than whitening agents. While many dentists do not distinguish between the two terms, bleaching typically refers to the use of chemicals to change the colour of tooth enamel, whereas whitening simply refers to the removal of surface stains caused by substances such as coffee or wine.

External cervical resorption is a serious side effect of walking bleach.<sup>10</sup> It is typically asymptomatic and is diagnosed through routine radiographic examination. It is preferred that bleaching be limited to the supragingival chamber and that the dentinal tubules be protected by the use of a barrier base. To prevent bleaching chemicals from percolating into the periodontal region, at least a 3-4 mm thick base should be applied.<sup>11</sup> Glass ionomer cement was used as the barrier material in our case.

It is recommended that resin composite restoration be postponed for at least 1–3 weeks after the bleaching is finished. Follow-up visits are recommended once a year to monitor the outcome and, if the clinician notices a regression of the initial result, repeat the bleaching treatment to maintain the ideal aesthetic colour.

### 4. Conclusion

With the advancement of modern cosmetic dentistry, a variety of treatments for treating non vital tooth discoloration are now available. "Walking" bleach is one of the oldest procedures, the bleach technique is being used today. It is an incredibly effective approach for rapidly and easily obtaining desired results as well as being financially feasible.

### 5. Conflict of Interest

The authors declare no relevant conflicts of interest.

### 6. Source of Funding

None.

## References

1. Watts A, Addy M. Tooth discoloration and staining: a review of the literature. *Br Dent J.* 2001;190(6):309–16.
2. Carey CM. Tooth whitening: what we now know. *J Evid Based Dent Pract.* 2014;(14):70–6. doi:10.1016/j.jebdp.2014.02.006.
3. Wray A, Welbury R. UK National Clinical Guidelines in Paediatric Dentistry: Treatment of intrinsic discoloration in permanent anterior teeth in children and adolescents. *Int J Paediatr Dent.* 2001;11(4):309–15. doi:10.1046/j.1365-263x.2001.00300.x.
4. Zimmerli B, Jeger F, Lussi A. Bleaching of nonvital teeth- A clinically relevant literature review. *Schweiz Monatsschr Zahnmed.* 2010;120(4):306–20.
5. Chng HK, Palamara JEA, Messer HH. Effect of hydrogen peroxide and sodium perborate on biomechanical properties of human dentin. *J Endod.* 2002;28(2):62–7. doi:10.1097/00004770-200202000-00003.
6. Plotino G, Buono L, Grande NM, Pameijer CH, Somma F. Nonvital Tooth Bleaching: A review of literature and clinical procedures. *J Endod.* 2008;34(4):394–407.
7. Spasser HF. A simple bleaching technique sodium perborate. *NYS Dent J.* 1961;27(8-9):332–4.
8. Nutting EB, Poe GS. A new combination for bleaching teeth. *J South Calif Dent Assoc.* 1963;31(9):289–91.
9. Bahuguna N. Cervical root resorption and nonvital bleaching. *Endodon.* 2013;25(2):106–11.
10. Macisaac AM, Hoen CM. Intracoronal bleaching: concerns and considerations. *J Can Dent Assoc.* 1994;60(1):57–64.
11. Sherwood AI, Miglani RS, Lakshminarayan L. Efficacy of glass ionomer as a barrier material in non-vital bleaching -A stereomicroscopic study. *Endod.* 2004;16:12–5.

## Author biography

**Rahul Grover**, Private Practitioners

**Ruchi Singla**, Senior Assistant Professor

**Cite this article:** Grover R, Singla R. Management of intrinsic discoloration in maxillary incisors with the walking bleach: A case report. *IP Indian J Conserv Endod* 2022;7(2):94-97.