

Content available at: <https://www.ipinnovative.com/open-access-journals>

IP Indian Journal of Conservative and Endodontics

Journal homepage: <https://www.ijce.in/>

Case Series

Surgical removal of periapical pathology with root end resection

Sugandha Sati^{1,*}, Aryama Balodi¹, Advaita Anand¹, Ayushi Bangari¹, Annil Dhingra¹

¹Dept. of Conservative and Endodontics, Seema Dental College and Hospital, Rishikesh, Uttarakhand, India



ARTICLE INFO

Article history:

Received 01-02-2023

Accepted 09-03-2023

Available online 12-04-2023

Keywords:

Surgical

Endodontology

Periradicular surgery

ABSTRACT

In children and young adults, traumatic dental injuries (TDIs) to permanent teeth are common. Of all dental injuries, crown fractures and luxations of these teeth are the most frequent. For a successful outcome, accurate diagnosis, treatment planning, and follow-up are critical. This article presents a case report series of surgical management of traumatic injury with periapical lesion with root end resection using root end filling materials.

This is an Open Access (OA) journal, and articles are distributed under the terms of the [Creative Commons Attribution-NonCommercial-ShareAlike 4.0 License](https://creativecommons.org/licenses/by-nc-sa/4.0/), which allows others to remix, tweak, and build upon the work non-commercially, as long as appropriate credit is given and the new creations are licensed under the identical terms.

For reprints contact: reprint@ipinnovative.com

1. Introduction

Apical surgeries with root end resection prevent bacterial microleakage from root canal system to periradicular tissue. As proposed by Lieblisch periapical surgery has to be performed in a tooth with no evidence of fracture and with an adequate periodontal status (less than 25% of vertical bone loss and periodontal pockets < 5 mm). Furthermore, the tooth must retain sufficient coronary structure for prosthesis and the patient should be able to tolerate the surgery.

Indications for apical surgery have been recently updated by the ESE (European Society of Endodontology, 2006) and include the following:

1. Radiological findings of apical periodontitis and/or symptoms associated with an obstructed canal (the obstruction proved not to be removable, displacement did not seem feasible or the risk of damage was too great).
2. Extruded material with clinical or radiological findings of apical periodontitis and/or symptoms continuing over a prolonged period.

3. Persisting or emerging disease following root-canal treatment when root canal re-treatment is inappropriate.
4. Perforation of the root or the floor of the pulp chamber and where it is impossible to treat from within the pulp cavity.

Contraindications for apical surgery include inadequate periodontal health, tooth with vertical root fracture, compromised medical history such as blood dyscrasias, uncontrolled diabetes.¹⁻⁵

2. Case Report 1

A patient came to the department with the chief complaint of swelling and mobility of teeth in upper front tooth region for 6 month. On taking the history, it was revealed that patient had met with an accident during her childhood. On examination grade 2 mobility was seen. Radiograph revealed a large periapical lesion involving 11 and 12.

Treatment plan was made of root canal therapy w.r.t 11, 12 followed by root end resection w.r.t 11 Prior to surgery, hematological investigations were carried out and the patient signed written consent. Antibiotics and Chlorhexidine mouth.

* Corresponding author.

E-mail address: sugandha.sati@gmail.com (S. Sati).

Ash was prescribed, a day before surgery.

On the first appointment pre operative impressions were recorded with pre operative photographs. Following the injection of 2% lignocaine and epinephrine local anaesthesia (1:100000).

On the first appointment pre operative impressions were recorded with pre operative photographs. Following the injection of 2% lignocaine and epinephrine local anaesthesia (1:100000). On tooth No. 11,12, an access opening was done. The working length was determined using an apex locator and was confirmed by a periapical radiograph. Cleaning and shaping were done up to master apical file and obturated with master cone. After completing the root canal procedure, a provisional restoration was given.

On the next appointment Surgical Intervention was carried out. After preparing the mouth, rinse with providine-iodine, swab, local anesthesia (2% lidocaine and 1:100,000 epinephrine) was administered. Prior to the incision placement, incision markings were made and bleeding points were marked, 15c blade and bard Parker Grip was used to place the incisions. A full mucoperiosteal flap was raised. After elevating the flap and inspecting, a breach in the cortical bone was located. A round carbide bur under constant irrigation for cooling was used to enlarge bony defect to the buccal window to gain access to the periapical lesion and root end of the tooth with defect.

The soft granulation was then removed using a curette, Hemostasis was achieved through the use of sterilant gauze.

The tip of 3mm was excised at a 90 angle, Under constant watering. A retrograde preparation was done and cavity was filled with Biodentin. Single interrupted sutures were Given.

The patient was then advised to follow post-operative instructions such as to apply cold compresses with an ice pack for 4–6 hours after surgery, followed by betadine mouth rinses to maintain a good oral hygiene. The patient was prescribed antibiotics and analgesics for 5 days. The patient was recalled after 3 days to evaluate the surgical site for healing and the absence of signs and symptoms such as pain and sinus tract. After 7 days, post-operative, the sutures were removed.

3. Case Report 2

A 32 -year-old male came to the Department of Conservative Dentistry and Endodontics (Seema Dental College and Hospital) with the chief complaint of pain and pus discharge for 1 week. Patient gave history of trauma 3 years back while playing football. It was seen that the root canal treatment w.r.t 22 was initiated by the previous dentist. Patient gave no history of any systemic illness. On examination, there was no obvious swelling. On radiographic examination periapical radiolucency involving 21 and 22 can be well appreciated. Diagnosis made was Ellis class IV fracture. Treatment plan made was root canal treatment followed by root end resection. On the

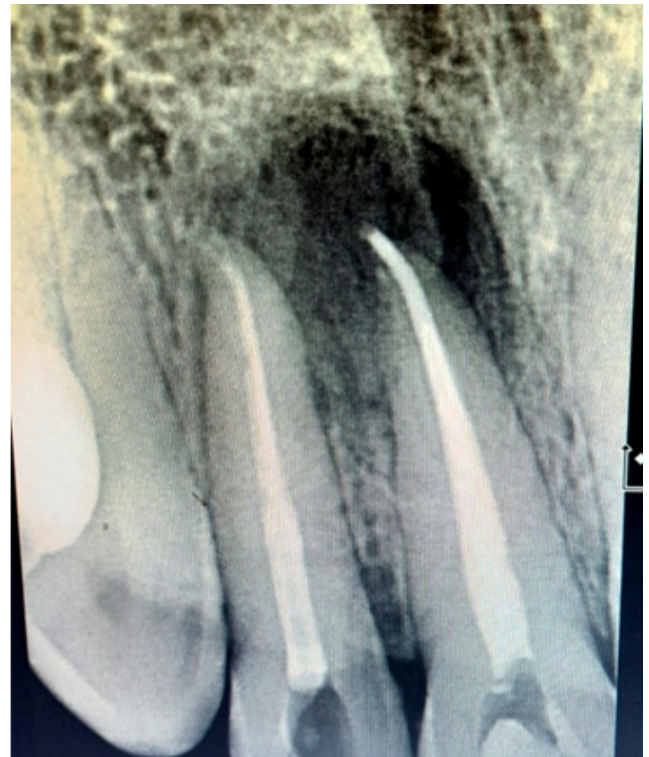

Fig. 1: Preoperative radiograph

1st appointment access opening irt to 21 was done then Working length was determined, shaping and cleaning was done irt 21 and 22. Intra canal medicament was placed up till the day of surgery. Obturation was done during the surgery by root end resection.

4. Case Report 3

An 18-year-old male patient came to the department with the chief complain of broken teeth in the upper front tooth region for 1 year. On taking the history, it was revealed that patient had met with an accident during his childhood by falling from the bed due to which he broke his upper front teeth.

Intra oral examination showed no lacerations, signs of alveolar bone fractures, or gingival irritation. On percussion, the tooth was judged non-tender. A class III fracture was seen in the maxillary right central incisor and maxillary right central lateral incisor. There was no tooth movement. The tooth electric pulp test and other vitality tests were inconclusive, indicating non-vital i.e Ellis Class IV fracture. Periapical X-rays showed complete root apical development of the affected tooth and periapical radiolucency at the apex of the teeth w.r.t 11, 12.

Treatment plan was made of root canal therapy w.r.t 11,12 followed by root end resection w.r.t 11,12 and bone graft placement

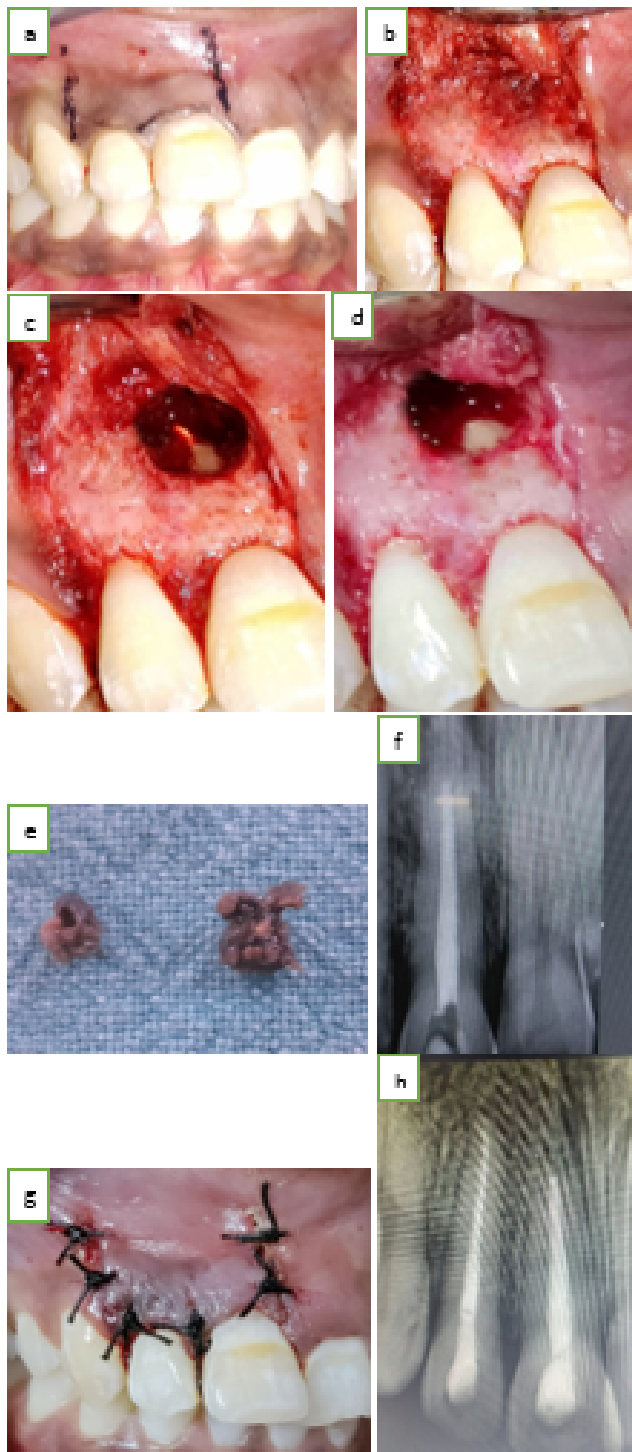


Fig. 2: a: Marking of the flap; b: Flap raised; c: Bony window created; d: Root end resected; e: Granulomatous tissue removed; f: Biodentin placed; g: Sutures placed; h: 6 months follow up

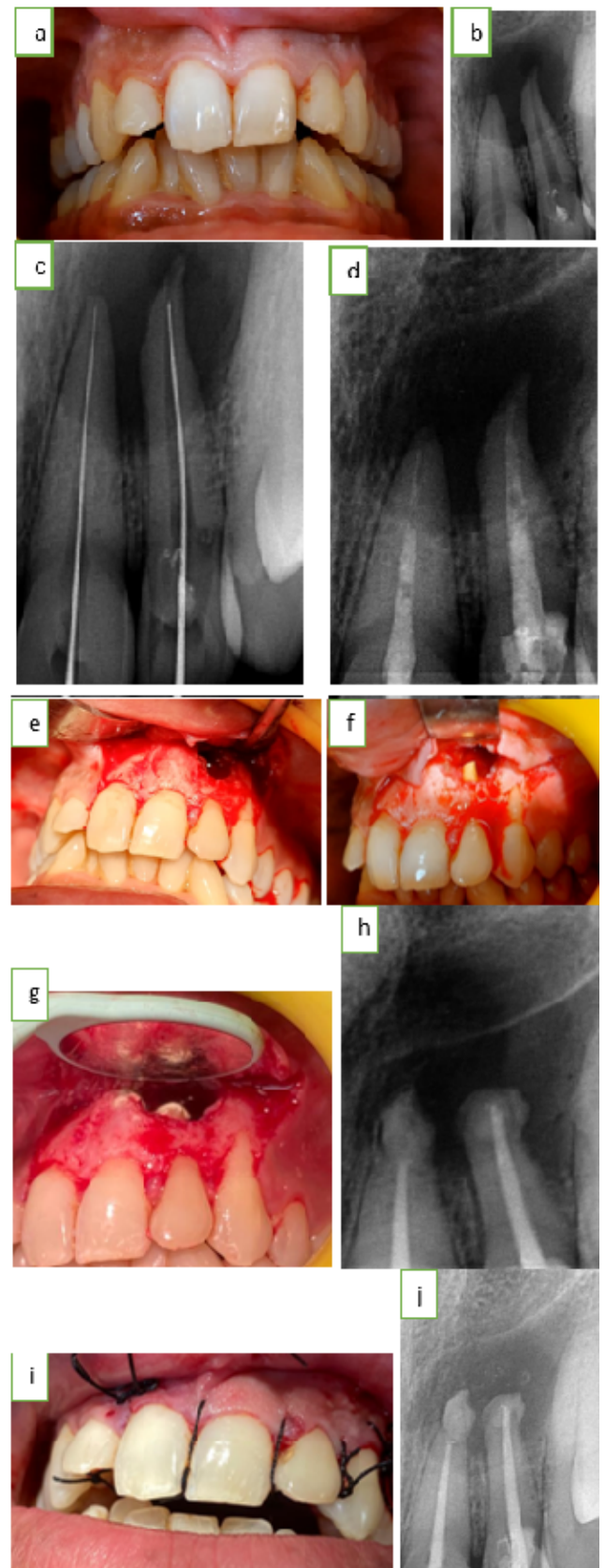


Fig. 3: a: Pre-operative image; b: Preoperative radiograph; c: Working length determination; d: Intracanal medicament; e: Full thickness mucoperiosteal flap raised; f: Root end resection; g: Retrograde mta filling image; h: Retrograde mta filling radiograph; i: Sutures placed; J: 6 month follow up.

Prior to surgery, hematological investigations were carried out and the patient signed written consent. Antibiotics and Chlorhexidine mouthwash was prescribed, a day before surgery.

On the first appointment pre operative impressions were recorded with pre operative photographs. Following the injection of 2% lignocaine and epinephrine local anaesthesia (1:100000). On tooth No. 11,13, an access opening was made using an endo access bur (DENTSPLY Maillefer, Switzerland). The working length was determined using an apex locator and was confirmed by a periapical radiograph. The root canal was then enlarged to ISO size 70 at the working length. Complete biomechanical preparation was then carried out using the step-back technique. During preparation, thorough irrigation with 2.5% sodium hypochlorite was carried out. The master cone was then confirmed by taking a radiograph, root canal obturation was done using down pack and back fill technique and then a radiograph after obturation was taken. After completing the root canal procedure, a provisional restoration was given.

On the next appointment Surgical Intervention was carried out. After preparing the mouth, rinse with povidine-iodine, swab, local anesthesia (2% lidocaine and 1:100,000 epinephrine) was administered. Prior to the incision placement, incision markings were made and bleeding points were marked, 15c blade and bard Parker Grip was used to place the incisions. For this case we used oscheinebein flap.

After elevating the flap and inspecting, a breach in the cortical bone was located. A round carbide bur under constant irrigation for cooling was used to enlarge bony defect to the buccal window to gain access to the periapical lesion and root end of the tooth with defect.

The soft granulation was then removed using a curette. The organization further assisted in the proper visualization of root tip. Hemostasis was achieved through the use of steriltant gauze.

The tip of 3mm was excised at an acute angle.10 degrees in the facial-lingual direction to the long axis of the Tooth with conical Fischer drill in high-speed handpiece, Under constant watering. The cavity was then filled aafter complete isolation, reverse the filling material.

A was the material of choice for the retrograde restoration. At the end bone graft was place in the cavity Careful evaluation and copious irrigation with normal saline of the surgical site was done to ensure complete debridement of a hemostatic agent, root-end filing material, and debris, which may hinder the process of healing. A damp gauze piece was slightly compressed to bring back the flap in position. Single interrupted sutures were Given The patient was then advised to follow post-operative instructions such as to apply cold compresses with an ice pack for 4–6 hours after surgery, followed by betadine mouth rinses to maintain a good oral hygiene. The patient

was prescribed antibiotics and analgesics for 5 days. The patient was recalled after 3 days to evaluate the surgical site for healing and the absence of signs and symptoms such as pain and sinus tract. After 7 days, post-operative, the sutures were removed.

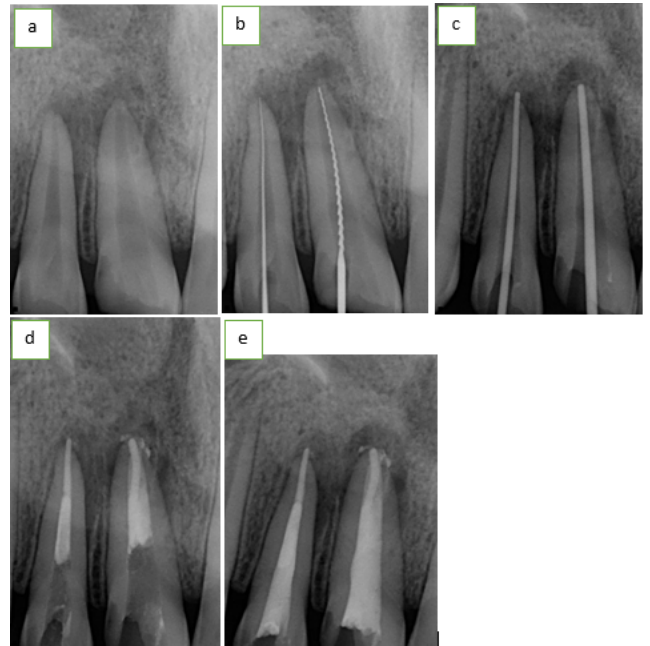


Fig. 4: a: Preoperative; b: Working length; c: Mastercone; d: Down pack; e: Backfill

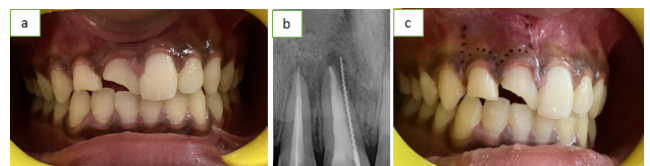


Fig. 5: a,b: Pre-operative; c: Incision markings

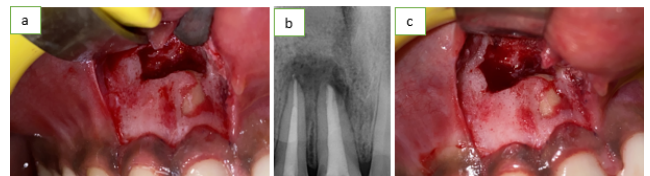


Fig. 6: a,b: Bony window; c: Root end resection

5. Case Report 3

An 18-year-old patient reported to the department with a chief complaint of pain in the upper front tooth region for 1 week. There was an history of fall from bike 1 week back

On clinical examination there was Ellis Class 3 fracture i.r.t 11,21 and radiographic examination revealed

radiolucency involving enamel, dentin and pulp i.r.t 11,12 and a periapical radiolucency i.r.t 11. Cold test was negative i.r.t 11 and lingering response i.r.t 21 Teeth presented a delayed response to electric pulp testing i.r.t 11 and no response i.r.t 21. The treatment planned was root end resection w.r.t 11 with retrograde filling of MTA. It was explained to the patient and consent was obtained. After the access opening of 11,21 was done, the working length was determined using k file and thorough shaping and cleaning was done. The teeth were then obturated using warm vertical condensation.

Raising Ochsensbein – Luebke (O-L) Flap, a periapical surgery was performed and periapical pathosis was enucleated. 3mm root end resection and retrograde cavity was prepared using ultrasonic tip. PRF was placed of 3mm thickness. The placement of the PRF was confirmed using a radiograph and the sutures were placed. The patient was recalled after 10 days for suture removal. The patient was kept under observation for the purpose of postoperative evaluation of healing of the periapical intervention in intervals of 1, 3 months.

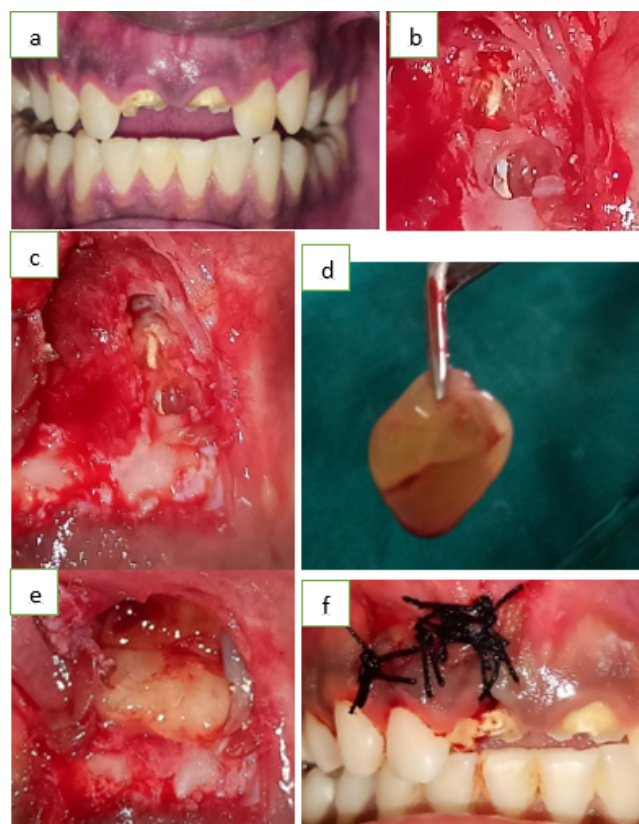


Fig. 7: a: Preoperative image; b: Bony window created; c: Root end resected; d: Plasma rich fibrin; e: PRF placed; f: Sutures placed

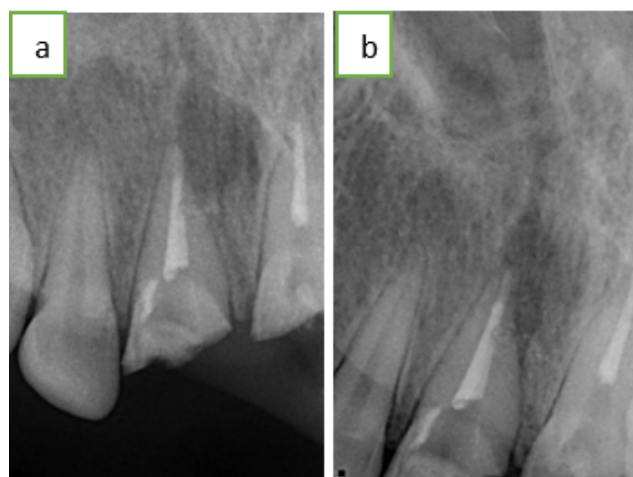

Fig. 8: a: 1 month follow up; b: 3 month follow up

6. Discussion

Gaining access to the afflicted area, examining the root circumference and root canal anatomy, and installing a biocompatible seal in the form of a root end filling that promotes periapical tissue regeneration are the objectives of a periradicular surgery.⁶

The flap design should be chosen primarily to facilitate surgical access to the periapical lesion and root and must always follow the basic principles to guarantee adequate vascularization of the flap.⁷

In this article a full thickness flap and oschenbein luebke flap was raised. Sounding the bone with the sharp end of the periosteal elevator was done, as there is a change in resonance when one approaches the diseased area. It is also prudent to identify the root by calculating twice the crown length and then shave the thin bone at the apex.⁸

The bony aperture was widened enough to permit visual and surgical access into the lesion, enabling the insertion of bone curettes and excavators the instrument was inserted between the tissue and the lateral edge of the cavity with its concave face toward the bone. This is continued all around the circumference of the cavity and slowly progressed toward the depth of the crypt in a scraping manner. After freeing all the tissue, it was gently grasped with a pair of tissue forceps and immersed in 10% buffered formalin solution and the granulomatous tissue was removed.

Resection of apical 3 mm of the root apex was done this will eliminate 78% of apical ramifications and 93% of lateral canals, which could contain material that would contribute to the periradicular disease. A 3 mm-deep Class I cavity was prepared along the long axis of the tooth, in order to place the filling material. Ultrasonic tips have been specifically designed for this purpose. The tips produce less smear layer, need less bevelling, and can be inserted through a smaller aperture. Mineral tri oxide aggregate was placed in the retrograde cavity prepared. The surgical site was gently

cleaned and irrigated with sterile saline to remove debris of haemostatic agents and filling materials.

The flap was repositioned and delicately compressed with a moist gauze to vent out the excess blood, and tissue fluids 3–0 Silk suture material was used followed by Compressing the flap with sterile ice packs in the immediate postoperative period minimizes the thickness of the fibrin clot and enhances wound healing.^{9,10}

3 month and 6 month follow up showed bone formation and reduced periapical radiolucency suggesting healthy bone formation.

7. Conclusion

In order to save a tooth with apical pathology that cannot be treated by traditional, non-surgical endodontics, apical surgery is now seen as a dependable therapy option. A good quality apical seal can be obtained using root end filling materials contributing to the success of the treatment. Mineral Trioxide Aggregate is a material for root-end filling. apices and necrotic pulp along with periapical radiolucency of considerable size.

8. Source of Funding

None.

9. Conflicts of interest

There are no conflicts of interest.

References

- Serrano-Giménez M, Sánchez-Torres A, Gay-Escoda C. Prognostic factors on periapical surgery: A systematic review. *Med Oral Patol Oral Cir Bucal*. 2015;20(6):715–22. doi:10.4317/medoral.20613.
- von Arx T. Apical surgery: A review of current techniques and outcome. *Saudi Dent J*. 2011;23(1):9–15. doi:10.1016/j.sdentj.2010.10.004.
- Franco PB, Karlis V. Apicoectomy in atlas of oral and maxillofacial surgery. Kademani D, Tiwana P, editors. St. Louis, MO: Elsevier; 2016.
- Ajayi J. Comparative study of treatment outcome in apicectomies with or without root-end filling. *Ann Ibadan Postgraduate Med*. 2018;16(2):109–14.
- Wang N, Knight K, Dao T, Friedman S. Treatment outcome in endodontics: the Toronto Study. Phases I and II: apical surgery. *J Endod*. 2004;30(11):751–61. doi:10.1097/01.don.0000137633.30679.74.
- Frank CS, Sweta BS, Meetu RK, Bekir K, Syngcuk K. Outcome of endodontic surgery: a meta-analysis of the literature - part I: comparison of traditional root end surgery and endodontic microsurgery. *JOE*. 2010;36(11):1757–65.
- Simsek-Kaya G, Saruhan N, Yapia-Yavuz G, Ertas U. A decision analysis for periapical surgery: retrospective study. *J Clin Exp Dent*. 2018;10(9):914–20.
- Baek SH, Plenk H, Kim S. Periapical tissue responses and cementum regeneration with amalgam, Super EBA, and MTA as root-end filling materials. *J Endod*. 2005;31(6):444–9. doi:10.1097/01.don.0000148145.81366.a5.
- Wu MK, de Schwartz F, van der Sluis L, Wesselink PR. The quality of root fillings remaining in mandibular incisors after root-end cavity preparation. *Int Endod J*. 2001;34(8):613–9. doi:10.1046/j.1365-2591.2001.00439.x.
- Kim E, Song JS, Jung IY, Lee SJ, Kim S. Prospective clinical study evaluating endodontic microsurgery outcomes for cases with lesions of endodontic origin compared with cases with lesions of combined periodontal-endodontic origin. *J Endod*. 2008;34(4):546–51. doi:10.1016/j.joen.2008.01.023.

Author biography

Sugandha Sati, Post Graduate 3rd Year Student

Aryama Balodi, Post Graduate Student

Advaita Anand, Post Graduate 3rd Year Student

Ayushi Bangari, Post Graduate 3rd Year Student

Annil Dhingra, HOD

Cite this article: Sati S, Balodi A, Anand A, Bangari A, Dhingra A. Surgical removal of periapical pathology with root end resection. *IP Indian J Conserv Endod* 2023;8(1):58-63.