



Case Report

Management of an Ellis Class IV fracture with open apex using MTA -A case report

Saksham Narainia^{1,*}

¹Dept. of Conservative Dentistry and Endodontics, Private Clinics, Bangalore, Karnataka, India



ARTICLE INFO

Article history:

Received 07-04-2023

Accepted 01-07-2023

Available online 02-09-2023

Keywords:

Mineral Trioxide Aggregate (MTA)

Apexification

Apical barrier

Apical plug

ABSTRACT

Management of immature necrotic permanent teeth imposes a challenge to the clinician as they cannot be managed with routine endodontic treatment. To treat such a tooth; thorough disinfection of the root canal system followed by an apical barrier to obturate the canal is required. This case report demonstrates management of an anterior necrotic tooth with an open apex using Mineral Trioxide Aggregate (MTA) for apexification. The tooth was thoroughly disinfected using antimicrobial irrigants. Calcium hydroxide dressing was given for a period of 1 week followed by an apical plug of 4-5 mm of MTA. A fiber post and composite core were given to finally restore the tooth with a full coverage crown. The positive clinical outcome of the case supports the use of MTA apexification for the management of open apex.

This is an Open Access (OA) journal, and articles are distributed under the terms of the [Creative Commons Attribution-NonCommercial-ShareAlike 4.0 License](https://creativecommons.org/licenses/by-nc-sa/4.0/), which allows others to remix, tweak, and build upon the work non-commercially, as long as appropriate credit is given and the new creations are licensed under the identical terms.

For reprints contact: reprint@ipinnovative.com

1. Introduction

Maxillary anterior teeth are the most common teeth to undergo trauma due to various reasons like accidental fall, impact trauma, sports etc. $2/3^{rd}$ of the root is formed when the tooth erupts. After the eruption, it takes $1^{1/2}$ to $3^{1/2}$ years for root completion of permanent teeth.¹ If due to trauma or caries exposure, the pulp undergoes necrosis, the dentin formation ceases and root growth gets arrested.² Such teeth present with open apex and blunder buss canals and the endodontic management of such teeth becomes a challenge.

The two prerequisites to treat such teeth are proper irrigation and an apical barrier for obturation. The apical barrier technique is known as apexification. Calcium hydroxide was the material of choice in earlier days to induce hard tissue formation at the apex. But there are few drawbacks with calcium hydroxide like it takes up to few months to form a barrier, the dressings have to be changed multiple times and the high chances of re-infection

in between appointments.³

Mineral trioxide aggregate (MTA) on the other side is a bio-compatible material and has shown to cause cementogenesis and osteoid like tissue formation thus helping in apical barrier formation.⁴ MTA has been the choice of material now for apexification procedures as it can be done in a single visit thus ruling out the disadvantages with calcium hydroxide.

The post endodontic management of teeth with poor coronal structure requires extra retention and reinforcement. Fiber posts cemented with an adhesive resin cement provide both reinforcement and esthetics in case of anterior teeth. These adhesive resin systems provide adequate strength to the weak tooth structure to ensure proper functioning of the tooth in future.⁵

In this article, management of an anterior tooth with an open apex that has undergone Ellis class IV fracture is discussed using MTA as an apexification material followed by reinforcement using fiber post and composite core.

* Corresponding author.

E-mail address: drsaksham.endodontist@gmail.com (S. Narainia).

2. Case Report

A 21-year-old female patient reported with the chief complaint of an unesthetic smile. The patient gave history of trauma to the front teeth region 10-11 years back. Clinical examination revealed fractured left central incisor involving enamel, dentin and pulpal space. There was no tenderness on vertical percussion plus no intra oral abnormalities. Intra oral periapical radiograph showed exposed root canal system with an open apex and a peri-apical lesion (Figure 1). Pulp vitality tests were negative for both thermal (cold) and electric pulp testing (Waldent, Inc.). Hence, diagnosis of asymptomatic apical abscess with an immature root apex was established with respect to 21.

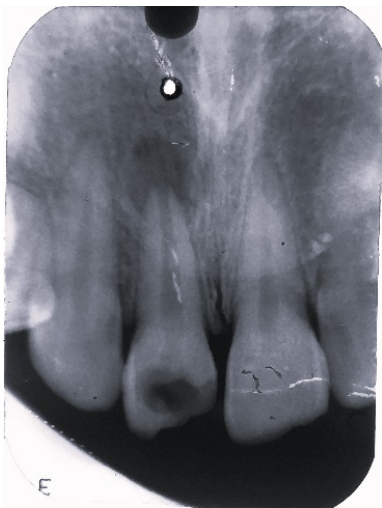

Fig. 1: Pre-operative radiograph showing open apex with a periapical lesion with respect to 21.

Apexification procedure was planned to close the open apex followed by a full coverage crown. The treatment plan was discussed and explained to the patient. After taking patient's informed consent, root canal treatment was initiated. The tooth was isolated with rubber dam (Coltene Whaledent Pvt.Ltd.) As it was a necrotic tooth, local anesthesia was not administered. The canal was already exposed to the oral cavity. Working length determination was done using #60 K file (Mani, Inc. Japan) with radiographic method (Figure 2). After determining working length, cleaning and shaping was done up to #80K file till the root apex with circumferential filing motion. Step back preparation was done up to #120K file. 3% Sodium hypochlorite (Prevest Denpro. Ltd. India) was used as the irrigant in between instrumentation. Once the canal was thoroughly cleaned and dried, Calcium hydroxide (Prime dental products, Pvt.Ltd.) dressing was placed for a period of 7 days (Figure 3).

On second visit, the dressing was removed using Hedstrom files (Mani Inc. Japan) and copious irrigation with 3% Sodium hypochlorite. The canal was then dried using

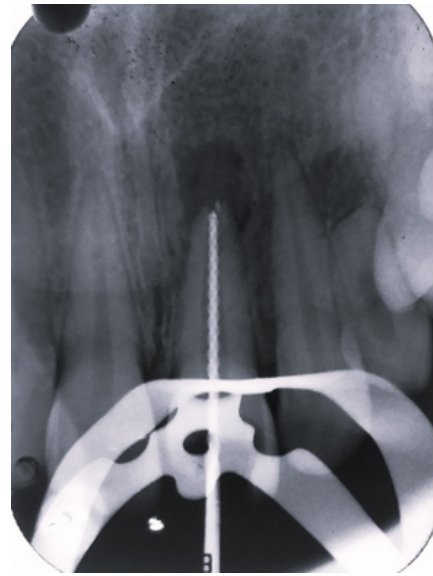


Fig. 2: Working length determination with radiographic method

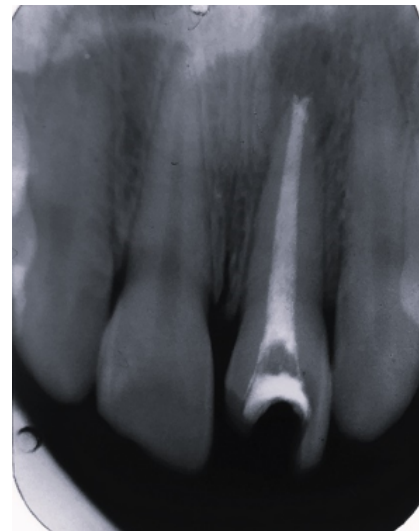


Fig. 3: Calcium hydroxide dressing placed as intracanal medicament.

absorbent paper points (Dentsply Maillefer, Switzerland) and apexification was carried out using ProRoot MTA (Dentsply Maillefer, Switzerland). A correct plugger size was selected with the help of a radiograph to condense the MTA inside the canal. MTA powder and liquid were mixed into the desired consistency and placed inside the canal with the help of a MTA carrier (Waldent, Inc). The selected plugger was used to pack the MTA in the apical 4-5mm of the canal to form the apical barrier (Figure 4). A moist cotton pellet was placed over the MTA followed by an interim restoration using Cavit (3M ESPE). Patient was recalled the next day.

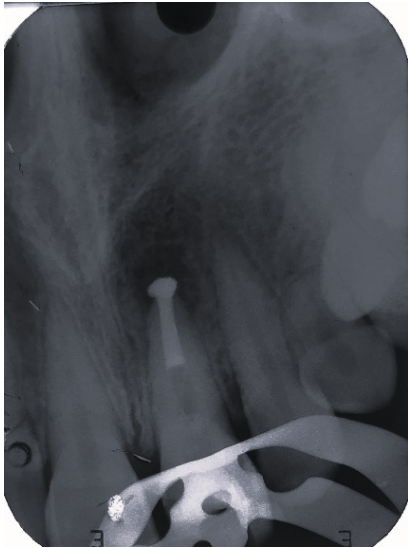

Fig. 4: MTA placed in the apical 4-5mm of the canal to form an apical barrier.

In the third visit, hand files and pluggers were used to confirm the formation of the apical plug. After confirming the closure of the apex, the undermined coronal structure was removed to evaluate the remaining coronal structure. As the remaining coronal tooth structure was poor, it was decided to restore the tooth with a fiber post and a composite core for better strength and retention of the final prosthesis. A Glass Fiber post (RelyX, 3M ESPE) was cemented inside the canal using RelyX U200 (3M ESPE) resin cement (Figure 5). After curing the cement, extra cement was removed and a layer of Universal adhesive (3M ESPE) was applied on to the remaining post and tooth surface. For the core, Bulk fill Composite (3M ESPE) was used (Figure 6). Finally tooth preparation was done for porcelain fused to metal crown as preferred by the patient. Gingival retraction cord (Prime Dental Products Pvt.Ltd.) was placed prior to impression (Figure 7). Impression was made using putty and light body (GC India) impression technique. Shade selection was done using Vita Classic shade guide (VITA Zahnfabrik).

On the final visit, the crown was placed and occlusion was checked. The crown was cemented using luting GIC cement (GC Gold Label, India) (Figure 8) .

3. Discussion

Teeth with open apices and incomplete root formation require a separate treatment plan. To treat such teeth an apical barrier is required to limit the obturating material and avoiding the extrusion into the periapical tissues. Calcium hydroxide has been used for the treatment of nonvital teeth with open apices to form artificial barrier.⁶ But due to the time required for apexification with it which ranges from

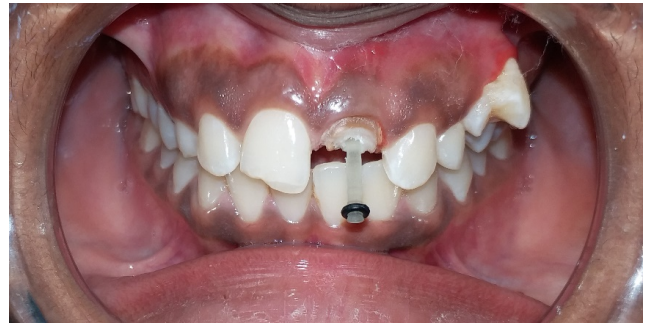

Fig. 5: Glass fiber post was cemented inside the canal using resin cement.

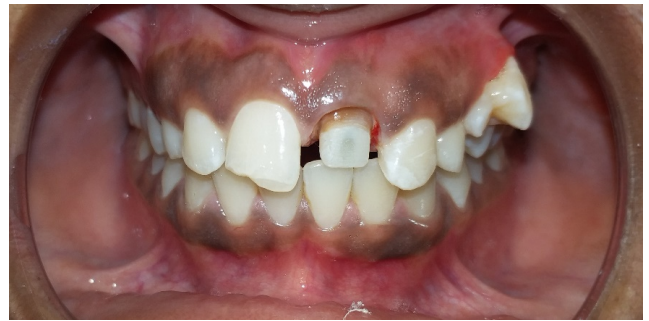

Fig. 6: Core build up was done using Bulk fill Composite.

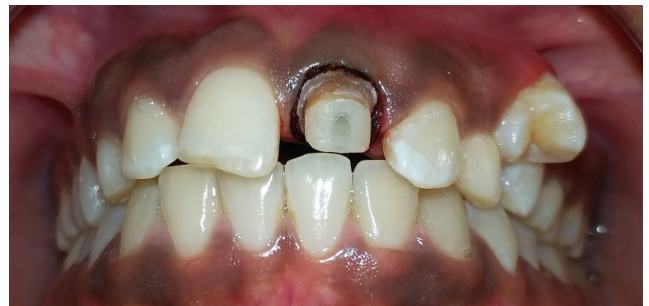

Fig. 7: Gingival retraction cord was placed prior to impression.

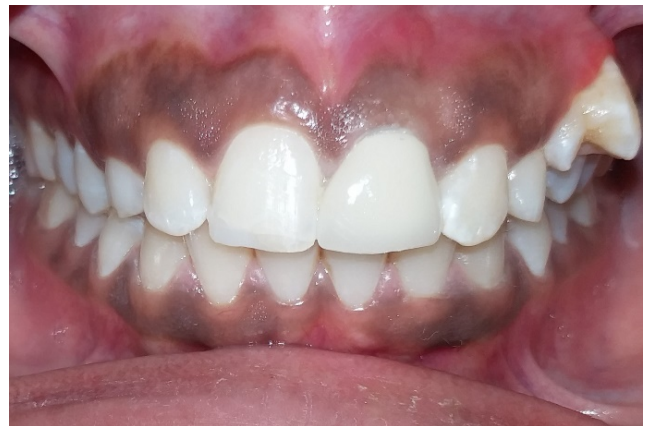

Fig. 8: Final outcome after cementation of Porcelain fused to metal crown.

one year to two years, there are problems like reinfection due to loss of temporary restoration, chances of the tooth to fracture and patient compliance.⁷

The most promising alternative to calcium hydroxide is MTA.⁸ MTA generates a high-alkaline aqueous environment by leaching the calcium and hydroxyl ions, thus forming hydroxyapatite in the presence of phosphate-containing fluids.⁹ The apical plug created with MTA serves as an apical barrier to condense the subsequent root canal filling material, thereby preventing reinfection of the canal system.

Because of its outstanding biocompatibility, ability to set in the presence of blood, and possibility to restore teeth in one to two visits without changing the mechanical properties of dentine, as seen with calcium hydroxide, the first choice of material suitable for single-visit apexification is MTA.¹⁰ In a study done by Simon S et al., apexification treatment with MTA showed a high prevalence of healing and apical closure.¹¹

Reviewing the above factors, single-step apexification was carried out using MTA in this case and the tooth was then restored with a fiber post and crown to re-establish the function and esthetic demands.

4. Conclusion

Calcium hydroxide has been the choice of material when it came to apexification for very long. But with problems like multiple visits, time constraints, increase susceptibility of the tooth to fracture and re-infection, newer materials like MTA should be preferred. Apexification with MTA definitely saves a lot of time and reduces the number of appointments as compared to calcium hydroxide and gives a predictable apical barrier in a single visit. Hence, this case of open apex was managed by using MTA instead of Calcium hydroxide and the result was very satisfactory both for the patient and the doctor.

5. Conflict of Interest

The author declares no relevant conflict of interest.

6. Source of Funding

None.

References

- Grossarthur EL, Nowak J. The Dynamics of Change. In: Pediatric Dentistry (Sixth Edition) Infancy Through Adolescence. Elsevier; 2019. p. 181–99.
- Salgar AR, Chandak MG, Manwar NU. Blunder buss canal: A challenge for endodontist. *Endodontology*. 2011;23:75–84.
- Masmoudi F, Cherni L, Sebai A, Baccouche Z, Maatouk F. The Complications of Apexification with Calcium Hydroxide: Two Case Reports. *Sch J Dent Sci*. 2017;4(8):369–76.
- Komabayashi T, Spångberg LS. Comparative analysis of the particle size and shape of commercially available mineral trioxide aggregates and Portland cement: a study with a flow particle image analyzer. *J Endod*. 2008;34(1):94–8. doi:10.1016/j.joen.2007.10.013.
- Lamichhane A, Xu C, Zhang FQ. Dental fiber-post resin base material: a review. *J Adv Prosthodont*. 2014;6(1):60–5. doi:10.4047/jap.2014.6.1.60.
- Fidel RA, Carvalho RG, Varela CH, Letra A, Fidel SR. Complicated crown fracture: A case report. *Braz Dent J*. 2006;17(1):83–6. doi:10.1590/s0103-64402006000100019.
- Ajwani P, Saini N. Non-surgical management of a mutilated maxillary central incisor with open apex and large periapical lesion. *Indian J Dent Res*. 2011;22(3):475–7. doi:10.4103/0970-9290.87074.
- Witherspoon DE, Ham K. One-visit apexification: Technique for inducing root-end barrier formation in apical closures. *Pract Proced Aesthet Dent*. 2001;13(6):455–60.
- Darmawi A, Dennis D, Abidin T. Mta as an apical plug in nonvital tooth with open apex; A case report. *JB Dent*. 2018;5(2):87–95. doi:10.33854/jbd.v5i2.155.
- Shabahang S, Torabinejad M. Treatment of teeth with open apices using mineral trioxide aggregate. *Pract Periodontics Aesthet Dent*. 2000;12(3):315–20.
- Simon S, Rilliard F, Berald A, Machtou P. The use of mineral trioxide aggregate in one-visit apexification treatment: A prospective study. *Int Endod J*. 2007;40(3):186–97. doi:10.1111/j.1365-2591.2007.01214.x.

Author biography

Saksham Narainia, Endodontic Consultant

Cite this article: Narainia S. Management of an Ellis Class IV fracture with open apex using MTA -A case report. *IP Indian J Conserv Endod* 2023;8(3):167-170.