

Content available at: <https://www.ipinnovative.com/open-access-journals>

IP Indian Journal of Conservative and Endodontics

Journal homepage: <https://www.ijce.in/>

## Case Report

# Management of large furcal defect -1.5 year follow up: A case report

Deepanshi<sup>1</sup>, Prachi<sup>1\*</sup>, Ashtha Arya<sup>1</sup>, Mandeep S. Grewal<sup>1</sup>, Gaurav Thapak<sup>1</sup>

<sup>1</sup>Dept. of Conservative Dentistry and Endodontics, SGT Dental College, Hospital and Research Institute, SGT University, Gurugram, Haryana, India



### ARTICLE INFO

#### Article history:

Received 14-07-2023

Accepted 12-08-2023

Available online 02-09-2023

#### Keywords:

perforation

furcation

mta

### ABSTRACT

In about 2 -12 % perforation may occur while doing a root canal or post placement. Perforation can be pathological or mechanical. Treatment outcome will depend on several factors size, position, time lapse, sealing ability of the material used. In this case report patient came with furcation defect which was managed with MTA and patient was kept on follow for 1.5 year.

This is an Open Access (OA) journal, and articles are distributed under the terms of the [Creative Commons Attribution-NonCommercial-ShareAlike 4.0 License](https://creativecommons.org/licenses/by-nc-sa/4.0/), which allows others to remix, tweak, and build upon the work non-commercially, as long as appropriate credit is given and the new creations are licensed under the identical terms.

For reprints contact: [reprint@ipinnovative.com](mailto:reprint@ipinnovative.com)

## 1. Introduction

Perforation in the continuity of the tooth structure can lead to direct contact of the canal system with external tooth surface. Perforation can be pathological and mechanical.

Pathological could be because of Resorption, Dental caries.

Mechanical is because of iatrogenic reason i.e. while doing root canal treatment or post space preparation.<sup>1,2</sup>

The occurrence of through connection between the canal and periodontium hamper the outcome of root canal treatment. In case of furcation involvement gingival over-growth may be present, which further reduces the outcome of the treatment.

Following factors affect the outcome of treatment

1. Position: defect apical to crestal bone have better prognosis
2. Size: smaller one heals better
3. Time Lapse : treated earlier heals better
4. Material used: sealing ability
5. Accessibility to canals
6. Isolation<sup>3</sup>

\* Corresponding author.

E-mail address: [prachipunia1410@gmail.com](mailto:prachipunia1410@gmail.com) (Prachi).

In about 2 -12 % perforation may occur while doing a root canal or post placement.<sup>4-8</sup> This case report present 1.5 year followed case of furcation repair where patient came to the department 3 weeks later defect occurred.

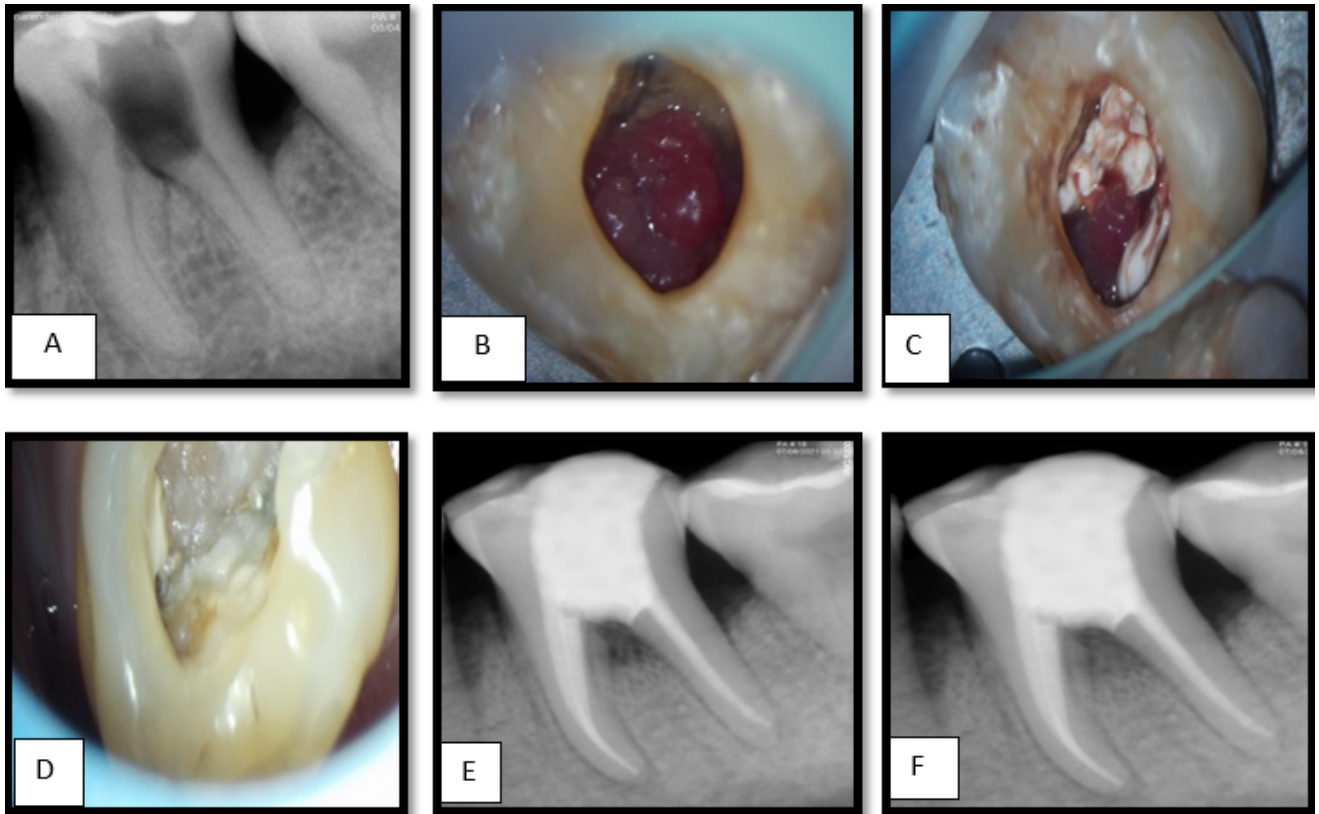
## 2. Case Report

A 45 years male came to the department for second opinion regarding his right mandibular tooth which was advised for extraction by his dentist. Patient was having problem while eating due to food lodgment and does not have any medical history.

Patient was advised to get an x-ray done for the same tooth (Figure 1A). IOPA revealed that root canal was initiated in that tooth and while doing access opening practitioner had gone little apically which has led to the breach in the floor of the pulp chamber. Bone loss was also evident in that area.

The condition and prognosis was explained to the patient still patient want to save his tooth. The prognosis was doubtful but after taking consent from the patient the treatment was initiated.

All the procedure were carried out under magnification and rubber dam isolation.



**Fig. 1:** **A:** Pre op radiograph; **B:** Microscopic view showing growth of granulation tissue; **c:** Blocking the canal orifice; **D:** Sealed defect, **E:** Post op radiograph; **F:** Follow up xray after 1.5 year.

The access cavity was refined granulation tissue (\$B) can be seen, all the canals were located and working length was taken. Bleeding was arrested with 1% sodium hypochlorite.

Canals are blocked with teflon tape (Figure 1C) and furcal defect was sealed with MTA (Figure 1D). For proper setting of MTA a moist cotton was kept over the MTA (angelus).

Followed by this the cavity is filled with temporary restoration. Patient was recalled after 3days. Canals were properly cleaned and shaped following proper irrigation with sodium hypochlorite and EDTA. Canals were obturated (Figure 1E). Patient was recalled after 7 days and was asked for the symptoms. As he was not having any problem so composite restoration was done and was recalled after 1 month and then after every 6 month till 1.5 year (Figure 1F).

### 3. Discussion

The case presented in this article was 3 weeks old large perforated lesion in the pulpal floor of right mandibular molar with evident bone loss. This case was successfully managed with MTA.

As this case was left opened for 3 weeks from the pulpal floor chronic inflammation lead to formation of granulation tissue growth because of which there was a profuse bleeding

in the chamber which was arrested by the use of 1% sodium hypochlorite.<sup>9</sup>

As there was large defect and was kept open for longer time a material with excellent sealing ability was required to seal the defect very well so MTA was selected.

Several studies has proposed the success of perforation repair with MTA as it is biocompatible does not induce any inflammation, not soluble, seals the chamber well , capable of induction of cementum, bone, PDL formation<sup>10-15</sup>

In case of large extensive furcation defect which is directly accessible internal matrix technique is suggestive in which matrix could be hydroxyapatite calcium sulphate, decalcified freezed dried bone or MTA with resorbable collagen can be used. But as in case of furcal defect calcium hydroxide can cause formation of pocket and all the above mention internal marix material contain calcium hydroxide so in this case we used MTA as internal matix as well as repair material in them.<sup>15</sup>

As for the successful outcome of perforation repair the defect should be small, apically, should not be contaminated treated and should be sealed immediately but in our case there was a sufficiently large defect with evident bone loss and was left un treated since 3 weeks so all these factors were indicating guarded prognosis.<sup>4-8,16</sup>

Patient want to save his tooth so with informed consent from the patient we started the treatment under proper isolation and magnification and the patient was successfully treated patient was recalled and assessed clinically and radiographically till 1.5 year.

#### 4. Conclusion

In case of perforation defect if the defect is sealed under aseptic condition with a good biocompatible material, proper root canal procedure with proper cleaning and shaping of the canal followed by obturation and proper coronal restoration then it may result in a successful long term outcome and evidence of healing will be reflected by the x-ray.

#### 5. Conflict of Interest

The author declares no relevant conflict of interest.

#### 6. Source of Funding

None.

#### References


- Nicholls E. Treatment of traumatic perforations of the pulp cavity. *Oral Surg Oral Med Oral Pathol.* 1962;15:603–12. doi:10.1016/0030-4220(62)90180-9.
- Bryan EB, Woollard G, Mitchell WC. Nonsurgical repair of furcal perforations: a literature review. *Gen Dent.* 1999;47(3):274–80.
- Oswald RJ. Procedural accidents and their repair. *Dent Clin North Am.* 1979;23(4):593–616.
- Kvinnslund I, Oswald RJ, Halse A, Gronningsaeter AG. A clinical and roentgenological study of 55 cases of root perforation. *Int Endod J.* 1989;22(2):75–84. doi:10.1111/j.1365-2591.1989.tb00509.x.
- Ingle JL. A standardized endodontic technique utilizing newly designed instruments and filling materials. *Oral Surg Oral Med Oral Pathol.* 1961;14:83–91. doi:10.1016/0030-4220(61)90477-7.
- Seltzer S, Bender IB, Smith J, Freedman I, Nazimov H. Endodontic failures-an analysis based on clinical, roentgenographic, and histologic findings. *Oral Surg Oral Med Oral Pathol.* 1967;23(4):500–30. doi:10.1016/0030-4220(67)90547-6.
- Kerekes K, Tronstad L. Long-term results of endodontic treatment performed with a standardized technique. *J Endod.* 1979;5(3):83–90. doi:10.1016/S0099-2399(79)80154-5.
- Sinai IH, Romea DJ, Glassman G, Morse DR, Fantasia J, Furst ML, et al. An evaluation of tricalcium phosphate as a treatment for endodontic perforations. *J Endod.* 1989;15(9):399–403. doi:10.1016/s0099-2399(89)80171-2.
- Hartwell GR, England MC. Healing of furcation perforation in primate teeth after repair with decalcified freeze dried bone: a longitudinal study. *J Endod.* 1993;19(7):357–61. doi:10.1016/S0099-2399(06)81363-4.
- Torabinejad M, Chivian N. Clinical applications of mineral trioxide aggregate. *J Endod.* 1999;25(3):197–205. doi:10.1016/S0099-2399(99)80142-3.
- Roberts HW, Toth JM, Berzins DW, Charlton DG. Mineral trioxide aggregate material use in endodontic treatment: a review of the literature. *Dent Mater.* 2008;24(2):149–64. doi:10.1016/j.dental.2007.04.007.
- Torabinejad M, Hong CU, Lee SJ, Monsef M, Ford TP. Investigation of mineral trioxide aggregate for root-end filling in dogs. *J Endod.* 1995;21(12):603–8. doi:10.1016/S0099-2399(06)81112-X.
- Torabinejad M, Ford TP, Mckendry DJ, Abedi HR, Miller DA, Kariyawasam SP, et al. Histologic assessment of mineral trioxide aggregate as a root-end filling in monkeys. *J Endod.* 1997;23(4):225–8. doi:10.1016/S0099-2399(97)80051-9.
- Ford TR, Torabinejad M, Mckendry DJ, Hong CU, Kariyawasam SP. Use of mineral trioxide aggregate for repair of furcal perforations. *Oral Surg, Oral Med, Oral Pathol, Oral Radiol Endodontol.* 1995;79(6):756–63.
- Abedi HR, Ingle JI. Mineral trioxide aggregate: A review of a new cement. *J Calif Dent Assoc.* 1995;23(12):36–9.
- Aadf.

#### Author biography

**Deepanshi**, Post Graduate Student

**Prachi**, Post Graduate Student

**Ashtha Arya**, Professor  <https://orcid.org/0000-0003-4598-6910>

**Mandeep S. Grewal**, Professor and HOD  <https://orcid.org/0000-0001-6952-0299>

**Gaurav Thapak**, Reader  <https://orcid.org/0000-0003-4988-6917>

**Cite this article:** Deepanshi, Prachi, Arya A, Grewal MS, Thapak G. Management of large furcal defect -1.5 year follow up: A case report. *IP Indian J Conserv Endod* 2023;8(3):171-173.