

Content available at: <https://www.ipinnovative.com/open-access-journals>

IP Indian Journal of Conservative and Endodontics

Journal homepage: <https://www.ijce.in/>

## Case Series

# A new revolution in esthetic restorations using smart chromatic technology: A case series

Arya Navnath Sinai Khandeparkar <sup>1,\*</sup>, Ida de Noronha de Ataide <sup>1</sup>,  
Marina Fernandes <sup>1</sup>

<sup>1</sup>Dept. Conservative Dentistry and Endodontics, Goa Dental College and Hospital, Bambolim, Goa, India



## ARTICLE INFO

### Article history:

Received 17-05-2023

Accepted 05-07-2023

Available online 02-09-2023

### Keywords:

Fractured teeth

Midline diastema

Universal composite

## ABSTRACT

Color-matching composite to natural tooth color is challenging due to inherent variations in tooth color. Manufacturers are aiming at providing materials with blending effect. A novel single-shade resin restorative composite (Omnichroma (OM)) has been developed by Tokuyama with 260 nm spherical fillers and a similar appearance to the surrounding tooth structure using smart chromatic technology. This article describes cases with fluorosis, anterior class II fractures, and midline diastema, where OM was used with a standard universal procedure. It was cured in 2mm increments and was used with Tokuyama universal bond. OM blocker is a supplementary material that was used in conjunction with OM as a lingual layer to prevent shade matching interference in these cases. All the restorations were polished using polishing cups and discs. OM with increased color matching may be helpful to simplify anterior restorations, minimizing clinical errors.

This is an Open Access (OA) journal, and articles are distributed under the terms of the [Creative Commons Attribution-NonCommercial-ShareAlike 4.0 License](https://creativecommons.org/licenses/by-nc-sa/4.0/), which allows others to remix, tweak, and build upon the work non-commercially, as long as appropriate credit is given and the new creations are licensed under the identical terms.

For reprints contact: [reprint@ipinnovative.com](mailto:reprint@ipinnovative.com)

## 1. Introduction

The world of restorative and esthetic dentistry evolves at a rapid rate when it comes to newer and better innovations in order to meet the ever-increasing demand of a more natural and life-like appearance of dentition.<sup>1</sup> Resin composite has become the primary restorative material in modern dentistry due to advancements in adhesive dentistry and the increasing aesthetic expectations of patients.<sup>2</sup> The technique of layering different shades allows conventional resin composites to closely replicate the appearance of natural teeth. However, the stratification technique typically demands a high level of restorative expertise and a significant amount of chair-side time.<sup>3</sup>

In contrast, clinicians have shown increased interest in the use of recently introduced universal-shade resin

composites. These innovative materials are designed to match nearly all shades, simplifying the restorative procedure and making it more accessible to a wider range of practitioners.<sup>4</sup> Omnichroma (OM) (Tokuyama Dental, Japan) has recently gained considerable popularity as a first shade matching composite. Its uniqueness lies in its utilization of "smart chromatic technology," allowing it to accurately replicate the structural color of its environment through careful manipulation of filler particle size.<sup>5</sup>

The shade variations in conventional resin composites are mainly influenced by the inclusion of pigments and dyes within the resin matrix, which is referred to as "chemical coloration." Additionally, the resin composite's "blending effect" (BE) plays a significant role in achieving a harmonious shade match. The BE refers to the resin composite's ability to reflect and assimilate the color of the adjacent tooth structure, thereby enhancing its aesthetic appearance.<sup>6</sup> In contrast to chemical color, universal composites employ structural color for their optical

\* Corresponding author.

E-mail address: [aryakhandeparkar@gmail.com](mailto:aryakhandeparkar@gmail.com) (A. N. S. Khandeparkar).

properties. The scattering and diffusion of light occurs when it passes through the resin composite, interacting with the filler particles on its surface. This interplay results in light transmission taking two forms: direct transmission in a straight line and diffusion.<sup>7</sup> Therefore, evaluating how different filler morphologies affect light transmission is crucial in predicting successful shade matching. This innovative approach, known as "structural color," utilizes the resin composite's ability to absorb and emit light, contributing to the advancement of shade matching techniques.<sup>8</sup>

OM primarily utilizing structural color, holds promising advantages such as minimal shade alteration over time due to reduced photochemical degradation and decreased color distortion. This is attributed to the arrangement of filler particles aligning with visible light wavelengths.<sup>9</sup> If these universal products prove to be effective, regardless of the shade matching technology employed by manufacturers, they could significantly streamline clinical shade matching procedures and decrease chair-side time. The objective of this case series was to assess the shade-matching ability of a single-shade universal composite in various cases.

## 2. Case History

### 2.1. Case 1

A 28-year-old male presented to the department of Conservative Dentistry and Endodontics with the primary concern of brownish-white stains present on all of his teeth. The patient was a resident of Tumakuru district in Karnataka, which is known for its high fluoride levels and gave history of consuming bore well water during his childhood. The patient also mentioned that his siblings had experienced similar staining on their teeth. There were no significant medical conditions reported by the patient. Based on the examination and history, a diagnosis of moderate fluorosis was established, with a Deans Fluorosis Index score of 4.

After conducting a thorough clinical and radiographic examination and taking preoperative photographs, upper and lower alginate impressions were obtained to create diagnostic models. Subsequently, the patient was presented with various treatment options, including ceramic or composite veneers, and provided with a comprehensive overview of the advantages and disadvantages associated with each choice. Following the detailed explanation, the patient willingly opted for smile enhancement using composite veneers. The treatment plan involved applying composite veneers to both the upper and lower teeth, spanning from the right first molar to the left first molar, thereby achieving the desired aesthetic outcome.

### 2.2. Tooth preparation

The enamel of all the teeth was prepared using a flat-end tapered diamond bur (Mani Inc., Tochigi Ken, Japan) with a facial reduction depth of 0.5–0.75 mm. A chamfer finish line was maintained at the level of the gingival margin, while the proximal margin extended into the facial and gingival embrasures. To prepare the enamel for bonding, a 37% phosphoric acid gel (N-Etch, Ivoclar Vivadent, Liechtenstein) was applied and left for 15 seconds. It was then rinsed with a water spray for 10 seconds, followed by careful air drying to ensure the dentin remained moist.

Next, a bonding agent (Palfique Universal Bond, Tokuyama Dental, Japan) was applied for 20 seconds and gently air-thinned for 5 seconds. The bonding agent was then light-cured for 10 seconds using a light curing device (3M ESPE Elipar TM 2500 curing light, Saint Paul, Minnesota, United States). Subsequently, OM (Tokuyama Dental, Japan) was applied to the tooth surfaces in 2mm increments. To achieve a smooth and polished appearance, the restorations were carefully finished and polished using appropriate polishing discs. (Figure 1)

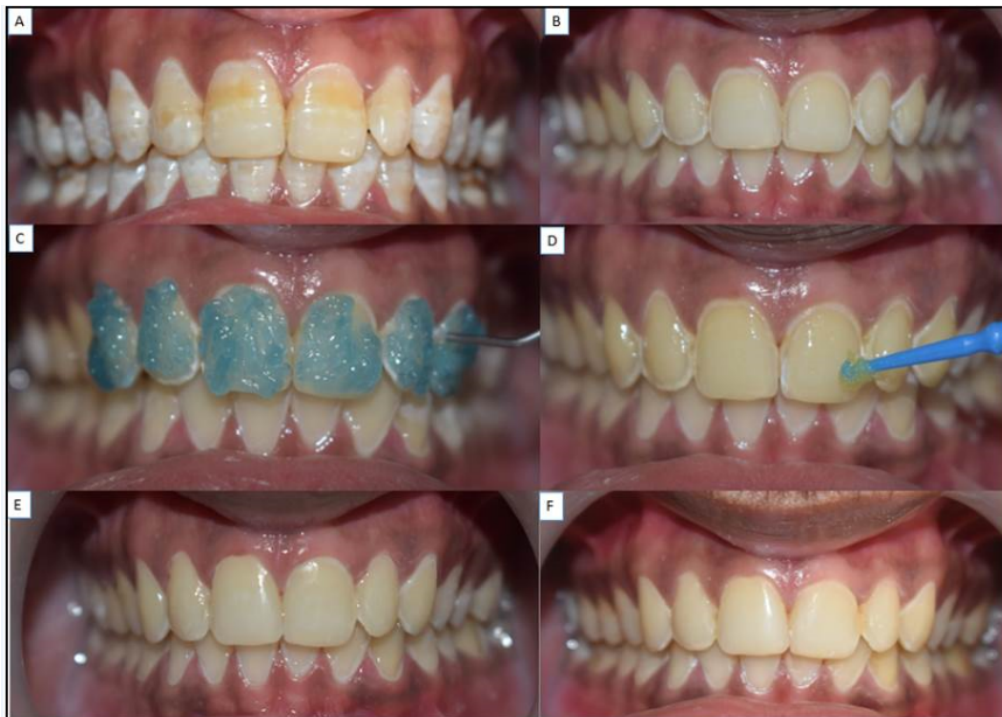### 2.3. Case 2

A 21-year-old male patient presented to the department of Conservative Dentistry and Endodontics due to a fractured upper right front tooth. The patient did not experience any pain or discomfort. Upon intraoral examination, an Ellis class 2 fracture was identified, accompanied by a midline diastema. Diagnostic casts were created, and a mockup was performed to assess the desired outcome. Subsequently, a silicone template was fabricated based on the mockup.

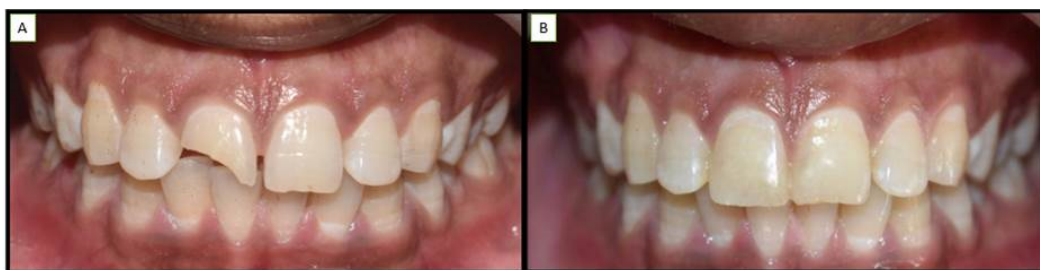For the restorative procedure the fractured surface was beveled, followed by etching and bonding. To ensure optimal shade matching, a 0.5 mm layer of OM blocker (Tokuyama Dental, Japan) was applied to prevent any shade matching interference due to lack of surrounding tooth structure. Next, OM was carefully applied, and the surfaces were finished and polished, resulting in a natural-looking and harmonious appearance. (Figure 2)

### 2.4. Case 3

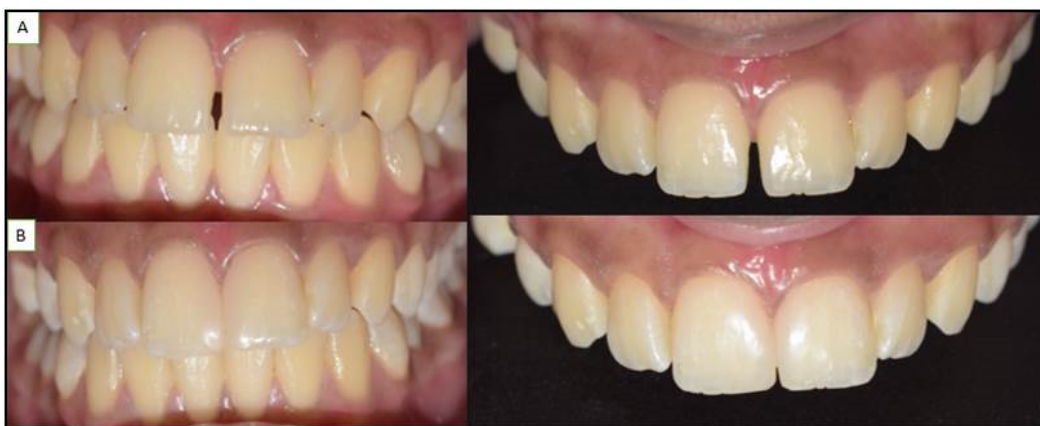A 38-year-old female patient reported to the department of Conservative Dentistry and Endodontics with chief complaint of spacing in between her upper front teeth. The patient's medical history was non-contributory and on intraoral examination, a midline diastema of 1mm was revealed in the maxillary arch. Diagnostic models were prepared on which a mockup was done and was shown to the patient. Slight roughening of mesial interproximal surfaces of both central incisors was done in order increase micromechanical retention followed by direct composite restorations using OM. (Figure 3)



**Fig. 1:** **A:** Intraoral pre-operative view showing brownish white stains on maxillary and mandibular teeth; **B:** Teeth preparation done on maxillary anterior teeth; **C:** Application of 37% phosphoric acid; **D:** application of bonding agent **E.** Immediate postoperative view; **F:** 6 months follow up.



**Fig. 2:** **A:** Intraoral pre-operative view of Ellis Class II fracture; **B:** Intraoral postoperative view.



**Fig. 3:** **A:** Intraoral pre-operative view of midline diastema; **B:** Intraoral postoperative view.

### 3. Discussion

Achieving accurate color matching is crucial for the success of resin composite esthetic restorations. Therefore, there is an ongoing quest to discover materials that possess both high esthetic capabilities and ease of use.<sup>10</sup>

The direct composite restoration technique offers several advantages, including minimal invasiveness, cost-effectiveness, and successful repair of tooth fractures with excellent long-term results in carefully selected cases. However, the process of shade selection can be challenging and time-consuming.<sup>11</sup> As the demand for improved esthetics continues to rise, advancements in dental material technology have led to the development of single shade composites such as OM. This innovative composite simplifies the shade selection process, providing a solution that meets the increasing need for better esthetic outcomes.<sup>12</sup>

OM, as per the manufacturer's claims, is a unique resin composite that is designed to be a one-shade system without the use of traditional pigments. Instead, its color properties are derived from the specific characteristics and composition of the material itself. The composition of OM includes uniform-sized supra-nano spherical fillers made of silicon dioxide (SiO<sub>2</sub>) and zirconium dioxide (ZrO<sub>2</sub>) with a particle size of 260 nm.<sup>13</sup>

One interesting feature of OM is that its translucency increases after the polymerization process. This is due to the difference in refractive index between the monomers before and after polymerization. By utilizing this approach, OM has been engineered to respond to light waves at a specific frequency, reflecting a particular wavelength within the tooth color space. As a result, it can match a wide range of colors using a single shade.<sup>14</sup>

The broad color-matching ability of OM eliminates the need for a shade-matching procedure and reduces composite inventory, allowing clinicians to minimize chair time, the wastage of unused composite shades, and reduce reliance on shade-matching procedures. Other potential benefits include less change in the shade over time due to reduced photochemical degradation and less color distortion since their filler particle arrangement corresponds to the wavelengths of the visible light.<sup>15</sup>

### 4. Conclusion

Universal single shade composites like Omnichroma can prove to be highly beneficial in simplifying anterior restorations and reducing clinical errors. These composites offer increased color matching capabilities, allowing for a more streamlined and efficient workflow. With their excellent polishability, strength, and ease of handling, they enable the creation of beautiful and reliable restorations, irrespective of the shade or class of the case. The versatility and performance of these composites contribute to improved outcomes and patient satisfaction in anterior

dental restorations.

### 5. Conflicts of Interests

The author has no financial interests or conflicts of interests.


### 6. Source of Funding


None.


### References

- Sharma N, Samant PS. Omnichroma : The See-It -To-Believe -It Technology. *EAS J Dent Oral Med.* 2021;3(3):100-4.
- El-Rashidy AA, Abdelraouf RM, Habib NA. Effect of two artificial aging protocols on color and gloss of single-shade versus multi-shade resin composites. *BMC Oral Health.* 2022;22(1):1-12.
- Miotti LL, Santos IS, Nicoloso GF. The use of resin composite layering technique to mask discolored background: A CIELAB/CIEDE2000 analysis. *Oper Dent.* 2017;42(2):165-74.
- Abdelraouf RM, Habib NA. Color-Matching and Blending-Effect of Universal Shade Bulk-Fill-Resin-Composite in Resin-Composite-Models and Natural Teeth. *Biomed Res Int.* 2016;p. 4183432. doi:10.1155/2016/4183432.
- Chen F, Toida Y, Islam R. Evaluation of shade matching of a novel supra-nano filled esthetic resin composite employing structural color using simplified simulated clinical cavities. *J Esthet Restor Dent.* 2021;33(6):874-83.
- Paravina RD, Westland S, Kimura M. Color interaction of dental materials: Blending effect of layered composites. *Dent Mater J.* 2006;22(10):903-8.
- Chu SJ, Trushkowsky RD, Paravina RD. Dental color matching instruments and systems. Review of clinical and research aspects. *J Dent.* 2010;38(2):2-16.
- Sanchez NP, Powers JM, and RDP. Instrumental and visual evaluation of the color adjustment potential of resin composites. *J Esthet Restor Dent.* 2019;31(5):465-70.
- Fu Y, Tippets CA, Donev EU. Structural colors: from natural to artificial systems. *Wiley Interdiscip Rev Nanomedicine Nanobiotechnol.* 2016;8(5):758-75.
- Furusawa K, Kobayashi S, Yamashita A. Effect of filler load on structural coloration and color adjustment potential of resin composites. *Dent Mater J.* 2023;42(3):343-50.
- Ferracane JL. Resin composite - State of the art. *Dent Mater J.* 2011;27(1):29-38.
- De Abreu J, Sampaio CS, , and EBJ. Analysis of the color matching of universal resin composites in anterior restorations. *J Esthet Restor Dent.* 2021;33(2):269-76.
- Durand LB, Ruiz-López J, Perez BG. Color, lightness, chroma, hue, and translucency adjustment potential of resin composites using CIEDE2000 color difference formula. *J Esthet Restor Dent.* 2021;33(6):836-43.
- Paravina RD, Majkic G, Imai FH. Optimization of tooth color and shade guide design: Clinical research. *J Prosthodont.* 2007;16(4):269-76.
- Eliezer R, Devendra C, Ravi N. Omnichroma: One Composite to Rule Them All. *Int J Med Sci.* 2020;7(6):6-8.

### Author biography

Arya Navnath Sinai Khandeparkar, Post Graduate Student  
 <https://orcid.org/0000-0003-0256-9826>

Ida de Noronha de Ataide, Professor and HOD  <https://orcid.org/0000-0002-6174-0542>

**Marina Fernandes**, Professor  <https://orcid.org/0000-0002-7641-2322>

**Cite this article:** Khandeparkar ANS, Ataide IN, Fernandes M. A new revolution in esthetic restorations using smart chromatic technology: A case series. *IP Indian J Conserv Endod* 2023;8(3):177-181.