

Content available at: <https://www.ipinnovative.com/open-access-journals>

IP Indian Journal of Conservative and Endodontics

Journal homepage: <https://www.ijce.in/>

Review Article

Dental implications of COVID-19 - An insight

Ashwath V¹, Lakshmi Kumari K^{2*}, Gowrishankar S³¹Director, Panchatheertham Health Care Solutions (OPC) Pvt Ltd., Chennai, Tamil Nadu, India²Dept. of Pedodontics and Preventive Dentistry, Sri Venkateshwara Dental College and Hospital, Thalambur, Chennai, Tamil Nadu, India³Dept. of Oral Medicine and Radiology, Radiology Sri Venkateshwara Dental College and Hospital, Thalambur, Chennai, Tamil Nadu, India

ARTICLE INFO

Article history:

Received 12-11-2023

Accepted 07-12-2023

Available online 16-12-2023

Keywords:

COVID-19

Corona virus

Immune suppression

Oral manifestation

Diabetes mellitus

Oral hygiene

Dental practice

ABSTRACT

COVID-19 is a pandemic viral disease caused by Severe Acute Respiratory Syndrome corona virus 2 (SARS-CoV-2). This pandemic has created a massive impact globally and is indeed a challenge to the mass healthcare management. Despite continuous, untiring efforts of the World Health Organisation (WHO) and the Health departments of various countries to curb this zoonotic disease, the propensity of the virus to spread through droplets, replicate and mutate has raised huge public health concerns. Oral cavity is an index of body's health. Oral manifestations such as ageusia, angular cheilitis, periodontal diseases, ulcers and fungal infections have been reported commonly in patients with COVID-19. These oral manifestations are valuable diagnostic criteria for the disease. Periodontal inflammation has been proved to increase the severity of the disease. Also, Periodontitis can present secondary to COVID-19 due to compromised immune system in this viral disease. Proper and adequate oral hygiene, appropriate use of corticosteroids and maintenance of glycemic control can reduce oral infections in COVID-19. Considering the increased risk of contracting the virus due to their proximity to the patients in the operating environment, oral health care providers must be aware of safety protocols and should strictly adhere to the recommendations by the regulatory authorities. This not only ensures higher safety, but also prevents the dental office from being a source of transmission for the virus. This review provides an overview on COVID-19 with an insight on its oral manifestations and a special emphasis on the safety protocols to be followed by dentists.

This is an Open Access (OA) journal, and articles are distributed under the terms of the [Creative Commons Attribution-NonCommercial-ShareAlike 4.0 License](https://creativecommons.org/licenses/by-nc-sa/4.0/), which allows others to remix, tweak, and build upon the work non-commercially, as long as appropriate credit is given and the new creations are licensed under the identical terms.

For reprints contact: reprint@ipinnovative.com

1. Introduction

The novel human corona virus disease COVID-19, a pandemic disease caused by Severe Acute Respiratory Syndrome corona virus 2 (SARS-CoV-2) is a severe respiratory disease associated with high mortality and morbidity. This disease from Wuhan of China is exponentially spreading all over the world exhibiting severe impact on routine lifestyle, economy and most importantly health. This is the fifth documented pandemic subsequent

to 1918 Spanish flu (H1N1), 1957 Asian flu (H2N2), 1968 Hong Kong flu (H3N2) and 2009 Pandemic flu (H1N1). Its origin has been traced to a province called Hubei in the Wuhan city of China.¹ In India, the first case of this COVID-19 was reported from Kerala among 3 medical students who have returned from Wuhan on January 30, 2020.² The novel Corona virus outbreak was declared as a global pandemic by WHO on March 11, 2020.

Oral cavity is considered a mirror of systemic health. Multiple oral manifestations have been and are being reported in patients with COVID-19. Few manifestations appear secondary to the COVID-19 disease and some

* Corresponding author.

E-mail address: sudharshini1989@gmail.com (L. Kumari K).

as a result of the treatment regimen used to contain the disease. Common oral manifestations include ageusia, anosmia, hypo salivation, ulcers, herpes ulcers, fungal infections like mucormycosis, submandibular salivary gland enlargement, cervical lymph node enlargement etc. This article is a comprehensive review on COVID-19 disease, its oral manifestations and the standard operating protocols to be followed by dentists.³

1.1. The spiked virus

The novel corona virus resembles a crown with multiple spikes on it and so it is named as ‘Corona’ which is derived from a Latin word meaning ‘crown’. The spiked structure of the virus can be appreciated in an electron microscope.⁴ It is an enveloped virus that has a single stranded RNA. It belongs to the genera- beta corona virus and is 26-32 kilobase in size. This virus is also of zoonotic origin similar to other corona virus. The China horse shoe type of bats is believed to be the zoonotic species of origin for SARS-CoV-2.⁵ The virus enters the host cell either by endosomal membrane fusion or plasma membrane fusion. There is a glycoprotein in the viral called as the S protein. This protein helps in binding and facilitate the entry of these organism into the host cell.⁶ The S protein binds to receptor ACE2 (angiotensin converting enzyme 2) of the host cell. This binding is primed by TMPRSS2 (transmembrane protease serine 2).⁷

The respiratory droplet from the cough and sneeze of the infected patients is a transmitting medium among humans. This transmission is higher when the exposure area to respiratory droplet is within 6 feet distance. The transmission can also be from the hands touching the settled droplets from the sneeze or cough and when the same hands are then taken to mouth and nose.⁸ Transmission of infection via faecal-oral route transmission have also been evident in recent studies.⁹ Patients are infectious until symptoms subside. Even after the recovery, patients can be contagious. These viruses can even stay as droplets on surfaces and survive, if the surrounding atmosphere favours them. But this can be eliminated with disinfectants such as sodium hypochlorite.¹⁰ Although multiple ways of transmission has been documented, the most significant and appropriate way of transmission is by directly getting exposed to the infected individuals.

2. Clinical Features of COVID-19

The clinical features this COVID-19 varies among each and every individual. Manifestations range from asymptomatic to severe acute respiratory distress, at times leading to death. Symptoms include fever, sore throat, cough, myalgia, fatigue, head ache and in few cases difficulty in breathing. In a study by Chen et al,¹¹ fever was a manifesting sign in 82 of 99 COVID-19 positive cases.

Cough was present in almost 81 of 99 cases, followed by shortness of breath in 31 cases. More than one symptom as manifestation was reported in 90% of cases. Fever, cough and shortness of breath were seen as a triad in almost 15% of cases. Inflammatory cytokines including IL2(interleukin-2), IL7(interleukin-7), IL10(interleukin-10), G-CSF (granulocyte colony stimulating factor), IP10(inducible protein 10), MCP1(monocyte chemo attractant protein 1), MIP1A (macrophage inflammatory protein 1), and TNF α (tumor necrosis factor α)were seen increased. Acute Respiratory Distress Syndrome was seen in 17% of cases, Acute renal injury in 3% and Acute respiratory injury in 8% of cases. Septic shock was seen in 4% of cases and Ventilator-associated pneumonia in 1% of cases.

Chest radiograph and Computed Tomography are gold standard diagnostic technique in evaluating the stage of disease as they detect the condition of lungs affected with pneumonia. A study by Attaway et al, revealed that about 15-30% of the COVID-19 patients develop acute respiratory distress syndrome. Diffuse alveolar damage with high thrombus burden in pulmonary capillary is seen in autopsy of patients who succumb to COVID-19.¹² Initially the disease was seen affecting and causing death in elderly and immuno-compromised patients, but gradually cases were among younger patients as well. A severe pneumonia with multiple organ dysfunction was observed in a case first reported in China.¹³ The first case of neonate was also reported from China and was mild.¹⁴

3. Oral Manifestations of COVID-19

COVID-19 presents with an array of oral manifestations which appear during the course of the disease, few lesions manifesting post disease as a secondary infection or as a result of the treatment for the disease.

Most frequently reported oral manifestations include ageusia, anosmia, hyposalivation, ulcers in various parts of oral cavity including tongue, glandular enlargement, cervical lymph node enlargement, angular cheilitis, periodontitis, aphthous and herpetic ulcers. Ageusia(loss of taste) and Anosmia(loss of smell) are the most common oral symptoms.^{15,16}

Mucormycosis or black fungal infection is a potentially dangerous mycotic infection reported in COVID-19 patients. Uncontrolled diabetes mellitus, hyperglycemia, immune suppression and secondary infection, corticosteroid therapy are factors contributing to Mucormycosis as a co-infection in COVID-10 patients.¹⁷ Another Mycotic disease that has been reported in COVID-19 patients is the invasive yeast infections caused by candida species. Prolonged ICU stays, central venous catheters and broad spectrum antibiotic use are the key factors leading to onset of invasive yeast infections in COVID-19 patients.¹⁸

Several other non-specific lesion such as mucositis have been reported in some cases. Exanthema, enanthema,

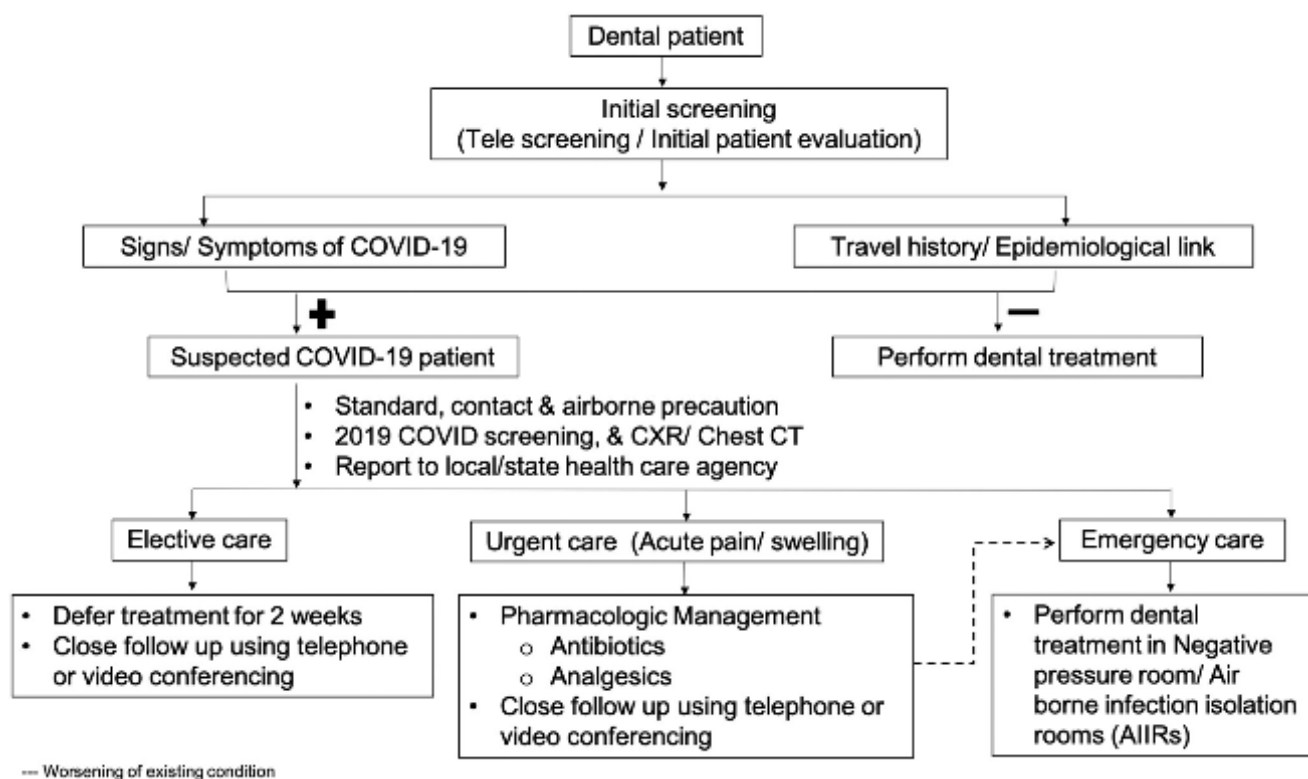


Figure 1: Clinical Dental Care of COVID-19 patients [Adapted from Ather A et al 23

macules, papules and plaques on tongue, lip, palate, etc have been reported. Vasculitis, thrombotic vasculopathy, mucosal hypersensitivity, secondary to COVID-19 might be a cause for the mucositis associated with COVID-19.¹⁹

Table 1: Procedure to wear a personal protective equipment (PPE) - Centre for disease control and prevention²⁰

Gown	<ul style="list-style-type: none"> • Fully cover torso from neck to knees, arms to end of wrists, and wrap around the back • Fasten in back of neck and waist • Secure ties or elastic bands at middle of head and neck
Mask or respirator	<ul style="list-style-type: none"> • Fit band to nose bridge • Fit snug to face and below chin • Fit-check respirator
Goggles or face shield	<ul style="list-style-type: none"> • Place over face and eyes and adjust to
Gloves	<ul style="list-style-type: none"> • Extend to cover wrist of isolation gown
Use of safe work practices to protect yourself and limit the spread of contamination	<ul style="list-style-type: none"> • Keep hands away from face • Limit surfaces touched • Change gloves when torn or heavily contaminated • Perform hand hygiene

4. Guidelines for Dental Practice in this Pandemic

COVID-19 is transmitted through respiratory droplets. Dentists are more prone to exposure to the respiratory droplets as their occupation involves working in oro-facial region. Particularly aerosol inducing procedures such as scaling, root canal treatment etc transmits the disease and the probability of getting infected is high. Hence, safety measures are essential to prevent the dentist from contracting the disease as well as prevent the patient from transmitting the disease. In India, Dental Council of India has formulated a standard to be followed by every Dentist in his practice.²¹

5. Patient Management

Patient is first encouraged towards a telephonic consultation followed by scheduling of appointment. Initial screening is done by asking 3 important questions like whether the patient has come in contact with any COVID-19 patient or suspected patient, their travel history and finally any symptoms for Covid-19 present. Positive response for any of the three question should be considered and in such cases the appointment should be delayed for at least 14days and the patient is advised for a mandatory quarantine. The patient is also advised to consult his general physician.²²

On patient arrival to the clinic, the patient temperature is measured with an infrared thermometer or camera with

Table 2: Procedure for safe removal of ppe kit - centre for disease control and prevention²⁰

Gloves	<ul style="list-style-type: none"> • Outside of gloves are contaminated! • If your hands get contaminated during glove removal, immediately wash your hands or use an alcohol-based hand sanitizer. • Using a gloved hand, grasp the palm area of the other gloved hand and peel off glove • Hold removed glove in gloved hand • Slide of ungloved hand under remaining glove at wrist and peel off second glove over glove • Discard gloves in a waste container
Goggles or face shield	<ul style="list-style-type: none"> • Outside of goggles or face shield are contaminated! • If your hands get contaminated during goggle or face shield removal, immediately wash your hands or use an alcohol-based hand sanitizer • Remove goggles or face shield from the back by lifting head band or ear pieces • If the item is reusable, place in designated receptacle for reprocessing. Otherwise, discard in a waste container
Gown	<ul style="list-style-type: none"> • Gown front and sleeves are contaminated! • If your hands get contaminated during gown removal, immediately wash your hands or use an alcohol-based hand sanitizer • Unfasten gown ties, taking care that sleeves don't contact your body when reaching for ties • Pull gown away from neck and shoulders, touching inside of gown only • Turn gown inside out • Fold or roll into a bundle and discard in a waste container
Mask or respirator	<ul style="list-style-type: none"> • Front of mask/respirator is contaminated — DO NOT TOUCH! • If your hands get contaminated during mask/respirator removal, immediately wash your hands or use an alcohol-based hand sanitizer • Grasp bottom ties or elastics of the mask/respirator, then the ones at the top, and remove without touching the front • Discard in a waste container
<p>Wash hands or use an alcohol-based hand sanitizer immediately after removing all PPE</p>	

infrared sensors. Any patient presenting with fever or any of the COVID-19 symptoms should be given appointment after 14days. As per Centre for Disease Control (CDC) guidelines, the suspected patients should be seated 6ft away from the healthy patients. Their environment should be adequately ventilated.²³ Pharmacological management with antibiotics and analgesics can be advised to these patients. Patient screening and management should be followed as in Figure 1.¹⁰ Patients are classified into elective, urgent and emergency care for their treatment and then further

treatment is planned. For elective care, appointment is delayed for 2 weeks. For urgent care, pharmacological management is first advised and then a close follow up with telephone or video call is done. In case of emergency, care a negative pressure room or airborne infection isolation room is preferred to perform any procedure.²⁴

Patient should be given 0.2% povidone iodine mouth rinse or 0.5-1% hydrogen peroxide mouth rinse as these have proven to reduce load of Corona virus in saliva.^{10,25} Personal care has to be taken by the dentist to prevent the disease transmission. Double masking, use of face shield and personal protective equipment, frequent sanitization of hands can help prevent transmission to the dentist.²³

6. Use of Personal Protective Equipments

There are certain guidelines proposed by Centre for Disease Control and prevention for wearing and safe removing of Personal Protective Equipment kits. The type of PPE used will vary based on the level of precautions required, such as standard and contact, droplet or airborne infection isolation precautions. The procedure for putting on [Table 1] and removing PPE[Table 2] should be tailored to the type of PPE.

7. Safe Removal of Personal Protective Equipment (PPE)

There are a variety of ways to safely remove PPE without contaminating our clothing, skin, or mucous membranes with potentially infectious materials. Remove all PPE before exiting the patient room except a respirator, if worn. Remove the respirator after leaving the patient room and closing the door. A proper sequence must be followed in removing the PPE kit (Table 2).

8. Conclusion

The COVID-19 pandemic is a global crisis due to its propensity to replicate and spread rapidly. It is indeed extremely challenging to control because of emergence of new mutated versions of the virus. To avoid exposure to dentists and also prevent the dental office from serving as area for transmission standard operating protocols by Dental Council of India and from Centres for Disease Control and prevention should be strictly implemented and followed. To conclude, proper oral hygiene to reduce severity of COVID-19, appropriate use corticosteroids and maintenance of blood sugar at optimum level helps prevent severe oral infections that can cause mortality.

9. Source of Funding

None.

10. Conflict of Interest

None.

References

- Chen W, Horby PW, Hayden FG, Gao GF. A novel coronavirus outbreak of global health concern. *Lancet*. 2020;395(10223):470–3.
- Perappadan B. India's first coronavirus infection confirmed in Kerala; 2020. [30 January 2020]. Available from: <https://www.thehindu.com/news/national/indias-first-coronavirus-infection-confirmed-in-kerala/article61638034.ece>.
- Singh G, Priya H, Mishra D, Kumar H, Monga N, Kumari K, et al. Oral manifestations and dental practice recommendations during COVID-19 pandemic. *J Family Med Prim Care*. 2021;10(1):102–9.
- Lan J, Ge J, Yu J, Shan S, Zhou H, Fan S, et al. Structure of the SARS-CoV-2 spike receptor-binding domain bound to the ACE2 receptor. *Nature*. 2020;581:215–20. doi:10.1038/s41586-020-2180-5.
- Mackenzie JS, Smith DW, Covid‑#8209;. A novel zoonotic disease caused by a coronavirus from China: What we know and what we don't. *Microbiol Aust*. 2020;p. MA20013. doi:10.1071/MA20013.
- Choudhary S, Malik YS, Tomar S, Tomar S. Identification of SARS-CoV-2 Cell Entry Inhibitors by Drug Repurposing Using in silico Structure-Based Virtual Screening Approach. *Front Immunol*. 2020;11:1664. doi:10.3389/fimmu.2020.01664.
- Hoffmann M, Weber H, Schroeder S, Krüger N, Herrler T, Erichsen S, et al. SARS-CoV-2 cell entry depends on ACE2 and TMPRSS2 and is blocked by a clinically proven protease inhibitor. *Cell*. 2020;181(2):271–80.e8.
- Bi Q, Wu Y, Mei S, Ye C, Zou X, Zhang Z, et al. Epidemiology and transmission of covid-19 in 391 cases and 1286 of their close contacts in shenzhen, china: A retrospective cohort study. *Lancet Infect Dis*. 2020;20(8):911–9.
- Gu J, Han B, Wang J. Gastrointestinal manifestations and potential fecal-oral transmission. *Gastroenterology*. 2020;158(6):1518–9.
- Kampf G, Todt D, Pfaender S, Steinmann E. Persistence of coronaviruses on inanimate surfaces and its inactivation with biocidal agents. *J Hosp Infect*. 2020;104(3):246–51. doi:10.1016/j.jhin.2020.01.022.
- Chen N, Zhou M, Dong X, Qu J, Gong F, Han Y, et al. Epidemiological and clinical characteristics of 99 cases of 2019 novel coronavirus pneumonia in Wuhan, China: a descriptive study. *Lancet*. 2020;395(10223):507–13.
- Attaway AH, Scheraga RG, Bhimraj A, Biehl M, Hatipoğlu U. Severe covid-19 pneumonia: pathogenesis and clinical management. *BMJ*. 2021;372:372:n436. doi:10.1136/bmj.n436.
- Chen F, Liu ZS, Zhang FR, Xiong R, Chen Y, Cheng XF, et al. First case of severe childhood novel coronavirus pneumonia in China. *Zhonghua Er Ke Za Zhi*. 2020;58(3):179–82.
- Zeng LK, Tao XW, Yuan WH, Wang J, Liu X, Liu ZS, et al. First case of neonate infected with novel coronavirus pneumonia in China. *Zhonghua Er Ke Za Zhi*. 2020;58:E009. doi:10.3760/cma.j.issn.0578-1310.2020.0009.
- Vaira LA, Salzano G, Deiana G, and GD. Anosmia and Ageusia: Common Findings in COVID-19 Patients. *Laryngoscope*. 2020;130(7):1787. doi:10.1002/lary.28692.
- Lechien JR, Chiesa-Estomba CM, De Siati D, Horoi M, Bon SL, Rodriguez A. Olfactory and gustatory dysfunctions as a clinical presentation of mild-to-moderate forms of the coronavirus disease (COVID-19): a multicenter European study. *Eur Arch Otorhinolaryngol*. 2020;277(8):2251–61.
- Singh AK, Singh R, Joshi SR, Misra A. Mucormycosis in COVID-19: A systematic review of cases reported worldwide and in India. *Diabetes Metab Syndr*. 2021;15(4):102146. doi:10.1016/j.dsx.2021.05.019.
- Arastehfar A, Carvalho A, Nguyen MH. COVID-19-Associated Candidiasis (CAC): An Underestimated Complication in the Absence of Immunological Predispositions? *J Fungi (Basel)*. 2020;6(4):211. doi:10.3390/jof6040211.
- Iranmanesh B, Khalili M, Amiri R, Zartab H, Afatoonian M. Oral manifestations of COVID-19 disease: A review article. *Dermatol Ther*. 2021;34(1):e14578. doi:10.1111/dth.14578.
- Centers for Disease Control and Prevention recommendations for putting on and removing personal protective equipment for treating COVID-19 patients; 2020. [Accessed March 17, 2020]. Available from: <https://www.cdc.gov/hai/pdfs/ppe/ppe-sequence.pdf>. Siteaccessed.
- Dental clinics protocol – final. Dental Council of India (May 7,2020). Available from: <https://dciindia.gov.in/Admin/NewsArchives/Dental%20Clinics%20Protocols%20Final.pdf>.
- Wang Y, Wang Y, Chen Y, Qin Q. Unique epidemiological and clinical features of the emerging 2019 novel coronavirus pneumonia (COVID-19) implicate special control measures. *J Med Virol*. 2020;92(6):568–76.
- Centers for Disease Control and Prevention. Infection control: severe acute respiratory syndrome coronavirus 2 (SARS-CoV-2); 2020. [Accessed 9 March, 2020]. Available from: <https://www.cdc.gov/coronavirus/2019-ncov/infection-control/control-recommendations.html>.
- Ather A, Patel B, Ruparel NB, Diogenes A, Hargreaves KM. Coronavirus Disease 19 (COVID-19): Implications for Clinical Dental Care. *J Endod*. 2020;46(5):584–95.
- Peng X, Xu X, Li Y. Transmission routes of 2019-nCoV and controls in dental practice. *Int J Oral Sci*. 2020;12:9. doi:10.1038/s41368-020-0075-9.

Author biography

Ashwath V, Dental Surgeon

Lakshmi Kumari K, Reader

Gowrishankar S, Senior Lecturer

Cite this article: Ashwath V, Kumari K L, Gowrishankar S. Dental implications of COVID-19 - An insight. *IP Indian J Conserv Endod* 2023;8(4):205-209.