

Content available at: <https://www.ipinnovative.com/open-access-journals>

IP Indian Journal of Conservative and Endodontics

Journal homepage: <https://www.ijce.in/>

Case Report

Management of midline diastema using the direct composite resin technique - A case report

M Kishore^{1*}, M Gayathri¹, L Md. Wasim Bari¹, M Sreeja Yadav¹, K Prathibha Laxmi¹

¹Dept. of Conservative Dentistry and Endodontics, Dr. NTR University of Health Sciences, Vijayawada, Andhra Pradesh, India



ARTICLE INFO

Article history:

Received 15-01-2024

Accepted 09-02-2024

Available online 20-03-2024

Keywords:

Midline Diastema

Space Closure

Esthetic Composite

Direct Composite Veneering

Single Visit Treatment

ABSTRACT

Diastema or space between the anterior teeth is a common aesthetic complaint of patients. Direct composite resins in midline diastema cases allow dentists to have complete control in formation of natural smiles. This case report describes midline diastema closure with esthetic composite layering technique. A 25-year-old male patient reported to the clinic, with a complaint of spacing in the upper front tooth region of the jaw. The direct aesthetic composite laminate veneer was considered as the treatment of choice for the build-up of both maxillary central incisors as a more conservative, inexpensive, aesthetic, and quicker option. A2 & A3 shades were selected; prepared tooth surface was etched for 15 seconds using 37% phosphoric acid, rinsed with water for 20 seconds, and air dried with slight air pressure. Bonding agent was applied (Adper single Bond, 3M ESPE, USA) and cured for 20 seconds using (Vivadent Blue phase) curing light. The labial surface of the restoration was flattened using red banded knife-edge tip diamond bur. The natural look of the restored teeth was achieved after finishing and polishing. At six-month and one-year recalls the general outlook of the maxillary anterior teeth was considered natural and aesthetical. Clinically, both restorations have no fractures and also the restoration margins on both maxillary central incisors demonstrated no discolorations. By taking this into consideration and according to the positive results, an experienced dentist with proper case selection, using an appropriate technique and modern materials, can perform highly aesthetic and durable direct composite resin restorations that can satisfy patients as under the conditions of the case presented.

This is an Open Access (OA) journal, and articles are distributed under the terms of the [Creative Commons Attribution-NonCommercial-ShareAlike 4.0 License](https://creativecommons.org/licenses/by-nc-sa/4.0/), which allows others to remix, tweak, and build upon the work non-commercially, as long as appropriate credit is given and the new creations are licensed under the identical terms.

For reprints contact: reprint@ipinnovative.com

1. Introduction

Diastema or space between the anterior teeth is the most common complaint of patients when esthetics is concerned.¹

The etiology of midline diastema is multifactorial. Major etiological factors are labial frenulum, microdontia, mesiodens, peg-shaped lateral incisors, lateral incisor agenesis, cysts in the midline region. Other habits such as finger sucking, tongue thrusting, and/or lip sucking, dental malformations, genetics, maxillary incisor proclination, dental-skeletal discrepancies, and imperfect coalescence of

the interdental septum can cause diastema.^{2,3} Reports shows that the prevalence of midline diastema is higher in maxilla than mandible. Causative factors of midline diastema are,

1. Developmental factors which include microdontia, missing lateral teeth, supernumerary teeth like mesiodens, tongue disorders like macroglossia and macro-hypertrophic fibro frenum.
2. Pathological factors like cysts, tumours, and inflammation of periodontium.
3. Neuromuscular factors such as habits like tongue thrusting, swallowing, or abnormal pressure during rest.^{4,5}

* Corresponding author.

E-mail address: dr.kishore1902@gmail.com (M. Kishore).

In esthetic dentistry, diastema can be corrected by various techniques like direct and indirect composite veneering, porcelain laminate veneers, and crowns like all ceramic, metal-ceramic, and composite crowns.^{6,7}

The selection of appropriate technique and usage of material for a patient depends on time, physical, psychological conditions, and economic limitations.^{8,9}

The use of direct composite resins in cases like midline diastema allows dental practitioners to have complete control in reproduction of natural smiles.¹⁰

This case report is a description of midline diastema closure with direct composite layering technique.

2. Case Report

A 25 year old male patient reported to the clinic, with a chief complaint of spacing in the upper front tooth region (Figure 2). On clinical examination, the medical history was non contributory and intraoral examination revealed, a midline diastema of 2.5 mm was in the maxillary arch (distal to 21 and mesial to 11). More conservative treatment plan was made for which direct composite laminate veneer was considered. The esthetic composite material was chosen for the build-up of both maxillary central incisors. This is inexpensive as well as aesthetic and a quicker option. There were no abnormal clinical and radiographic findings.

3. Discussion

The excellence in choosing direct composite resin restoration is time factor, as it can be completed in a single visit. Other advantages are not requiring the preliminary models and thus eliminating the laboratory fees. Direct composite veneer restorations are advantageous than other possible treatment options such as ceramic veneers and orthodontic treatment procedures.¹¹

The major disadvantage of direct composite resin restoration compared to the porcelain alternatives is of the material features, which include fractional toughness, shear, and compressive strength. These features are low for few composite materials compared to porcelain alternatives. Thus they are not ideal and not suited for ultra high stress areas which have seen in certain clinical situations.^{12,13}

Indirect ceramic fragment restoration is one of the other treatment options for these cases. It is made in a laboratory and is attached to the tooth after preparation. Even though these restorations are esthetically good and help in function, the major disadvantage compared to direct composite veneering technique is its multiple visits with a minimum of two visits.¹⁴

Recent studies showed that direct composite resin technique is esthetic, stable, cost effective and functional. Especially for patients with proper occlusion it can be completed in single visit or less chair side time compared to other techniques.^{15,16}

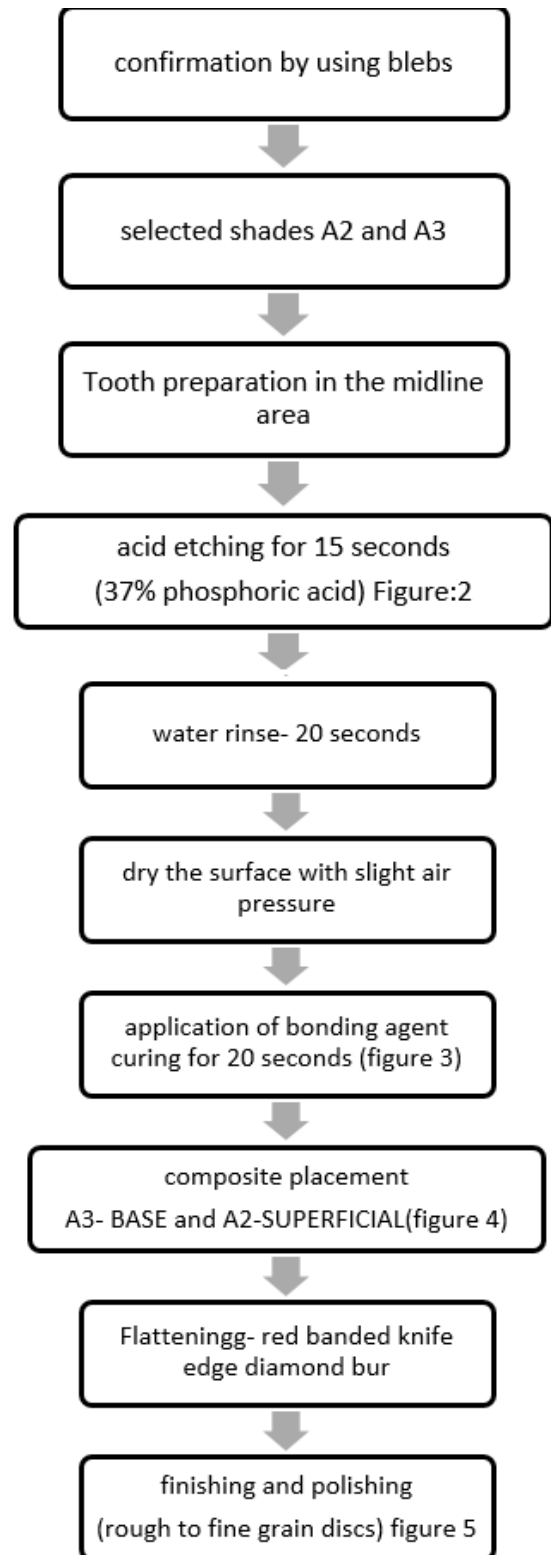


Figure 1: Procedure

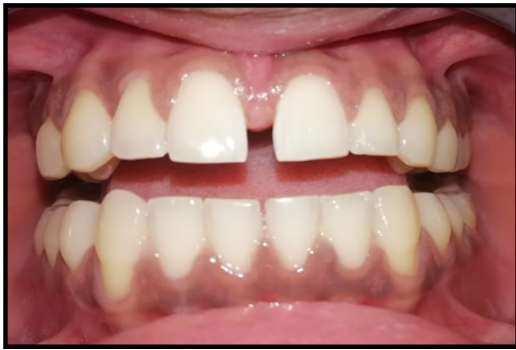

Figure 2:

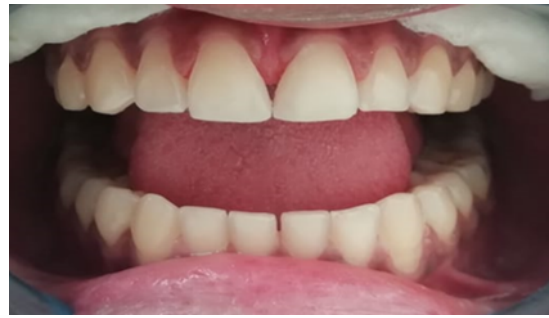

Figure 6:

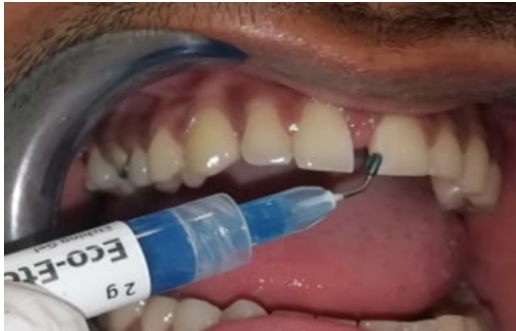

Figure 3:

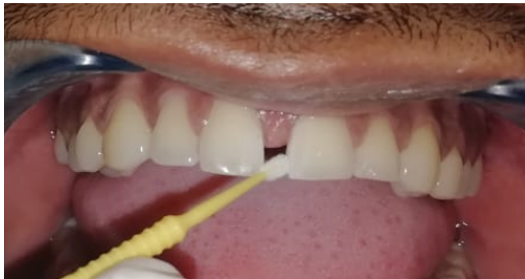

Figure 4:

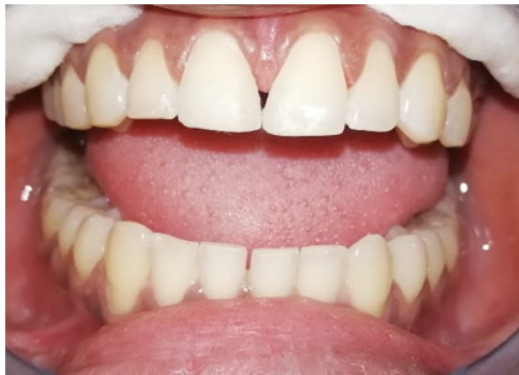

Figure 5:

One of the major advantages of direct composite restorations is its reparability. It can be easily repaired compared to other choices. Color stability of direct resin restorations is acceptable but this feature is much better for ceramic restorations. This drawback can be prevented by providing accurate finishing and polishing and regular recall visits.^{15,17}

Esthetic importance, restricted time and money are the factors responsible for choosing direct composite resin restoration as a treatment procedure in this case. Even though these restorations are advantageous, they have certain drawbacks too. The disadvantages include low fracture toughness, shear and compressive strengths. Thus these restorations are contra indicated in areas of high occlusal load.¹⁸

The longevity of these restorations can be jeopardized due to Para-functional forces acting on the teeth which are not controlled in the cases of bruxism, malocclusion situations like Angles class-III molar relation, end-to-end occlusal relation, and / or oral habits like nail biting.

When it comes to the color sturdiness of the direct composite resin restoration, it is not as excellent as glazed ceramics; although, it absolutely depends on quality of finishing and polishing procedure, and staining of restoration can be halted with frequent visits to the clinic.^{18,19}

In spite of various drawbacks of direct composite resin restorations, improved features of the bonding agents and bonding techniques, advanced resin materials provide the practitioners the positive hope and fortune to design more esthetic, functional, precisely conservative and long standing smiles in a very short period.^{18,19}

Natural and esthetic smile was noticed at 6 months and 1 year recall visits. The restorations on maxillary anterior teeth especially the margins were stable without any discolorations and there were no fracture lines.

Although 1 year follow-up does not seem long enough and further long term follow-ups are required, common problems such as marginal leakage, discoloration of restorations and margins, fractures of the restorations, and de-bonding of the composite resins usually merge within

six months of the treatment procedure, taking this into consideration and according to the positive results of this case, an experienced dental practitioner with proper case selection, using an appropriate technique and modern restorative materials, can perform highly aesthetic and durable direct composite resin restorations that can help the patients as under the conditions of this presented case.

4. Conflict of Interests

There is no conflict of interests.

5. Source of Funding

None.

References

1. Koor K, Muthu MS, Rathna PV. Spontaneous closure of midline diastema following frenectomy. *J Indian Soc Pedod Prev Dent.* 2007;25(1):26–6.
2. Graber T. *Orthodontics: Principles and Practice.* 3rd edn. W.B. Saunders Company; 1972.
3. Tanaka OM, Morino AK, Machuca OF, Schneider N. When the Midline Diastema Is Not Characteristic of the “Ugly Duckling” Stage. *Case Rep Dent.* 2015;p. 924743. doi:10.1155/2015/924743.
4. Tuori K. Weber and the Ideal of Roman Law’, in Andrew Lewis, and Michael Lobban (eds), *Law and History: Current legal Issues 2003 Volume 6, Current Legal Issues* (Oxford, 2004; online edn, Oxford Academic, 22 Mar. 2012). Oxford Academic;. p. 200–14. doi:doi:10.1093/acprof:oso/9780199264148.003.0011..
5. Tanaka OM, Morino AYK, Machuca OF, Schneider NA. When the Midline Diastema Is Not Characteristic of the "Ugly Duckling" Stage. *Case Rep Dent.* 2015;(3):924743. doi:10.1155/2015/924743.
6. Azzaldeen A, Muhamad AH. Diastema Closure with Direct Composite: Architectural Gingival Contouring. *J Adv Med Dent Scie Res.* 2014;3(1):1–6.
7. Azzaldeen A, Nezar W, Muhamad AH. Direct bonding in diastema closure high drama, immediate resolution: a case report. *Int J Dent Health Sci.* 2014;1(4):430–5.
8. Chalifoux PR. Perception esthetics: factors that affect smile design. *J Esthetic Restor Dent.* 1996;8(4):189–92.
9. Prabhu R, Bhaskaran S, Prabhu KG, Eswaran M, Phanikrishna G, Deepthi B, et al. Clinical evaluation of direct composite restoration done for midline diastema closure-long-term study. *J Pharm Bioallied Sci.* 2015;7(6):559–62.
10. Dale BG, Aschheim KW. *Esthetic Dentistry: A Clinical Approach to Techniques and Materials.* vol. 11. Philadelphia, Pa, USA: Lea and Febiger; 1993.
11. Berksun S, Kedici PS, Saglam S. Repair of fractured porcelain restorations with composite bonded porcelain laminate contours. *J Prosthet Dent.* 1993;69(5):457–8.
12. Jordan RE. *Esthetic Composite Bonding: Techniques and Materials.* St. Louis, Mo, USA: Mosby; Revised edition; 1993.
13. Stappert CFJ, Ozden U, Gerds T, Strub JR. Longevity and failure load of ceramic veneers with different preparation designs after exposure to masticatory simulation. *J Prosthet Dent.* 2005;94(2):132–9.
14. Bag B, Bagis YH. Porselen Lamine Veneer’lerin Klinik Uygulama Aşamaları: Klinik Bir Olgu Sunumu. *Ankara Üniversitesi Diş Hekimliği Fakültesi Dergisi.* 2006;33(1):49–57.
15. Prabhu R, Bhaskaran S, Prabhu KG, Eswaran M, Phanikrishna G, Deepthi B, et al. Clinical evaluation of direct composite restoration done for midline diastema closure-long-term study. *J Pharm Bioallied Sci.* 2015;7(6):559–62.
16. Khashayar G, Dozic A, Kleverlaan CJ, Feilzer AJ, Roeters J. The influence of varying layer thicknesses on the color predictability of two different composite layering concepts. *Dent Mater.* 2014;30(5):493–8.
17. Azzaldeen A, Muhamad AH. Diastema closure with direct composite: architectural gingival contouring. *J Adv Med Dent Sci Res.* 2015;3(1):134–9.
18. Stappert CFJ, Ozden U, Gerds T, Strub JR. Longevity and failure load of ceramic veneers with different preparation designs after exposure to masticatory simulation. *J Prosthetic Dent.* 2005;94(2):132–9.
19. Garber DA, Goldstein RE, Feinman RA. *Porcelain Laminate Veneers.* vol. 3. Chicago, Ill, USA: Quintessence Publishing; 1988.

Author biography

M Kishore, Senior Lecturer

M Gayathri, Senior Lecturer

L Md. Wasim Bari, Clinician and Consultant Endodontist

M Sreeja Yadav, Senior Lecturer

K Prathibha Laxmi, Senior Lecturer

Cite this article: Kishore M, Gayathri M, Bari LMW, Yadav MS, Laxmi KP. Management of midline diastema using the direct composite resin technique - A case report. *IP Indian J Conserv Endod* 2024;9(1):45-48.