

Content available at: <https://www.ipinnovative.com/open-access-journals>

IP Indian Journal of Conservative and Endodontics

Journal homepage: <https://www.ijce.in/>

## Case Report

# Non-surgical management of simultaneous occurrence of internal root resorption and calcific metamorphosis: A case report

H.C Baranwal<sup>1</sup>, Gracemol Raju<sup>1\*</sup>

<sup>1</sup>Dept. of Conservative Dentistry and Endodontics, Faculty of dental Sciences, IMS, Banaras Hindu University, Varanasi, Uttar Pradesh, India



### ARTICLE INFO

#### Article history:

Received 02-04-2024

Accepted 22-05-2024

Available online 03-06-2024

#### Keywords:

Calcific metamorphosis

Internal resorption

Periapical abscess

### ABSTRACT

Internal resorption and calcific metamorphosis are two sequelae of pulpal necrosis after traumatic injuries like concussion and luxation injuries. After traumatic injury, the pulp may become completely necrosed followed by calcification of the entire root canal by the activity of odontoblastic cells. In some other cases, partial necrosis of the pulp tissue with overstimulation of odontoclastic cells and resorption of the root canal dentinal walls may happened. Commonly any of the cells become active and one of the sequelae may will continue. Rarely these two conditions will happen together. In this particular case report with simultaneous occurrence of these two conditions with symptomatic periapical abscess.

This is an Open Access (OA) journal, and articles are distributed under the terms of the [Creative Commons Attribution-NonCommercial-ShareAlike 4.0 License](https://creativecommons.org/licenses/by-nc-sa/4.0/), which allows others to remix, tweak, and build upon the work non-commercially, as long as appropriate credit is given and the new creations are licensed under the identical terms.

For reprints contact: [reprint@ipinnovative.com](mailto:reprint@ipinnovative.com)

## 1. Introduction

Two common pathologic pulpal sequelae have been occurred after traumatic injury like concussion or subluxation, are either calcific metamorphosis or internal resorption. Calcific metamorphosis is probably initiated by a stimulation of odontoblastic activity in pulpal response to dental trauma with deposition of hard tissue and partial or total obliteration of pulp canal space. The tooth clinically present with discolouration. Internal resorption is probably initiated by stimulation of odontoclastic activity, which are predominantly recruited through the blood vessel. It is an uncommon resorption of the tooth starts from the root canal and destroys the surrounding tooth structure. If not treated it actively progresses to involve adjacent dentine areas; may lead to perforation. Generally, if one of these processes begins and is left untreated, the course of events will continue.<sup>1-5</sup> In this case, there is rare presentation of internal resorption in a calcific metamorphosed tooth with

periapical abscess.

## 2. Case Report

A 33-year-old male patient came to OPD with chief complaint of discoloured tooth on upper front teeth region for 10 years and swelling on front aspect of palatal region since 3 days. History of trauma to anterior teeth 12 years ago and patient's medical history was noncontributory. On clinical examination, Grade 1 mobility of tooth in relation to upper left central incisor and anterior palatal tender swelling. Teeth in relation to 21 and 22 showed negative response on EPT and cold pulp testing and both teeth are tender on vertical percussion. Pre operative intra oral periapical radiograph and maxillary occlusal radiograph showed obliteration of pulpal space with an ill-defined radiolucency near to the center in the cervical third of root canal. Ill defined apical radiolucency was also present in relation to 21 and 22. Thus, provisional diagnosis of pulp necrosis followed by calcification and cervical internal root resorption with symptomatic periapical abscess was made

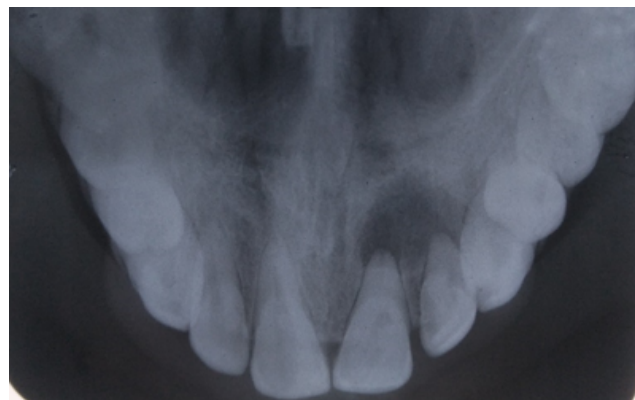\* Corresponding author.

E-mail address: [gracemolraju94@gmail.com](mailto:gracemolraju94@gmail.com) (Gracemol Raju).

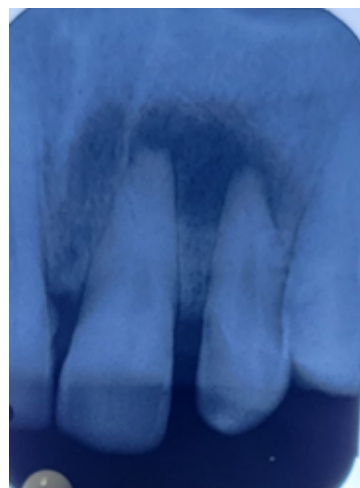
and root canal therapy with thermoplastic obturation was planned.

### 2.1. Management

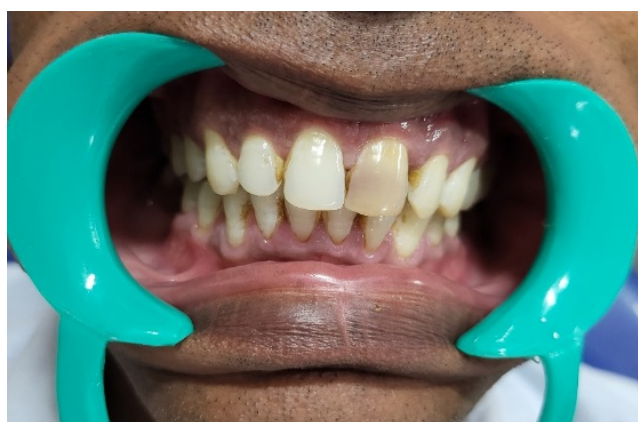The proper assessment of tooth position and angulations was made and access cavity was initiated carefully after rubber dam isolation with the high speed no 4 round bur towards the pulp chamber in a stepwise removal of enamel and dentin. A proper access was made with the help of Endo Z bur. (Dentsply endo Z tungsten carbide). An endodontic explorer DG 16 was used to obtain catch point in the centre of tooth where tiny blackish discolouration point was noted. The line of patency of canal was negotiated with the help of no 8 c+ files, which is always maintained in the line parallel to the long axis of tooth. A copious amount of 17% EDTA was used to demineralise the restricted hard tissues along the canal. The glide path was obtained using no 10 C+ files. Cleaning and shaping of canal done by rotary instruments till protaper F3. Irrigation with NaOCl and ultra sonic activation done to remove the tissue debris from the resorption space. Finally thorough irrigation done with normal saline and Ca (OH)<sub>2</sub> intracanal medicament dressing done. Patient was recalled after 3 weeks and irrigate the canal with normal saline. Dried with paper points. Obturation of upper left lateral incisor with F3 cone. In Upper left central incisor place the F3 cone with sealer for proper apical seal. Removal of gutta-percha from just below the internal resorption defect level. Resorption defect and above it is filled with thermoplastic obturation technique by using Bee fill 2 in 1. After proper condensation periapical radiograph was taken for conformation of proper seal. Permanent restoration done with composite resin.



**Figure 2:** Maxillary occlusal radiograph showing calcified canal with periapical radiolucency



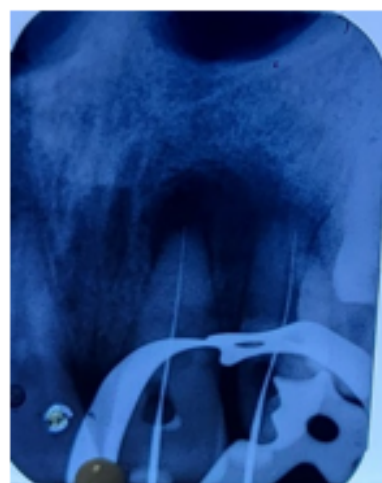**Figure 3:** Pre-operative IOPAR



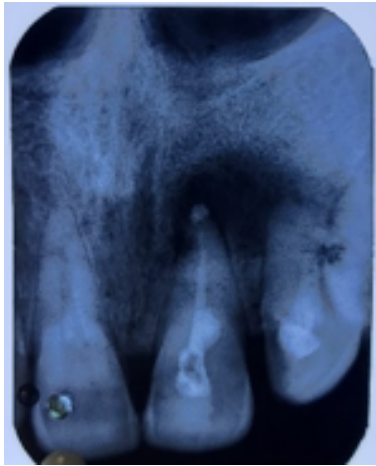
**Figure 1:** Facial view of the patient showing yellowish discoloration of upper left central incisor

### 3. Discussion

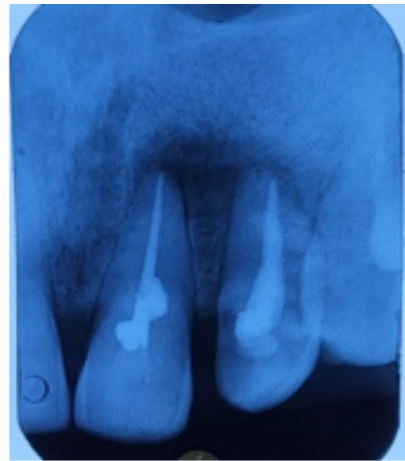The occurrence of calcific metamorphosis is more common in anterior teeth, but the exact mechanism of canal



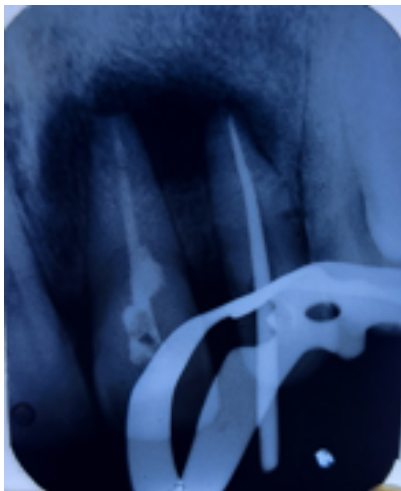**Figure 4:** Working length IOPAR



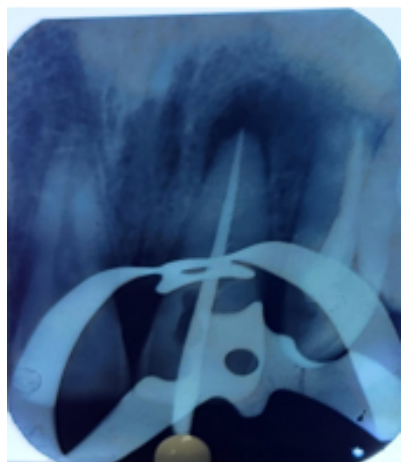**Figure 5:** Ca(OH)<sub>2</sub> intra canal medicament dressing



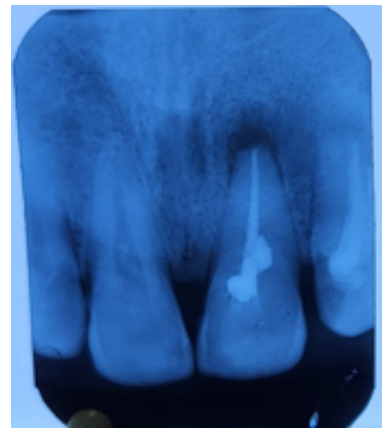
**Figure 8:** Thermoplastic obturation



**Figure 6:** Master cone IOPAR of 22



**Figure 7:** Master cone IOPAR of 21



**Figure 9:** 6 Months follow up

obliteration is unclear. The chance of pulp canal obliteration after dental trauma ranges from 4 to 24 %.<sup>1</sup> According to the American Association of Endodontics case assessment criteria, the endodontic treatment of the calcified teeth falls in high difficult treatment criteria. The proper knowledge about the anatomy of teeth is the first step in managing calcified teeth. The location of canal orifice is the difficult step in this management. According to the law of root canal location, the pulp chamber always presents in the center of tooth at the level of CEJ.<sup>2</sup> The color of pulp chamber which is darker than normal dentin also indicates the location of orifice. Usage of Methylene blue and champagne bubble test are also useful in finding calcified canal. Negotiation and preparation of root canal up to working length is the second difficult step. Endodontic instruments like DG 16 explorer, canal pathfinder; C+ files have the capacity to penetrate deeply inside the canal. The normal K files lack rigidity and more prone to fracture as compared to more rigid C+ file. So, the ideal file for negotiating calcified canal is C+ Files. LN burs and Mueller burs

are modified burs for the management of calcified canals. Precise identification of canal orifice can be done with operating microscope by increased magnification. High accuracy of negotiation and successful management of the calcified canal with dental loupes, ultrasonic tips and pre operative CBCT evaluation. Internal resorption (IR) is a rare, resorptive pathological process, beginning in the pulpal space and extending into the surrounding dentin. Due to its insidious pathology, internal resorption can progress to a great extent before its detection. Arresting the cellular activity is the main concern while managing such resorptive lesions. So proper biomechanical preparation is the most essential thing during the management. Only 2% cases show clinical signs.<sup>5-11</sup> Majority of the cases stayed as asymptomatic for a long period of time. In some cases, the lesion may be detected accidentally during routine dental check-up. An internal resorption lesion mainly consists of granulation tissue infiltrated by lymphocytes, macrophages, neutrophilic leukocytes, and plasma cells. In majority of cases of active internal resorption, the tooth is partially or fully vital with a consistent blood supply to the granulation tissue in the resorption area. In this particular case shows calcified canal along with internal resorption. For both clinical entity the common etiology is traumatic injury like concussion or subluxation. As these two lesions are caused by two different cell type activity, simultaneous occurrence of these two are very rare. Histologically internal resorption is mainly caused by the increased activity of odontoclastic cells and calcification by odontoblast cells. In normal scenario, after traumatic injury to teeth, either the calcification or resorption may happen and delayed treatment can lead to progression of any of these lesions. However, it can be arrested in its initial phase if detected earlier. Calcium hydroxide has been known to be a potent inhibitor of inflammation. The prognosis of treatment depends on the extent or the size of lesion.<sup>4</sup> But in this case the tooth became non-vital and pulpal tissues showed calcification after its necrosis. So, can concluded that the lesion was in inactive state and properly done conventional root canal therapy can resolve the pathology.

#### 4. Conclusion

Early diagnosis, removal of the cause, proper treatment of the resorbed root is mandatory for successful treatment outcome. Proper removal of resorbed tissue and disinfection will stop the further progression of internal resorption. Thermoplastisized obturation is one of the best method for

obturation of tooth with internal resorption. In this case noted with clinical and radiographical signs of healing after conventional root canal treatment.

#### 5. Source of Funding

None.

#### 6. Conflict of Interest


None.

#### References

1. McCabe PS, Dummer PMH. Pulp canal obliteration: an endodontic diagnosis and treatment challenge. *Int Endod J.* 2011;45(2):177–97.
2. Krasner P, Rankow HJ. Anatomy of the pulp chamber floor. *J Endod.* 2003;30(1):5–16.
3. Kobayashi C. Penetration of constricted canals with modified K files. *J Endod.* 1997;23(6):391–3.
4. Thomas P, Pillai RK, Ramakrishnan BP, Palani J. Review Article An Insight into Internal Resorption. *ISRN Dent.* 2014;p. 7. doi:10.1155/2014/759326.
5. Andreassen JO. Luxation of permanent teeth due to trauma. A clinical and radiographic follow-up study of 189 injured teeth. *Eur J Oral Sci.* 1970;78(1-4):273–86.
6. Wedenberg C, Zetterqvist L. Internal resorption in human teeth—a histological, scanning electron microscopic, and enzyme histochemical study. *J Endod.* 1987;13(6):255–9.
7. Moule AJ, Moule CA. The endodontic management of traumatized permanent anterior teeth: a review. *Aust Dent J.* 2007;52(1):122–37.
8. Robertson A. A retrospective evaluation of patients with uncomplicated crown fractures and luxation injuries. *Endod Dent Traumatol.* 1998;14(6):245–56.
9. Ne RF, Witherspoon DE, Gutmann JL. Tooth resorption. *Quintessence Int.* 1999;30(1):9–25.
10. Heithersay GS. Clinical endodontic and surgical management of tooth and associated bone resorption. *Int Endod J.* 1985;18(2):72–92.
11. Goultschin J, Nitzan D, Azaz B. Root resorption: review and discussion,” *Oral Surgery, Oral Medicine. Oral Pathol.* 1982;54(5):586–90.

#### Author biography

**H.C Baranwal**, Dean and Professor  <https://orcid.org/0000-0002-1694-4933>

**Gracemol Raju**, MDS Student  <https://orcid.org/0009-0008-5240-285X>

**Cite this article:** Baranwal HC, Gracemol Raju. Non-surgical management of simultaneous occurrence of internal root resorption and calcific metamorphosis: A case report. *IP Indian J Conserv Endod* 2024;9(2):75-78.