

Content available at: <https://www.ipinnovative.com/open-access-journals>

IP Indian Journal of Conservative and Endodontics

Journal homepage: <https://www.ijce.in/>

## Case Report

# Management of iatrogenic root perforation using mineral trioxide aggregate as a repair material – A case report

Harakh chand Baranwal<sup>1</sup>, Vijul<sup>\*</sup>

<sup>1</sup>Faculty of Dental Sciences, Banaras Hindu University, Varanasi, Uttar Pradesh, India



## ARTICLE INFO

### Article history:

Received 26-03-2024

Accepted 19-04-2024

Available online 03-06-2024

### Keywords:

Iatrogenic root perforations

Mineral trioxide aggregate (MTA)

## ABSTRACT

Root perforations are one of the unsolicited complications of endodontic treatment. Early diagnosis of the defect, location of the perforation, choice of treatment materials used, host response, and practitioner's experience are the factors responsible for the successful management of root perforations. Perforations should be managed as soon as they are diagnosed. Several materials have been used for the management of root perforations, out of which Mineral trioxide aggregate is the most commonly used repair material. This case report presents the successful non-surgical management of iatrogenic perforation; repaired, treated and sealed with MTA.

This is an Open Access (OA) journal, and articles are distributed under the terms of the [Creative Commons Attribution-NonCommercial-ShareAlike 4.0 License](https://creativecommons.org/licenses/by-nc-sa/4.0/), which allows others to remix, tweak, and build upon the work non-commercially, as long as appropriate credit is given and the new creations are licensed under the identical terms.

For reprints contact: [reprint@ipinnovative.com](mailto:reprint@ipinnovative.com)

## 1. Introduction

Perforations can be defined as communications between the tooth and supporting tissues that are formed either iatrogenically or pathologically that can drastically affect the prognosis of the root canal therapy in the long run.<sup>1</sup> Perforations once diagnosed, must be treated immediately to seal the communication between the tooth and surrounding tissues to minimize the injury and prevent contamination of the periodontium.<sup>2</sup>

A perforation into the supporting tissues might not necessarily involve pulp, however, healing can be hampered if the perforation site is superimposed with some kind of bacterial infection or an irritating restorative material, leading to consequences like proliferation or gingival down growth of epithelium into the perforation area,<sup>3</sup> destruction of periodontal fibers, formation of granulomatous tissue, inflammation, bone resorption<sup>4,5</sup> and ultimately tooth loss. Therefore, proper asepsis should be maintained during perforation repair to avoid any of these consequences.<sup>6</sup>

Materials that can be used for management of perforations include, amalgam, calcium hydroxide, gutta percha, super EBA, composite resin, cavit (temporary filling material), zinc oxide–eugenol, IRM, glass ionomer, resin/metal modified glass ionomer, dentin chips, hydroxyapatite, Portland cement, MTA and Biodentine. The material to be chosen for perforation repair should be antimicrobial, non-cariogenic, nontoxic, non-absorbable, radiopaque, promote osteogenesis and cementogenesis and provide a seal against microleakage from the perforation.<sup>3</sup>

One of all the materials listed, Mineral trioxide aggregate (MTA) has most of the above mentioned characteristics. It has shown good outcomes in apexification, radicular resorption, root-end surgery, direct pulpal coverage and repair of lateral radicular and furcal perforation.<sup>4</sup>

The present case report illustrates the successful management of an iatrogenic perforation at a cervical level of the root on the mesial aspect of a lower central incisor.

<sup>\*</sup> Corresponding author.

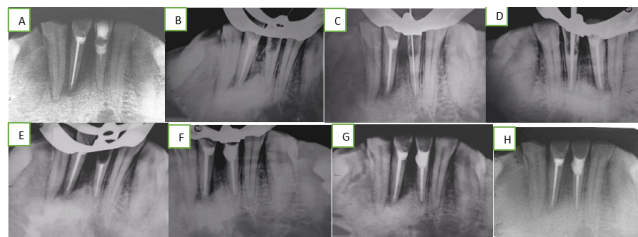
E-mail address: [vijul6638@gmail.com](mailto:vijul6638@gmail.com) (Vijul).

## 2. Case Report


A 34-year old female patient was referred to our department of Conservative dentistry and Endodontics, with a chief complaint of pain and discomfort in lower front tooth for the past one week. She gave history of root canal procedure done one week prior at a private clinic. On clinical examination, 31 was tender on percussion with temporary restoration placed on the lingual surface. No evident localised gingival inflammation or no probing depth was found. An intraoral periapical radiograph revealed attempted root canal procedure and perforation in 31 at cervical level of root. The treatment plan was non-surgical management of perforation site using MTA and complete root canal of 31.

Patient's consent was taken and the tooth was anaesthetized with 2% lignocaine (1:1,00,000 adrenaline) and isolated with rubber dam.

The root canal of 31 was negotiated fully and working length was determined. Cleaning and shaping were carried out using ProTaper rotary files system with irrigation of 3% sodium hypochlorite (NaOCl). Final irrigation was done using normal saline. Apical preparation was performed for single cone obturation and obturation was done with FI gutta-percha (Dentsply) using zinc oxide eugenol as sealer. Gutta percha was condensed below the level of perforation. Mineral trioxide aggregate (MTA – ANGELUS) was mixed and carried to the perforation site with the help of a carrier and packed with an appropriately fitted plugger. Repair of the perforation was carried out by progressive placement and packing of small increments of the Mineral Trioxide Aggregate followed by post-endo restoration with Type 2 Universal Restorative Glass Ionomer Cement. Immediate post-operative x-ray was taken. At the 1week follow-up, the patient was asymptomatic. Patient was kept on regular follow up.



**Figure 1:** (IOPA radiographs): (A,B,C) Pre- op , Perforation at cervical level of root, working length measurement; (D,E,F) Master cone placed, Obturation done below the level of perforation, MTA placed to repair perforation; (G,H) Post-op, 3 month follow up showing evident bone healing.



**Figure 2:** (Clinical photographs): (A,B,C) Pre-op, Access cavity prepared, bleeding observed in the canal due to perforation; (D,E) MTA placed in canal after obturation, Post- endo completed with GIC

## 3. Discussion

The role of endodontic therapy is unparalleled in maintaining the integrity of the natural dentition and its supporting structures and perforations during these procedures are the second greatest cause of failure of treatment.<sup>7</sup>

When the perforation site is small and easily accessible, with no infection and healthy periodontium non-surgical perforation repair should be opted. The cases in which non-surgical retreatment fails to respond, or in which concomitant management of the periodontium is required, surgical intervention is employed.<sup>8</sup>

Critical factors influencing the successful prognosis are mainly, the prevention of bacterial infection of the perforation site, the time duration between perforation and its repair, the location of the perforation, and a treatment provided as soon as possible.<sup>9</sup>

In the present case, the perforation was encountered in the mesial cervical area of the root of the lower left central incisor, which might have been created during access preparation while locating the canal orifice or flaring coronal third of the root canal. The first sign of perforation is considered to be the sudden appearance of blood from the canal. To avoid such errors, access cavity preparation should be carried out about the tooth anatomy, along with the help of microscopes to locate the canal orifice.<sup>2</sup>

MTA consists of fine hydrophilic particles of tricalcium silicate, tricalcium laminate, tricalcium oxide, with small amounts of mineral oxides. Bismuth oxide powder provides radiopacity. pH is 12.5, with low solubility and compressive strength, thereby discouraging its placement in functional areas.<sup>10</sup>

Torabinejad and colleagues found no marginal gaps in root end fillings with MTA, while they found gaps ranging from 3.8 to 14.9 microns with amalgam, super EBA, and

IRM. In another study, Torabinejad and colleagues found that MTA leaked significantly less than amalgam and super EBA when placed in 3mm root end preparations.<sup>11</sup>

Bates and colleagues used a fluid filtration device to test the sealing properties of MTA super EBA and amalgam, it was found that MTA has superior sealing properties when compared to others.

Wu and colleagues found that the seal created with MTA in root end fillings lasts for at least a year.<sup>12</sup>

Biocompatibility of MTA has been studied by several authors who found it to be less cytotoxic, non-mutagenic, and with less microleakage allowing cementum overgrowth and may actively promote in the formation of hard tissue.<sup>13</sup>

#### 4. Conclusion

Perforations are an unfortunate mishap that can happen to the best of us. However, the management approach undertaken to deal with these significantly impacts the prognosis of the case. A well-aware should therefore make all necessary efforts to avoid such situations in the first place. The advent of newer bioceramic repair materials such as MTA has aided in turning these failures into an endodontic success.

#### 5. Source of Funding

None.

#### 6. Conflict of Interest


None.


#### References

1. Fuss Z, Trope M. Root perforations: classification and treatment choices based on prognostic factors. *Endod Dent Traumatol.* 1996;12(6):255–64.
2. Bansode PV, Pathak S, Wavdhane MB, Khedgikar S, Gite S. Shirish Khedgikar, Dr. Shraddha Gite - Non-Surgical Repair of A Perforation

- Defect-A Case Report. *J Med Dent Sci Res.* 2017;4(1):32–5.
3. Balla R, LoMonaco CJ, Skribner J, Lin LM. Histological study of furcation perforations treated with tricalcium phosphate, hydroxyapatite, amalgam, and Life. *J Endod.* 1991;17(5):234–8.
4. Petersson K, Hasselgren G, Tronstad L. Endodontic treatment of experimental root perforations in dog teeth. *Endod Dent Traumatol.* 1985;1(1):22–8.
5. Seltzer S, t IS, Augus D. Periodontal effects of root perforations before and during endodontic procedures. *J Dent Res.* 1970;49(2):332–9.
6. Beavers RA, Bergenholtz G, Cox CF. Periodontal wound healing following intentional root perforations in permanent teeth of Macaca mutlatta. *Int Endod J.* 1986;19(1):36–44.
7. Bakland LK. Endodontic mishaps: perforations. *J Calif Dent Assoc.* 1991;19(4):41–4.
8. Fuss Z, Trope M. Root perforations: classification and treatment choices based on prognostic factors. *Endod Dent Traumatol.* 1996;12(6):255–64.
9. Ng YL, Mann V, Gulabivala K. A prospective study of the factors affecting outcomes of nonsurgical root canal treatment: part 1: periapical health. *Int Endod J.* 2011;44(7):583–609.
10. Shihaab SS, Sharma S. Perforations in endodontics. *Int J Curr Adv Res.* 2017;6(3):2919–22.
11. Beltes P, Zervas P, Lambrianidis T, Moylyvdas I. Invitro study of the sealing ability of four retrograde filling materials. *Endod Dent Traumatol.* 1988;4(2):82–4.
12. Bondra DL, Hartwell GR, Macpherson MG, Portell FR. Leakage in vitro with IRM, high copper amalgam and EBA cements as retrofilling materials. *J Endod.* 1989;15(4):157–60.
13. Torabinejad M, Watson TF, Ford TP. Sealing ability of a mineral trioxide aggregate when used as a root end filling material. *J Endod.* 1993;19(12):591–5.

#### Author biography

**Harakh chand Baranwal**, Dean and Professor  <https://orcid.org/0000-0002-1694-4933>

**Vijul**, Junior Resident  <https://orcid.org/0009-0009-2930-6525>

**Cite this article:** Baranwal H, Vijul. Management of iatrogenic root perforation using mineral trioxide aggregate as a repair material – A case report. *IP Indian J Conserv Endod* 2024;9(2):92-94.