

Apexification of non-vital central incisors with wide open apices using biodentine for inducing artificial apical plug

Kavita Dube^{1,*}, Soumya Shukla², Bonny Paul³, Charu Kapur⁴

¹Reader, ³Professor, ⁴Lecturer, Dept. of Conservative Dentistry & Endodontics, ²Senior Lecturer, Dept. of Pedodontics & Preventive Dentistry, Hitkarini Dental College & Hospital, Jabalpur

***Corresponding Author:**

Email: drkdube@gmail.com

Abstract

This article reports the treatment of seven traumatized non-vital central incisors in four patients by apexification with Biodentine after placement of a suitable intracanal medicament (Metapex/Triple antibiotic paste) for 15 days. The teeth were obturated in the same appointment. The patients were recalled at intervals of 3 months, 6 months and one year. All teeth were asymptomatic after a follow up of one year and showed radiographic signs of healing. Based on the existing literature and our present cases, Biodentine can be used efficiently for apexification procedure. However, long-term clinical trials and investigations are further required.

Keywords: Apexification, MTA, BioDentine, Open apices

Introduction

Traumatic injury of an immature permanent tooth can lead to the loss of pulp vitality and may also arrest the root development, leading to non-vital tooth with open apices.¹ The process of completion of root development and the closure of the root apex occurs upto 3 years after eruption of the tooth.²

Unfortunately traumatic injuries occurring on young permanent tooth are not rare, and the majority of them occurs before the root formation is complete, and often result in pulpal inflammation or necrosis.³ These teeth present wide dentinal tubules that allow the penetration of bacteria and their irritants.⁴ A non-vital open apex tooth presents a number of difficulties for efficient root canal therapy.⁵ Kaiser first introduced the use of calcium hydroxide in 1964 and proposed using it along with camphorated parachlorophenol to induce the formation of calcified apical barrier.⁴ Although the technique is efficient, but has several disadvantages like time taken for induction of a calcified apical barrier varies between 6-24 months, hence prolonged treatment involves risk of bacterial recontamination, increases dentine brittleness and increases the risk of cervical fractures.⁶

In recent times, synthetic apical barriers have popularized as alternatives to the traditional methods, like introduction of MTA Mineral Trioxide Aggregate, CEM Calcium Enriched Mixture and a novel material Biodentine launched in 2009 is claiming to be a revolutionary material capable of offering a bioactive and biocompatible replacement for dentine.⁷ Biodentine is similar to MTA in basic composition and serves as its substitute.⁴

The following clinical cases report the successful outcome of inducing artificial apical barrier by an apical plug of Biodentine.

Case Report

The study was peer reviewed and approved by a local board of research and ethics. Included were 7 necrotic single rooted teeth with open apices. Patient's age ranged from 9 to 13 years old. Cold test was conducted for all teeth using Endo-frost cold spray Coltene Whaledent, Germany, for which none of teeth responded positively. Thorough clinical examination was carried out, a summary of the descriptive data of cases in the first visit are shown on Table 1.

Table 1: Descriptive data of clinical examination

Case	Tooth number	Age/ Gender	Clinical Examination
1.	11 & 21	10 years/Female	Ellis class IV fracture in 11 & 21. Pain, swelling with labial mucosa, active pus discharge
2.	11 & 21	13 years/Male	Ellis class IV fracture in 11 & 21. Grade I mobility. Pain, swelling with labial mucosa, active pus discharge.
3.	11 & 21	11years /Female	Ellis class IV fracture in 11 & 21. Grade I mobility. Pain, swelling with labial mucosa, active pus discharge
4.	11	9years/Male	Ellis class IV fracture in 11 & 21. Grade I mobility. Pain, swelling with labial mucosa, active pus discharge

After obtaining informed oral and written consent from patients, the treatment was commenced. Local anaesthesia was obtained with 2% lignocaine 1:80000 dilution access cavity was prepared and working length was determined. Biomechanical preparation was carried out using 80 size k file in circumferential manner. Root canal was disinfected using 3% sodium hypochlorite and sterile normal saline. The canal was dried with a large size paper point and intracanal dressings were placed as mentioned in Table 2.

Table 2: Details of intracanal medicaments used

Case	Tooth number	Intracanal medicament
1.	11 & 21	Triple antibiotic paste comprising of minocycline, ciprofloxacin and metronidazole 100µg each ml ⁻¹ with propylene glycol as a vehicle was packed 1mm short of the radiographic apex
2.	11 & 21	Triple antibiotic paste comprising minocycline, ciprofloxacin and metronidazole 100µg each ml ⁻¹ with propylene glycol as a vehicle was packed 1mm short of the radiographic apex
3.	11 & 21	Metapex – Calcium Hydroxide with Iodoform Meta Biomed Co. Ltd, Korea was packed in the canal 1mm short of the radiographic apex
4.	11	Metapex was packed in the canal 1mm short of the radiographic apex

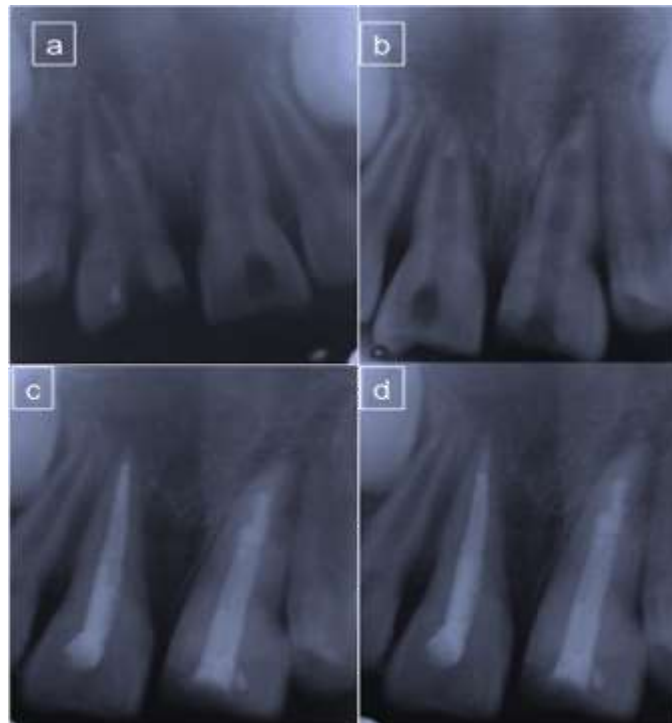


Fig. 1

- a. Pre-operative radiograph
- b. Radiograph after placement of apical plug
- c. Post-obturation Radiograph
- d. Radiograph – at one year follow up

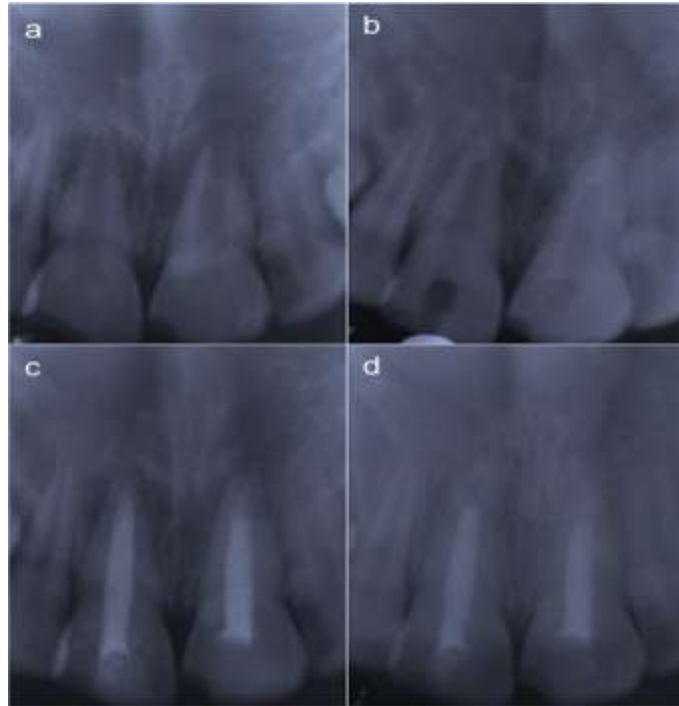


Fig. 2

- a. Pre-operative radiograph**
- b. Radiograph after placement of apical plug.**
- c. Post – obturation Radiograph**
- d. Radiograph – at one year follow up**

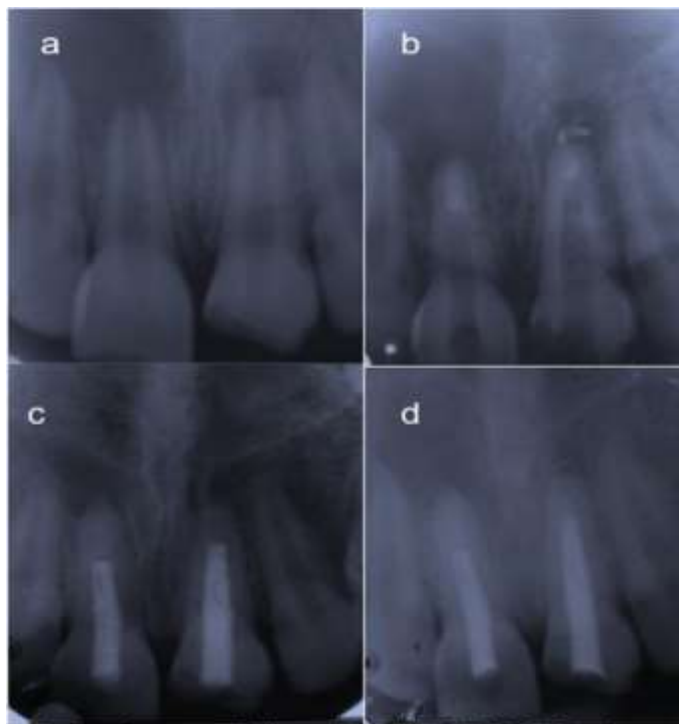

Fig. 3

- a. Pre-operative radiograph**
- b. Radiograph after placement of apical plug.**
- c. Post – obturation Radiograph**
- d. Radiograph – at one year follow up**

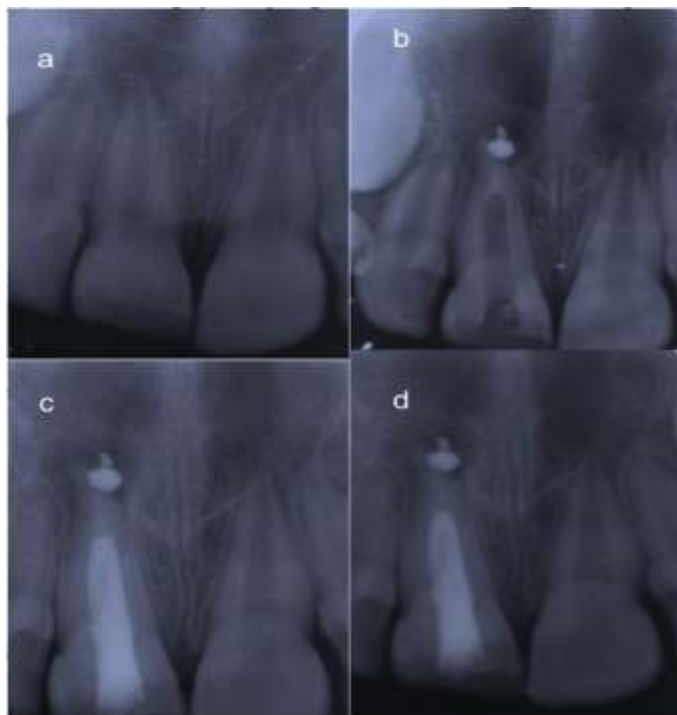


Fig. 4

- a. Pre-operative radiograph
 b. Radiograph after placement of apical plug.
 c. Post – obturation Radiograph
 Radiograph – at one year follow up

The access cavity was temporarily sealed with Glass ionomer cement GC Fuji Type II, France and the patients were recalled after 2 weeks.

After 2 weeks, when the patients were asymptomatic, the intracanal medicament was removed with copious irrigation and H files. The canals were flushed with 3% hypochlorite followed by sterile normal saline and dried with absorbent paper points. Biodentine (Septodont, St. Maudes Fosses, France) was manipulated according to manufacturer's recommendation and placed in the apical one third of the root canal with help of hand pluggers and condensed to form an apical plug of 3-4mm and was left undisturbed for 15-20 minutes. The central incisors were then obturated using lateral condensation technique with AH plus sealer (Dentsply, Germany) and restored. Follow up and clinical examination after 1 month showed absence of clinical symptoms; the patient was kept on follow up and recall visits for 3months, 6months and 1 year follow up and on every appointment IOPA Radiograph were advised, which showed progressive involution of periapical radiolucency and healing at the apex.(Fig. 1,4)

Discussion

Induction of apical healing required 3-4months with Calcium Hydroxide and multiple appointments. Patient compliance with this regime may be poor; the

temporary seal may result in reinfection and prolongation of the treatment. This led to the single visit apexification technique which has gained popularity and be considered as an effective alternative to calcium hydroxide apexification.

Morse et al defined one visit apexification as the non-surgical condensation of a biocompatible material into the apical end of the root canal. This technique is a viable option for treating immature teeth with necrotic pulps². It has been postulated that the material for choice for apexification should have cement-conductive potential⁵.

The use of Mineral Trioxide aggregate (MTA) for single visit apexification has gained wide popularity. Torabinajad et al hypothesized that cementogenic properties of MTA might be due to several features such as biocompatibility, alkalinity and sealing ability⁹. The pH value of MTA is 10.2 after mixing which rises upto 12.5, 3 hours after mixing. The sustained Calcium Hydroxide release by MTA is due to its ability to maintain a high pH for a long period of time 78 days after its setting¹⁰.

This material has been extensively studied and researched and has gained enormous popularity. However, its complicated handling and slow setting kinetics are a concern. The enormous popularity of this innovative material and research in material science led to the development of other Calcium silicate based

materials. Biodentine with Active Biosilicate Technology was announced by dental materials manufacturer Septodont developed by Septodont research group in September of 2010, and made available in January of 2011¹². According to the research and development department of said manufacturer, “a new class of dental material which could conciliate high mechanical properties with excellent biocompatibility, as well as bioactive behaviour” Septodont Biodentine TM scientific file, 2010 had been produced. According to the manufacturer, the material can be used as a “dentine replacement material whenever original dentine is damaged.”

Biodentine is used for crown and root dentin repair treatment, repair of perforations or resorptions, apexification and root-end fillings. Bio dentine powder is mainly composed of tricalcium silicate, calcium carbonate and zirconium oxide as the radio-pacifier. The liquid contains calcium chloride as the setting accelerator and water-reducing agent¹³. Biodentine shows apatite formation after immersion in phosphate solution¹² indicative of its bioactivity.

Additionally, Biodentine is insoluble in saliva and is able to withstand pressure of 400 gm mm⁻² within 6 minutes of setting, which makes it ideal for single visit apexification procedure.^{12,14} However according to study conducted by Sulthan IR hard tissue healing that is closely affected by alkaline pH and calcium ion release of materials was found to be similar for both Biodentine and MTA when used as a root end filling material.¹⁵

This article emphasizes the novel approach of using Biodentine to achieve single visit apexification of the cases with an open apex and large periapical lesion. The use of Biodentine has been demonstrated to induce periapical healing for single visit apexification of the cases.

Conclusion

The results demonstrated in the cases presented in this report are encouraging Biodentine seems to be a promising material for apexification although long-term clinical studies need to be done for the further validation of the predictability regarding use of this material.

References

1. Khetarpal A, Chaudhary S, Talwar S, Ravi R. Revascularization of immature permanent tooth with periapical lesion using a new biomaterial-a case report. *Int J Dent Sci Research* 2013;1(1):20-21.
2. Rafter M. Apexification: a review. *Dent Traumatol* 2005;21(1):1-8.
3. Andreasen JO, Andreasen FM. Textbook and color atlas of traumatic injuries to the teeth, 3rd edn. Copenhagen: Munksgaard;1994.
4. Pawar A.M, Kokate S.R, Pawar M.G, Hegde V.R. Apexification of non-vital central incisors with wide open apices using conventional approach of calcium hydroxide

- dressings and contemporary approach of artificial apical barrier by apical plug of biodentine: report of two cases. *Univ Res J Dent* 2013;3(2):79-82.
5. Nosrat A, Asgary S, Eghbal M J, Ghodduji J. Calcium – enriched mixture cement as artificial apical barrier: a case series. *J Conserv Dent* 2011;14(4):427-31.
6. Andreasen J, Farik B, Munksgaard E. Long-term calcium hydroxide as root canal dressing may increase risk of root fracture. *Dent Traumatol* 2002;18(3):134-7.
7. Bachoo I.K, Seymour D, Brunton P. Clinical case reports using a novel calcium-based cement. *Br Dent J* 2013;214(2):61-64.
8. Saunders WP, Saunders EM. Coronal leakage as a cause of failure in root canal therapy: a review. *Endod Dent Traumatol* 1994;10(3):105-108.
9. Torabinejad M, Pitt Ford T, Mckendry D, Abedi H, Miller D. Histologic assessment of mineral trioxide aggregate as a root-end filling in monkeys. *J Endod* 1997;23(4):225-8.
10. Fridland M, Rosado R. MTA solubility: a long term study. *J Endod* 2005;31(5):376-379.
11. MeenaKumari C, Takkar H, Nigam N, Punia SK. Mineral trioxide aggregate used as apical plug in open apex cases-a review and a case report. *Ind J Dent Sci* 2011;4(3):15-17.
12. Septodont Biodentine Active Biosilicate Technology SCIENTIFIC file; 2010. Available from: [http://www.septodont.fr/fichiers_upload/biodentinescientificfile .pdf](http://www.septodont.fr/fichiers_upload/biodentinescientificfile.pdf).
13. Laurent P, Camps J, De MM, Dejou J, About I. Induction of specific cell responses to a Ca3SiO5-based posterior restorative material. *Dent Mater* 2008;24(11):1486-94.
14. Sinha N, Singh B, Patil. Cone beam-computed topographic evaluation of a central incisor with an open apex and a failed root canal treatment using one-step apexification with Biodentine: a case report. *J Conserv Dent* 2014;17(3):285-88.
15. Khan SIR, Ramchandran A, Deepalakshmi M, Kumarapan SK. Evaluation of pH and calcium ion release of mineral trioxide aggregate and a new root-end filling material. *E J Dent* 2012;2(2):166-9.

How to cite article:

Dube K, Shukla S, Paul B, Kapur C. Apexification of non-vital central incisors with wide open apices using biodentine for inducing artificial apical plug. *Ind J Conserv Dent* 2016;1(1):32-36