

Reattachment of the coronal fragment: The biological restoration

Ruchet Purba¹, Snehal Sonarkar^{2,*}

¹Senior Lecturer, SV Dental College, Bengaluru, Karnataka, ²Senior Lecturer, Dept. of Conservative Dentistry & Endodontics, VSPM's Dental College & Research Centre, Nagpur, Maharashtra

***Corresponding Author:**

Email: snehalsonarkar@gmail.com

Abstract

Fracture of anterior tooth occurs frequently in dentistry. Tooth reconstruction can be done by fragment reattachment and this procedure is known as "Biological Restoration." Advances in restorative materials, placement techniques and preparation design help the clinician to restore fractured teeth. Using minimal invasive approach treatment of the maxillary anterior region can be completed effortlessly within a single appointment. This case report describes the successful outcome of a coronal tooth fracture that was treated using fibre posts for fragment reattachment.

Clinical Significance: Fragment reattachment of the tooth which is recently traumatized has many clinical significance.

1. Restores tooth function
2. Helps in achieving the esthetics
3. Conservative approach
4. Less time consuming when compared to other techniques of restoration like composite build up and ceramic restoration.
5. It is a cost effective treatment procedure

Keywords: Biological Restoration, Crown Lengthening, Diode Laser, Reattachment.

Introduction

Fractures are most commonly seen in children and adolescent affecting primary and permanent dentition. Maxillary anteriors are the most commonly fractured teeth with central incisors having highest incidence.¹⁻³ There are several factors that influence management of fractured coronal fragment such as biologic width, pulpal involvement, alveolar bone fracture, restorability of fractured tooth, trauma to soft tissue, presence or absence of fractured fragment and its approximation, occlusion, esthetics, finances, and prognosis.⁴⁻⁶

Thus, both soft and hard tissues surrounding the teeth should be considered while managing fractured tooth fragment thereby achieving favourable prognosis. The treatment options are divided into conservative approach (orthodontic band, pin retained restoration, reattachment) and invasive procedures (inlays, onlays, full coverage crowns, post and core).⁷ Amongst all these procedures, fragment reattachment is considered as the most conservative approach. This technique of natural tooth fragment reattachment is known as "Biologic restoration," and was first done by Chosack and Eidelman in 1964.⁸

Over the decades, dentistry has advanced in terms of materials and treatment techniques. Till date none of the restorative material has similar property as of the natural tooth.⁹⁻¹¹ Numerous authors have suggested the use of natural fractured tooth fragments as an efficient method for restoring tooth.^{9,12-21} When the patient presents fragment in the good condition, optimal results could be achieved (autogenous bonding).^{8,14,15} The use of fractured tooth fragments, adhesives, and restorative materials provide a good functional and esthetic result.

The following article describes two clinical cases of "Biological Restoration" using fibre glass.

Case Report

Case 1: A 18 year old boy was referred to the Department of Conservative Dentistry and Endodontics, with a chief complaint of crown fracture in right maxillary central incisor due to a fall. Clinical examination revealed the horizontal fracture with tooth 11 and there was pulpal exposure. (Fig. 1A) A diagnosis of Ellis class 3 fracture was made. Further, clinical examination also revealed the extension of fracture line from labial to lingual in an apical direction. The fractured coronal fragment was stored in saline to prevent dehydration. (Fig. 1B & 1C) Immediate root canal therapy was carried out on the two teeth. (Fig. 1D). Because the fracture line was above the bony crest, crown lengthening using laser was carried out to reach the edges of the root surface on the palatal side (Fig. 1E & 1F). Post space was made on the two teeth with corresponding drills to receive light transmitting post [Re for post Glass Fibre] (Fig. 1G). The prefabricated fibre post was checked in the canal for adaptation. After isolation, root canal walls were etched with 35% phosphoric acid for 20 seconds, rinsed and dried with paper points. Bonding agent [ADPER Single Bond2, 3M ESPE] was then applied to the root canal walls with a micro brush in two coats and gently air dried followed by light curing for 15 seconds. Bonding agent was also applied to the light transmitting post. The root canal was then coated with a flowable composite [FILTEK Z-350, 3M ESPE] and was also applied on as a thin layer on the post. The post was then seated and polymerization was done. (Fig. 1H & 1I)

The posts were cut 2mm outside the canal orifice. The pulp chamber and the fitting surface were similarly etched and primed in the fragments. The fractured tooth fragment was then verified for a fit with the tooth to ensure proper adaptation. Flowable composite was then applied to the pulp chamber area and the fragments were aligned to have a proper fit. The excess cement was removed and polymerization was done from all the sides of tooth. A groove was made on the line of reattachment and filled with microhybrid composite [FILTEK SUPREME, 3M ESPE], finished and polished. (Fig. 1J) Finally a fibre splint was used to splint teeth from 21 to 12 to improve the support and prognosis of the concerned tooth. (Fig. 1K)

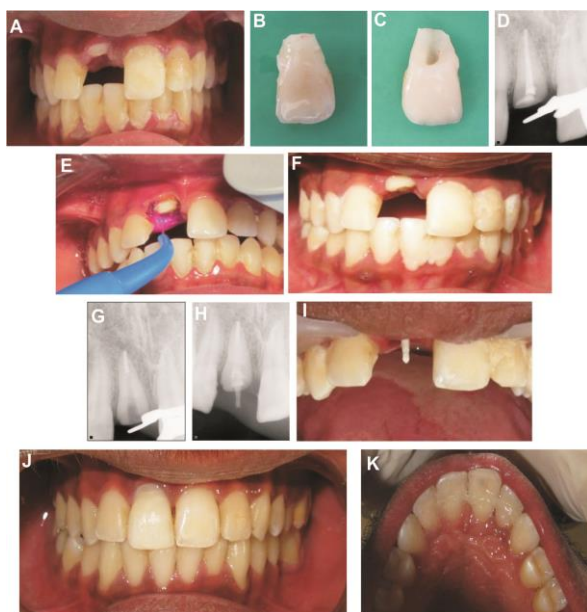


Fig. 1: Pictographic description for case no 1. A- Initial clinical presentation of fractured right maxillary central incisor, B-labial aspect of Tooth Fragment, C-Palatal aspect of Tooth Fragment, D-Radiograph after endodontic therapy, E-Crown Lengthening procedure using Diode Laser, F-Recall after 4 days, G-Post space preparation, H- Post cementation Radiograph, I-Clinical view of post fitting and cementation, J-Cementation of tooth fragment using dual cure cement and after finishing and polishing, K-Palatal view after finishing and polishing

Case 2: A 30 year old male reported to the department with the history of mobile teeth as a result of fall 2 days back. The patient complaint of pain and mobility of the front teeth on eating food and there was no other significant history. Intraoral clinical examination revealed an Ellis class-3 fracture with tooth 21 running in an oblique direction from labial to palatal side (Fig. 2A & 2B). Local anesthesia was administered and the extent of fracture line was evaluated again. The fractured tooth fragment was attached palatally to the

tissues so the tooth fragment was not removed. Single visit root canal therapy was done with 21. (Fig. 2C) Small groove was prepared on the fractured line such that it involves both the tooth and fractured fragment. The tooth surface and fractured fragment were etched with 37% phosphoric acid for 20 seconds, rinsed. Bonding agent [ADPER Single Bond 2, 3M ESPE] was then applied and cured. Subsequently flowable composite [FILTEK Z-350, 3M ESPE] was used to fill the access cavity in the tooth and the prepared grooves into the coronal fragment. Ensuring the complete fit of the fragment on the tooth structure it was light cured after making it stable by applying finger pressure such that it is in close adaptation with the tooth structure. The fragment was carefully seated on the remaining tooth and light cured. During curing firm and stable finger pressure was applied to the coronal fragment to closely oppose to the tooth. Ensuring the close adaptation of the tooth and the fragment, curing was done for 20 sec each from all the sides. After complete curing the restoration was finished and polished (Super-Snap, Shofu INC., Kyoto, Japan). Then the occlusion was evaluated. (Fig. 2D)

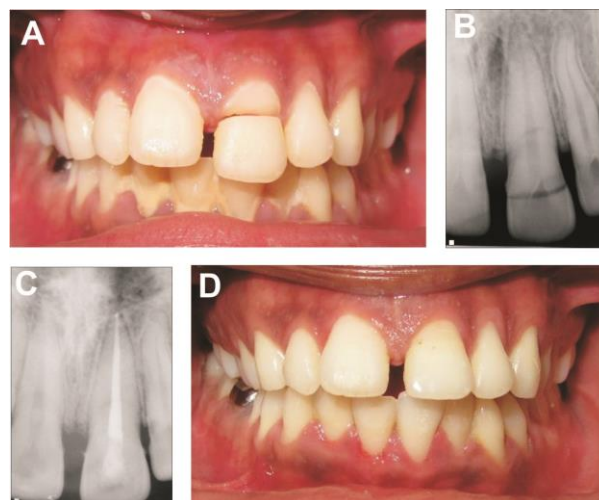


Fig. 2: Pictographic description for case no 2. A- Initial clinical presentation of fractured maxillary left central incisor, B-Radiograph with left central incisor showing horizontal radiolucent line in the cervical third, C-Radiograph after completion of endodontic therapy, D-Cementation of fractured fragment after finishing and polishing

Discussion

Reattachment of natural fragment is the most conservative approach in management of fractured tooth. Complete evaluation of coronal, occlusal and periodontal status helps in planning the reattachment procedure.²² Further, it helps in eliminating unmatched shades, difficulty in contouring and texture reproduction and lastly its differential wear. It was reported that the prognosis for reattached crown fragment was better than composite resin restoration.²³

There are many factors which influence the longevity and outcome of the treatment performed. These factors are extension of the fracture line, approximation between the fractured fragments and the tooth and lastly the need of endodontic therapy. In case 1, crown lengthening was done so as to achieve biologic width for maintaining periodontal health. However, in the second case there was no need for crown lengthening procedure.

The challenge for restorative dentistry is when the tooth is extensively damaged. Such teeth shall be restored using intracanal retention (by post) aiming retention of tooth fragment. The use of tooth colored fiber posts have several advantages such as they have similar modulus of elasticity as of dentin, less chance of fracture, bonds to the dentin and are more esthetic. The use of fiber post with composite core forms monobloc effect that further reinforces the tooth.²⁴

In both the cases, fractured fragment was restored using dual cure resin cement, fibre reinforced post and original crown fragment thus providing reinforcement to the restored segment, increased durability and survival. 25 High success rate of about 90% have been stated when the periodontal status and color was followed up for about 24 months.¹⁴

Conclusion

Reattachment is a conservative approach for restoring tooth. It helps in restoring the function and esthetic of the tooth. With the use of appropriate restorative materials and technique, good esthetic results can be achieved.

Bibliography

- Shulman JD, Peterson J. The association between incisor trauma and occlusal characteristics in individuals 8–50 years of age. *Dent Traumatol* 2004;20(2):67-74.
- Caliskan MK, Turkun M. Clinical investigation of traumatic injuries of permanent incisors in Izmir, Turkey. *Endod Dent Traumatol* 1995;11(5):210-3.
- Shayegan A, De Maertelaer V, Abbeele AV. The prevalence of traumatic dental injuries: A 24-month survey. *J Dent Child* 2007;74(3):194-9.
- Olsburgh S, Jacoby T, Krejci I. Crown fractures in the permanent dentition: pulpal and restorative considerations. *Dent Traumatol* 2002;18(3):103–15.
- Reis A, Franci C, Loguercio AD, Carrilho MR, Rodrigues Filho LE. Re-attachment of anterior fractured teeth: fracture strength using different techniques. *Oper Dent* 2001;26(3):287–94.
- Andreasen FM, Norén JG, Andreasen JO, Engelhardt S, Lindh-Strömberg U. Long term survival of fragment bonding in the treatment of fractured crowns. *Quintessence Int* 1995;26(10):669–81.
- Badami AA, Dunne SM, Scheer B. An *in vitro* investigation into the shear bond strengths of two dentine-bonding agents used in the reattachment of incisal edge fragments. *Dent Traumatol* 1995;11(3):129-35.
- Chosack A, Eidelman E. Rehabilitation of fractured incisor using the patients natural crown. *Case Report. J Dent Child.* 1964;31(1):19-21.
- Busato AL, Loguercio AD, Barbosa AN, Sanseverino Mdo C, Macedo RP, Baldissera RA. Biological restorations using tooth fragments. *Am J Dent* 1998;11(1):46–9.
- Galindo VAC, Nogueira JSE, Yamasaki E, Kós Miranda D. Biological posts and natural crowns bonding—alternatives for anterior primary teeth restoration. *J Bras Odontoped Odontol Bebe* 2000;16(7):513–20.
- Kaizer OB, Bonfante G, Pereira Filho LD, et al. Utilization of biological posts to reconstruct weakened roots. *Rev Gaucha Odontol* 2008;56(1):7–13.
- Aguiar KCFM, Nascimento TN, Corona SAM, Dibb RGP. Homogeneous bonding, alternative technique for anterior teeth fracture. *Rev Gaucha Odontol* 2000;48(2):153–4.
- Tavano KT, Botelho AM, Motta TP, Paes TM. Biological restoration: total crown anterior. *Dent Traumatol* 2009;25(5):535–40.
- Gabrielli F, Dinelli W, Fontana UF, Porto CLA. A presentation and clinical assessment of a restoration technique in anterior teeth, with adapted extracted teeth fragments. *Rev Gaucha Odontol* 1981;29(1):83–7 (in Portuguese).
- Yilmaz Y, Zehir C, Eyboglu O, Belduz N. Evaluation of success in the reattachment of coronal fractures. *Dent Traumatol* 2008;24(2):151–8.
- Demarco FF, Moura FRR, Tarquinio SBC, Lima FG. Reattachment using a fragment from an extracted tooth to treat complicated coronal fracture—case report. *Dent Traumatol* 2008;24(2):257–61.
- Nogueira Filho Gda R, Machion L, Teixeira FB, Pimenta LA, Sallum EA. Reattachment of an autogenous tooth fragment in a fracture with biologic width violation: a case report. *Quintessence Int* 202;33(3):181–4.
- Busato ALS, Antunes M. Heterogeneous bonding in anterior fractured teeth. *Rev Gaucha Odontol* 1984;32(2):137–40 (in Portuguese).
- Oz IA, Haytaç MC, Toroglu MS. Multi-disciplinary approach to the rehabilitation of a crown-root fracture with original fragment for immediate esthetics: a case report with 4-year follow-up. *Dent Traumatol* 2006;22(1):48–52.
- Reis A, Loguercio AD, Kraul A, Matson E. Reattachment of fractured teeth: a review of literature regarding techniques and materials. *Oper Dent* 2004;29(2):226–33.
- Baratieri LN, Ritter AV, Monteiro Junior S, de Mello Filho JC. Tooth fragment reattachment: an alternative for restoration of fractured anterior teeth. *Pract Periodontics Aesthet Dent* 1998;10(1):115–25.
- Maitin N, Maitin SN, Rastogi K, Bhushan R. Fracture tooth fragment reattachment. *BMJ Case Rep* 2013. 1-7. doi:10.1136/bcr-2013-009183. Accessed from the site <https://www.ncbi.nlm.nih.gov/pubmed>. on 24 October 2016.
- Cavalleri G, Zerman N. Traumatic crown fractures in permanent incisors with immature roots: a follow-up study. *Endod Dent Traumatol* 1995;11(6):294–6.
- Tay FR, Pashley DH. Monoblocks in root canals: A hypothetical or tangible goal. *J Endod* 2007;33(4):391-8.
- Vitale MC, Caprioglio C, Martignone A, Marchesi U, Botticelli AR. Combined technique with polyethylene fibers and composite resins in restoration of traumatized anterior teeth. *Dent Traumatol* 2004;20(3):172–7.

How to cite this article:

Purba R, Sonarkar S. Reattachment of the coronal fragment: The biological restoration. *Ind J Conserv Endod* 2016;1(2):52-54.