

Case report on Gingival enlargement along with Amelogenesis Imperfecta a rare clinical entity in children

Neha Bhadoria^{1,*}, Pallavi Singh², Mohit Gunwal³

¹Senior Lecturer, Dept. of Pedodontics, ²Senior Lecturer, Dept. of Periodontics, ³Reader, Dept. of Endodontics, Index Institute of Dental Sciences, Indore, Madhya Pradesh,

***Corresponding Author:**

Email: bhadorianeha01@gmail.com

Abstract

Increase in size of gingiva is a common finding of gingival enlargement. It is characterized by evident growth of gingiva vertically towards incisal edge of clinical crown and horizontally towards buccolingual area and has increased prevalence on buccal surface of anterior teeth. Amelogenesis imperfecta consists of group of condition genetic in origin and affects the structure and clinical appearance of all enamel and all most all the teeth in more or less equal manner and it might be related to morphological or biochemical changes in body. It can be in isolated form or associated with other abnormalities as in syndrome. It can be autosomal dominant, autosomal recessive, sex linked and sporadic inheritance pattern. In X linked form it may result from mutation in Amelogenin gene, AMELX. Autosomal recessive reports in families with consanguinity.

Introduction

Increase in size of gingiva is a common feature of gingival disease. It is characterized by evident growth of gingiva vertically towards incisal edge of clinical crown and horizontally towards buccolingual area and has increased prevalence on buccal surface of anterior teeth.¹

Aetiology and pathogenesis of gingival hyperplasia is not well established it can be linked to 2 factors i) individual susceptibility ii) local factors (dental plaque). The most common type is plaque induced. Inflammation occurs due to presence of local irritants such as compromised oral condition, due to calculus and mouth breathing. It occurs due to alteration in host tissue response to plaque accumulation.² Such condition can be enhanced by hormones in puberty or pregnancy and also may be exaggerated by certain systemic condition. Also it may cause interference with speech or mastication and results in halitosis, looking unsightly.³

Amelogenesis imperfecta represents a group of condition genomic in origin which affects the structure and clinical appearance of enamel of all or nearly all the teeth in more or less equal manner.⁴ This can exist in isolation or associated with other abnormalities in syndrome. It may show autosomal dominant, autosomal recessive, sex linked and sporadic inheritance pattern. In X linked form it may result from mutation in Amelogenin gene, AMELX. Autosomal recessive reports in families with consanguinity. Diagnosis is based on family history, pedigree plotting and meticulous clinical observation.⁵

Case Report

14 year old female child reported to the Department of Pedodontics in Index Institute of Dental Sciences with chief complaint of discoloration of teeth and bleeding gums, since 6 months. Due to her swollen

gums she had improper speech, difficulty in eating, incompetent lips and hindered aesthetics. Her oral hygiene habit includes brushing once a day using a medium brush with horizontal technique. There was no history of drug intake, fever, weight loss, seizures, nor did the patient give any history of physical or mental disorder. Also familial, prenatal and postnatal history was non-significant. Her sibling also had discoloured malformed teeth.

Examination: Extra-oral examination reveals that the patient has convex profile and lips are everted and incompetent. An intraoral examination shows generalized, diffused edematous enlargement of the gingiva involving all the teeth. Bleeding on probing was evident. Surface was smooth, distended, stippling was lost and pitting was evident. Patient had grade III gingival enlargement with pseudo pockets of depth 5-6mm.

On hard tissue examination child had discoloured, malformed teeth, yellowish brown in colour which were prone to disintegrate. All teeth had yellowish brown in colour. Sensitivity was present, with several retained primary teeth, occlusal surface of molar was worn off and oral hygiene was very poor.

Investigations: Orthopantomogram revealed several retained primary teeth. Mandibular left canine was horizontally impacted. Radiographically enamel and dentine was distinguishable with no pulp involvement. Radiographs exhibited a thin outline of radio dense enamel, and low or even absent cusps. Clinical and radiographic appearances of the teeth of our case were harmonious with rough pattern hypoplastic teeth.

Diagnosis: It was diagnosed as Plaque Induced inflammatory type of gingival enlargement and Amelogenesis imperfecta hypoplastic type.

Treatment:The objectives of treatment were to conserve the tooth structure, increase the lost vertical dimension to a comfortable position (physiologic neuromuscular position), to restore masticatory function and improve aesthetics. The treatment was planned in three phases.

Phase 1 Periodontal Therapy: After completion of Phase I therapy, a quadrant-wise periodontal surgery was performed along with systemic antibiotic therapy using techniques. In first quadrant, ledge and wedge technique was done followed by external bevel gingivectomy in second quadrant. Kirkland knives were used for incisions. An Urban periodontal knife was used for interdental incisions. After one month gingival contouring was performed. After the final step, the patient was advised to maintain good oral hygiene and regular check-up once in 6 months.

An Incisional Biopsy was done. Report shows presence of parakeratinized stratified squamous epithelium. Underlying connective tissue stroma is dense fibrocellular interspersed with fibroblast. Dense patchy chronic inflammatory infiltrate mainly consisting of lymphocytes and plasma cells were seen. The tissue is adequately vascular. All these features gave a diagnosis of inflammatory gingival enlargement.

In **Phase 2** considering the loss of dental tissues of posterior teeth, it necessary to place stainless steel crown(3M/ESPE) to restore occlusion and occlusal vertical dimension of the child. Preformed Stainless steel crown were given on permanent first molar's following minimal tooth preparation of teeth.

In **Phase 3** to improve aesthetics and to establish anterior tooth function acrylic crowns were given on anterior teeth as a part of temporization. As there was insufficient tooth structure and further reduction of tooth would lead to pulpal exposure. This will be later replaced by Porcelain Fused to Metal crown once the growth spurt is completed. Occlusal surface of premolars and 2 permanent molar were restored. Oral hygiene instructions were given and the patient was recalled after 1 month for follow up. After a follow up of 6 months the patient was satisfied with both function and aesthetics.

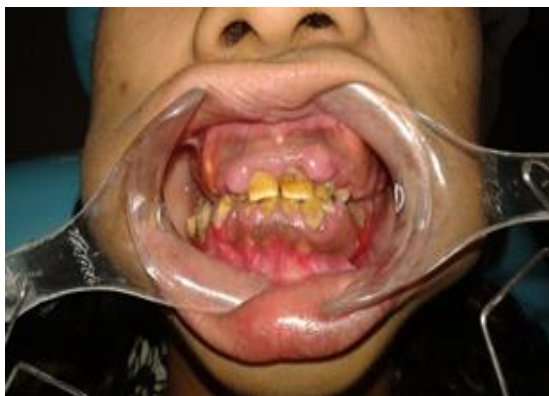

Fig. 1: Extra oral Preoperative photograph

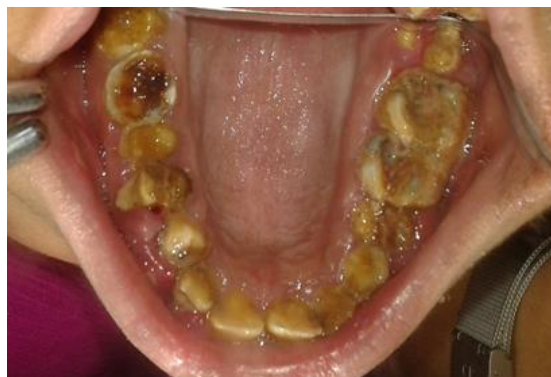

Fig. 2: Preoperative Intraoral photograph of maxillary arch

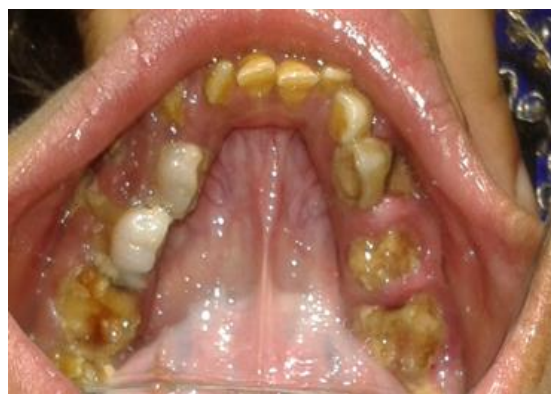

Fig. 3: Preoperative Intraoral photograph of mandibular arch

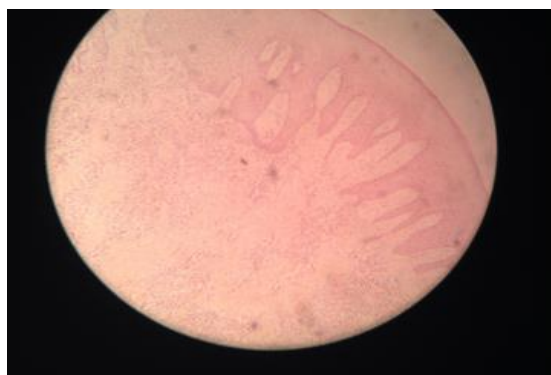


Fig. 4: Histopathologic image depicting connective tissue stroma which is dense fibro cellular. Dense patchy chronic inflammatory infiltrate predominated in lesion

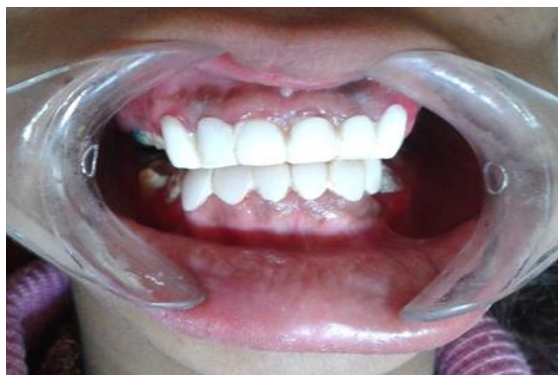

Fig. 5: Extraoral postoperative photograph after prosthetic rehabilitation

Discussion

There are a number of treatment options available for teeth affected by AI. The treatment of patients with AI represents as challenge to dentist. The main features are loss of tooth structure, hindered esthetics and tooth ache. The treatment plan differs and depends upon—age, financial status, and severity of the disease and intraoral tissue.⁵

In the present case there was no systemic involvement. Studies have shown the prevalence of Amelogenesis imperfecta to be 1:700 to 1:14000 depending on the population examined. It can be autosomal dominant, autosomal recessive or X-linked mainly it is of three types first is hypoplastic (60 to 70%), then is hypomaturation type (20 to 40%), and last is hypocalcification type (7%). A multidisciplinary approach is required to evaluate, diagnose, and resolve the condition.⁶

The main etiological factor for inflammatory hyperplasia is prolonged exposure to dental plaque, calculus and factor that favour plaque accumulation and retention which include poor oral hygiene, structural anomaly and faulty restoration.⁷ In present case report the constant increase in gingival mass has resulted in delayed eruption and displacement of teeth, arch deformity, spacing, migration of teeth, eversion of lip, and retained deciduous teeth. As a result child develops abnormal swallowing pattern, speech problem and difficulty in mastication.⁸

In this case as the patient was suffering from Amelogenesis imperfecta this condition affects food excursion, result in accumulation of food debris and plaque comprising of periodontopathic bacteria which prolong and aggravates this condition. Usually in such cases the patient might undergo repeated gingivectomy procedures. This further aggravates child and parents' tension. Therefore, counseling is mandatory for patients and parents.

In this case after phase I periodontal therapy as the tissue had significant fibrotic component it doesn't resolved completely so surgical removal of tissue was the treatment of choice so flap surgery was done.⁸

Full coverage restoration is desirable for posterior teeth due to the extensive loss of enamel and to prevent further loss of tooth structure. Full coverage adhesive composite crowns or polycarbonate crowns are also used but good hygiene has to be maintained because of the plaque retentive nature of the these materials and passive eruption can expose defective enamel.⁹

In this SSC were given as they are extremely durable, relatively cheap, subject to minimal technique sensitivity during placement and offers advantage of full coverage restoration. Scott H Rosenblum treated a 13-year-old patient with full coverage stainless steel crowns on the molars with resulted in an increase in vertical dimension and for anterior because of aesthetics used stainless steel crowns with veneer phasing.¹⁰

As the premolars and second permanent molars were in state of active eruption so crown were not placed, but the occlusal surface were restored. According to patient after periodontal therapy and restorative procedure were over patients dental hypersensitivity disappeared completely, chewing function increased and aesthetics improved this was strong motivation to improve her confidence and level of cooperation during treatment. In final phase acrylic crowns were placed on anterior teeth to restore aesthetics.

Also in this case the aesthetics and profile of patient was severely compromised, treatment required by such patient is substantial in terms of clinical and psychologically. This condition presents problems in socialization. Form and function are compromised but can be treated both preventively as well restoratively, with the treatment continued throughout transition from childhood into adult.¹¹

Conclusion

Amelogenesis imperfecta with inflammatory gingival enlargement presents as rare dental disorder with complex management protocol and multidisciplinary approaches. The doctor should use appropriate measure for treatment of this condition. Local factors such as plaque and calculus are main reason behind gingival enlargement and in this case presence of Amelogenesis imperfecta further exaggerated this condition. Therefore importance of regular check-up and maintenance of good oral hygiene should be emphasized. The treatment of such cases should start as early as possible. This case report represents the functional and esthetic rehabilitation of AI with inflammatory gingival enlargement.

References

1. Miranda J, Brunet L, Roset P, Farré M, Mendieta C. Reliability of two measurement indices for gingival enlargement. *J Periodontol Res.* 2012;47(6):776-82.
2. Ramer M, Marrone J, Stahl B, Burakoff R. Hereditary gingival fibromatosis: Identification, treatment, control. *J Am Dent Assoc* 1996;127(4):493-5.

3. Pandit IK, Pandit N. Non-specific inflammatory gingival enlargement--a case report. *J Indian Soc Pedod Prev Dent.* 2000;18(1):21-3.
4. Dhaval N. Mehta, Jigna Shah, and Bhavik Thakkar Amelogenesis imperfecta: Four case reports. *J Nat Sci Biol Med.* 2013;4(2):462-465.
5. Crawford PJ, Aldred M, Bloch-Zupan A. Amelogenesis imperfecta. *Orphanet J Rare Dis.* 2007 Apr 4;2:17.
6. Wright J. The diagnosis and treatment of dentinogenesis imperfect and amelogenesis imperfecta. *Hellenic Dent J* 1993;2:17-24.
7. Carranza Textbook of clinical periodontology 9 edition page 373-378.
8. Pandit IK1, Pandit N Non-specific inflammatory gingival enlargement--a case report. *J Indian Soc Pedod Prev Dent.* 2000;18(1):21-3.
9. Bouvier D, Duprez JP, Bois D. Rehabilitation of two patients with amelogenesis imperfecta: A report of two cases. *ASDC J of Dent Child* 1996;63(6):443-47.
10. Rosenblum SH. Restorative and orthodontic treatment of an adolescent patient with amelogenesis imperfecta. *Pediatr Dent* 1999;21(4):289-92.
11. Wright JT, Robinson C, Shore R. Characterization of the enamel ultrastructure and mineral content in hypoplastic Amelogenesis imperfecta. *Oral Surg Oral Med Oral Pathol* 1991;72:594-601.

How to cite this article:

Bhadoria N, Singh P, Gunwal M. Case report on Gingival enlargement along with Amelogenesis Imperfecta a rare clinical entity in children. *Ind J Conserv Endod*, 2016;1(2):61-64.