

Endodontic management of a hidden middle distal canal in mandibular first molar with post-operative CBCT-a case report

Shaik Izaz^{1,*}, Bolla Nagesh², CH B. Sunil³, Bhargavi Dasari⁴

¹PG Student, ²HOD, ³Professor, ⁴MDS, Sibar Dental College, Guntur, Andhra Pradesh

***Corresponding Author:**

Email: shaik.ajas@gmail.com

Abstract

The main objective of root canal treatment is thorough mechanical and chemical cleansing of the entire pulp space and to provide an intact hermetic seal. A 30 year-old female patient was referred to the Department of Conservative Dentistry and Endodontic with a chief complaint of acute pain in her right lower back tooth. From the clinical and radiographic findings, a diagnosis of symptomatic irreversible pulpitis with symptomatic apical periodontitis was made for tooth 46, and root canal treatment was scheduled. Access cavity, radiographs revealed 5 canals: mesiobuccal, mesiolingual, distobuccal, middle distal, distolingual. Obutartion was done with warm vertical compaction technique using AH-Plus sealer. To be able to precisely detect, search, and decontaminate root canal system, cone-beam computed tomography can be used to aid in diagnosis of root canal morphology. Treating extra canals may be challenging but the inefficiency to find and properly treat root canals may cause failures.

Keywords: Anatomy, CBCT, Mandibular molar, Middle distal.

Introduction

The self-named success or the failure bankon with four main marks that includes awareness about the root canal anatomy and morphology of the entire root canal system, chemical cleansing & disinfection, 3 dimensional obturation and a sound restoration.¹ Various areas of odontology have anatomically complex and highly variable canal configuration and mandibular first molars which normally have one mesial and one distal root with two mesial and one or two distal canals.² Vertucci (1984) was first to propose a standardized method for categorizing root canal anatomical variations, later Weine (2004) described a more clinically relevant classification of the root canal anatomy. Abounding classification do exists in the literature with different canal configurations.^{3,4} The incidence of five canals in the mandibular first molar has been reported which ranges from 1%-15% whereas the incidence of three distal canals has been diminished to 0.6 %.^{5,6} According to Vertucci, before root canal treatment, it is must to emphasis on the importance to visualise and knowledge of internal anatomy relationships. Hence, careful evaluation of two or more peri-apical radiographs with opposed cone angles with respect to target tooth before commencing the root canal therapy to adequately reveal the morphologic characteristic of root canal system.⁷ Cone Beam Computed Tomography (CBCT) has been recommended for the accurate evaluation of root canal systems. Neelakantan et al. (2010) reported that CBCT has the ability to detect the root canal system as accurately as canal staining and clearing techniques, which was considered superior to many other techniques used to study the root canal systems.⁸ The purpose of the present article is to report the successful

non-surgical management of a three-rooted left permanent mandibular first molar having five root canals (three in distal root and two in mesial) having a Type XII (3-2) root canal pattern in the distal root (Gulabivala et al. 2001).⁹

Case Report

A 30 year-old female patient was referred to the Department of Conservative Dentistry and Endodontic with a chief complaint of acute pain in her right lower back tooth. On clinical examination, there was gross decay in the mandibular right first permanent molar (tooth 46) from the buccal surface, (Fig. 1A, 1B) which was tender to percussion. The patient's medical history was non-contributory. The tooth was not mobile and periodontal probing around the tooth was within physiological limits. Pulp sensibility testing of the involved tooth with dry ice (R C Ice; Prime Dental Products Pvt Ltd, Mumbai, India) caused an intense lingering pain whilst electric pulp stimulation (Ashoosons API Pulp Tester, Delhi, India) caused a delayed response. The preoperative diagnostic radiograph revealed an occlusal radiolucency, approaching the pulp space with periodontal ligament space widening and loss of lamina dura in relation to 46 (Fig. 1C). From the clinical and radiographic findings, a diagnosis of symptomatic irreversible pulpitis with symptomatic apical periodontitis was made for tooth 46, and root canal treatment was scheduled. Radiographic evaluation of the tooth indicated a normal root canal anatomy. Anaesthesia was achieved by means of inferior alveolar nerve block with 1.8 ml of 2% lignocaine with 1:80,000 adrenaline (Lignox, Indoco Remedies Ltd., India). Access cavity was prepared under rubber dam (Hygenic dental dam,

Coltene Whaldent, Switzerland) isolation in relation to 46. On examination with a DG-16 endodontic explorer (Hu-Friedy, USA), the pulp chamber had four canals (mesiobuccal, mesiolingual, distobuccal and distolingual). After scouting the root canals, flaring of the coronal thirds was performed with a Protaper SX& S1 rotary files (Dentsply, Maillefer)(Fig. 2C). The working length was determined using electronic apex locator (Propexpixi, Dentsply) and confirmed radiographically (Fig. 2A). During the initial working length radiograph a third distal canal was appreciated (Fig. 2A). Under 3.5X magnification (Seiler Instrument Inc, St. Louis, MO) access cavity was modified using long shaft round bur no-2 on the distal surface and third canal was located. Another working length radiograph (Fig. 2B, 2D) was established by #15H and K-files (Dentsply, Maillefer) and confirmed using an Apex locator (Propexpixi, Dentsply). Biomechanical

preparation was done using protaper rotary files (Dentsply, Maillefer) according to the manufacturer's instructions under abundant irrigation with 0.9% normal saline(Baxter India Pvt Ltd., Alathur, India), 5.25% sodium hypochlorite (Prime Dental Product, Mumbai, India) and 17% EDTA (Smear Clear, Kerr corporation Orange, CA) after the use of each instrument. Canals were then dried with absorbent points(Dentsply, Maillefer) and filled with warm vertical compaction technique using AH-Plus sealer (Dentsply, Maillefer) (Fig. 3A, 3B). Tooth was then restored with amalgam and post-operative peri-apical radiograph was obtained (Fig. 3C). A three-dimensional image of tooth 46 was obtained using CS 3D Imaging Software (Carestream Dental LLC - North America) confirming the obturation in all the five canals (Fig. 4A, 4B). Porcelain fused to metal crown was placed after 15days under asymptomatic conditions (Fig. 4C).

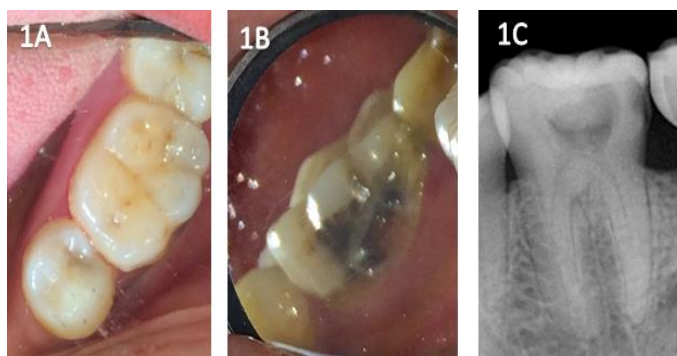


Fig. 1

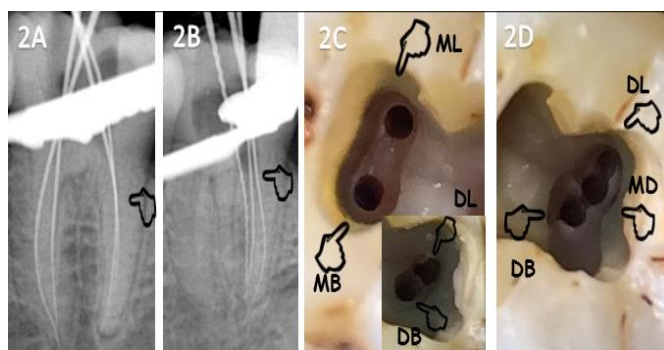


Fig. 2

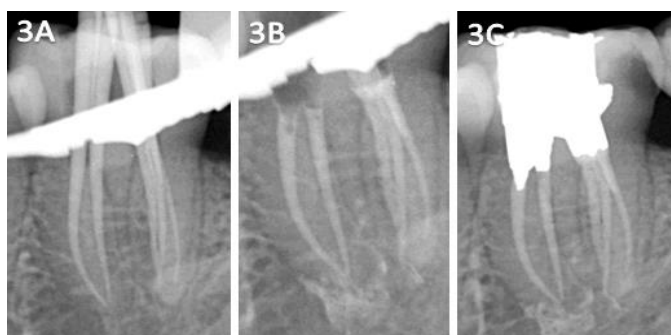

Fig. 3

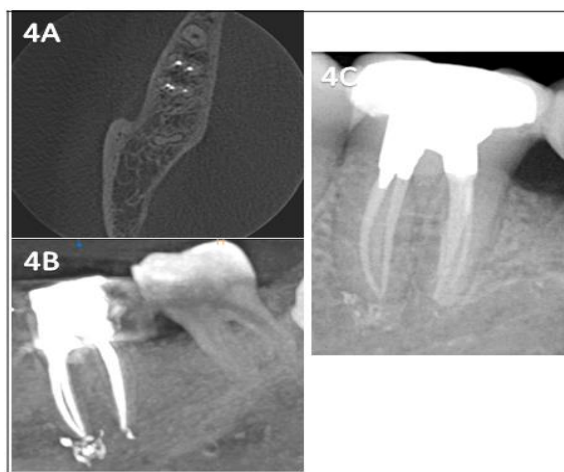


Fig. 4

Discussion

Human tooth morphology exists with complicated and diverse root canal system poses a challenge to successful diagnosis and treatment. Although literature suggests the presence of multiple canals in distal root.⁹⁻¹⁵ However, three canals in a distal root is a very rare occurrence. According to literature incidence of three canals in distal root of mandibular first molar in an Senegalese population is 0.2%; 0.7% in Burmese population; 1.6% in Thai population, 3% in Sudanese population; 1.7% in Turkish population and Indian population.¹⁶ It has been postulated that apposition of secondary dentin leads to dentinal vertical partitions inside the root canal cavity during the tooth maturation thus creating the canals. During this process extra third canal may be created inside the canal cavity. Similar extra canals are placed centrally between the buccal and lingual orifices and the third canal diameter i.e., middle canal is usually smaller than the existing two canals.¹⁷ This case demonstrates a rare anatomical configuration in mandibular first molars. In this case report, distal root has three distinct root canal orifices with single root, that could be described as Type XII canal configuration according to Gulabivala et al. 2001.⁹ Instrumentation is one of the key factors in the success of endodontic therapy and the clinician should be aware of the varied anatomy. An avid clinician should be always keen to explore the possibility of additional canals whenever in doubt, with the assistance of technologies such as those of magnification and illumination. In this case post-operative CBCT was advised to confirm the canal configuration and to sealing condensation of the root canal filling material within the root canal system. According to the guidelines of National council for Radiation Protection, the use of CBCT in endodontics has limited only to certain complicated conditions where conventional imaging has failed to work up. Conventional imaging lacks in identification of accessory canals with suspected complex morphologies. The information

which is recorded from the conventional and digital radiographs have limited values because it gives two dimensional image of a three dimensional object. Hence advanced three dimensional imaging like Cone Beam Computed Tomography has come in to existence, the major advantage of which is making the clinician to prospect the image in multiple slices of tooth roots so that the canal configuration is accurate. Various ex vivo, in-vivo studies have reported its advantages and importance over the conventional imaging to ascertain the canal morphology. However, CBCT scan is advocated only when aberrant anatomy is suspected based on the conventional radiographs and clinical examination for confirmatory diagnosis following the newer concept like ALADA (as low as diagnostically acceptable) which is a modification of ALARA (as low as reasonably achievable).¹⁸ A thorough understanding of tooth morphology (Burns & Herbranson 2002), angulated radiographs (Fava & Dummer 1997), CBCT (Robinson et al. 2002, Gopikrishna et al. 2006 and Sponchiado et al. 2006) where in three dimensional radiography was used for the confirmatory diagnosis of morphological aberrations in the root canal anatomy and exploring the root canal under the operating microscope (Rampado et al. 2004) are the fundamental prerequisites for a successful treatment outcome.¹⁹⁻²⁴

Conclusion

Factors which influence the success of root canal treatment include, thorough knowledge, about the varied canal anatomy, effective diagnosis with the help of newer diagnostic tools, sound knowledge and techniques about chemical cleansing, disinfection, obturation and use of higher magnification. The case presented shows a middle distal canal in mandibular molars is one such variation among the existing canal anatomy. The assumption about the fixed number of root canals is now obscure, so the boundness of the dentist to evaluate each case carefully both clinically

and radio-graphically would provide a better prognosis & longevity for endodontic therapy.

References

1. Malagnino V, Gallotini L, Passariello P. Some unusual clinical cases on root anatomy of permanent maxillary molar. *J Endod* 1997;23(2):127-8.
2. Bains R, Loomba K, Chandra A, Loomba A, Bains V. K, Garg A. The radix entomolaris: a case report. *ENDO2009*;3(1):121-25.
3. Vertucci FJ. Root canal anatomy of the human permanent teeth. *Oral Surg Oral Med. Oral Pathol*1984;58(5):589-99.
4. Weine FS. *Endodontic Therapy* (6th edn) MO: Mosby Publication, 2004, pp 37-52.
5. N. Adanir. "An unusual maxillary first molar with four roots and six canals: a case report." *Aust Dent J* 2007;52(4):333-5.
6. H. Fabra-Campos. "Unusual root anatomy of mandibular first molars." *J Endod*1985;11(12):568-72.
7. Martinez-Lozano MA, Forner-Navarro L, Snchez-Cortes JL. Analysis of radiologic factors in determining premolar root canal systems. *Oral Surg Oral Med Oral Pathol Oral Radiol Endod* 1999;88(6):719-22.
8. Neelakantan P, Subbarao C, Subbarao CV. Comparative evaluation of modified canal staining and clearing technique, cone-beam computed tomography, peripheral quantitative computed tomography, spiral computed tomography, and plain and contrast medium-enhanced digital radiography in studying root canal morphology. *J Endod* 2010;36(9):1547-51.
9. Gulabivala K, Aung TH, Alavi A, Ng YL. Root and canal morphology of Burmese mandibular molars. *IntEndod J* 2001;34(5): 359-70.
10. Stroner WF, Remeikis NA, Carr GB. Mandibular first molar with three distal canals. *Oral Surg Oral Med Oral Pathol* 1984;57(5):554-57.
11. Beatty RG, Interian CM. A mandibular first molar with five canals: Report of case. *J Am Dent Assoc* 1985;111(5):769-71.
12. Ghoddusi J, Naghavi N, Zareri M, Rohani E. Mandibular first molar with four distal canals. *J Endod* 2007;33(12):1481-83.
13. Sperber GH, Moreau JL. Study of the number of roots and canals in Senegalese first permanent mandibular molars. *IntEndod J* 1998;31(2):117-22.
14. Goel NK, Gill KS, Taneja JR. Study of root canals configuration in mandibular first permanent molar. *J Indian Soc Pedod Prev Dent* 1996;14(1):12-14.
15. Calikan MK, Pehlivan Y, Sepetçiođlu F, Türkün M, Tuncer SS. Root canal morphology of human permanent teeth in a Turkish population. *J Endod* 1995;21(4):200-04.
16. Kottoor J, Sudha R, Velmurugan N. Middle distal canal of the mandibular first molar: A case report and literature review. *Int Endod J*. 2010;43(8):714-22.
17. A. Martinez-Berna and P. Badanelli. "Mandibular first molars with six root canals." *J Endod* 1985;11(8):348-52.
18. Jaju PP, Jaju SP. Cone Beam computed tomography: Time to move from ALARA to ALADA. *Imaging Sci Dent*. 2015;45:263-5.
19. Burns RC, Herbranson EJ. Tooth morphology and access cavity preparation. In: Cohen S, Burns RC, editors. *Pathways of the pulp*. 8th ed. St. Louis, Missouri: Elsevier, Mosby; 2002. pp. 173-229.
20. Fava LR, Dummer PM. Periapical radiographic techniques during endodontic diagnosis and treatment. *IntEndod J* 1997;30(4): 250-61.
21. Gopikrishna V, Bhargavi N, Kandaswamy D. Endodontic management of a maxillary first molar with a single root and a single canal diagnosed with the aid of spiral CT: a case report. *J Endod* 2006;32(7):687-91.
22. Robinson S, Czerny C, Gahleitner A, Bernhart T, Kainberger FM. Dental CT evaluation of mandibular first premolar root configuration and canal variations. *Oral Surg Oral Med Oral Pathol Oral Radiol Endod* 2002;93(3):328-32.
23. Sponchiado EC Jr, Ismail HA, Braga MR, de Carvalho FK, Simoes CA. Maxillary central incisor with two root canals: a case report. *J Endod* 2006;32(10):1002-4.
24. Rampado ME, Tjaderhane L, Friedman S, Hamstra SJ. The benefit of the operating microscope for access cavity preparation by undergraduate students. *J Endod* 2004;30(12):863-7.

How to cite this article

Izaz S, Nagesh B, Sunil CHB, Dasari B. Endodontic management of a hidden middle distal canal in mandibular first molar with post-operative CBCT-a case report. *Ind J Conserv Endod* 2016;1(2):65-68.