

## Healing outcome of large peri-apical radicular cyst in maxillary canine region treated using mineral trioxide aggregate as an orthograde restorative material with 24 months of follow up - A case report

Shaik Izaz<sup>1,\*</sup>, Bhargavi Dasari<sup>2</sup>, Nagesh Bolla<sup>3</sup>, Deepthi Vundavalli<sup>4</sup>, Sowmya Kallepalli<sup>5</sup>

<sup>1,4</sup>PG Student, <sup>3</sup>HOD, Sibar Institute of Dental Sciences, <sup>5</sup>Dept. of Conservative Dentistry & Endodontics, MNR Dental College & Hospital, Andhra Pradesh, <sup>2</sup>Senior Lecturer, Dept. of Oral & Maxillofacial Radiology, KIMS Dental College, Andhra Pradesh

**\*Corresponding Author:**

Email: shaik.ajas@gmail.com

---

### Abstract

Mineral trioxide aggregate (MTA), is made up of hydrophilic fine particles that harden in the presence of dampness or blood. It constitutes the salts of tricalcium alluminate, tricalcium silicate and bismuth oxide, which makes it biocompatible and radiopaque when compared to classic materials for root filling such as amalgam, cements, Super-EBA, and IRM. Being an advantageous material it is beneficial to be used in most common peri-apical endodontic diseases. This case report centres the attention on the technical skills as well as on the healing ability of the most commonly used material. This article also discusses the amazing repair property of the material in the case.

**Keywords:** Biocompatibility, Maxillary canine, Mineral trioxide aggregate, Two visit endodontics, Open apex.

---

### Introduction

Bacterial infection of the pulp space and pulpal disease result in periapical lesions. These lesions are usually found during routine clinical check-up as sinus opening in the oral cavity or through radiographs. Peri-apical lesions are commonly classified as radicular cysts, dental granulomas or abscesses.<sup>(1)</sup> Among these lesions, the incidence rate of cyst ranges from 6% to 55%, the occurrence of granulomas varies from 9.3% to 87.1%, and for abscesses it spans from 28.7% to 70.07%. However clinical evident lesions which are larger in size, are most likely to be called as radicular cysts and the small size lesions are categorised under granulomas or abscesses.<sup>(2)</sup>

For such larger or the small lesion, the preliminary procedures is to perform endodontic treatment, specially cleaning and shaping, to eliminate the cause such as necrotic tissue and infective bacteria. Cleaning and shaping and disinfecting the canals in the apical thirds are usually not adequately performed, for such elimination of cause cannot be expected; therefore, complete obturation of the prepared, cleaned and shaped canal space is necessary. Proper obturation leads to descend the chances of coronal leakage and bacterial recontamination and also seals the apex from peri-apical tissue fluids.<sup>(3)</sup>

Based on the intrinsic properties and handling characteristics of obturation materials some of the very few are most commonly used for obturating the prepared coronal and radicular space. Parts of core materials have been classified as cements, pastes, plastics, or solid. These materials should exhibit certain characteristics to resolve and prevent endodontic failure. The ideal requirements of obturating materials are they should be bacteriostatic, seal apically and laterally, be non-irritating to peri-apical tissues, resist

moisture, and provide radiopacity. Furthermore, the material should be sterile, non-shrinking, non-staining, easily placed and removed from the root canal system. Most widely used obturating material among many is gutta-percha.<sup>(4)</sup> However multiple studies suggested that gutta-percha is highly susceptible to microleakage when coronal restoration is not provided. A few number of in-vitro studies using dye penetration, fluid filtration, or bacterial leakage models stated that gutta percha as an obturating materials showed vulnerability. Bacterial challenges to exposed gutta-percha with sealer in various in vitro experimental models have shown leakage along the material within 3–30 days.<sup>(5)</sup> In the literature no known methods with wide variety of techniques of cold lateral or warm vertical compaction of gutta-percha can predictably produce a coronal bacterial-tight seal when the material is exposed to microorganisms. Although gutta-percha has an added advantage of handling properties and biocompatibility. However the susceptibility of gutta-percha to contamination and microleakage has led to the recommendation that sealed coronal core materials is placed directly after the completion of orthograde root canal treatment when using gutta-percha.<sup>(6)</sup>

Mineral trioxide aggregate (MTA) might have a profound advantage when used as canal obturation material because of its superior physiochemical and bioactive properties. The original material (ProRoot MTA; Dentsply Tulsa Dental) was introduced to seal pathways of communication from the external surface of the tooth in perforation repair and as a root-end filling material in endodontic surgery. When early scientific observations and clinical outcomes demonstrated favourable biologic responses to the material, other uses for MTA were explored and investigated. MTA was found to be effective as a pulp

capping and pulpotomy agent for the repair of internal and external resorptive defects and was also shown to promote root-end induction in teeth with immature apices.<sup>(7)</sup>

MTA also provides an effective seal against dentin and cementum and promotes biologic repair and regeneration of the periodontal ligament (PDL). Because perforation repair, root-end induction, and root-end filling are essentially forms of partial canal obturation, the orthograde filling of the apical region or the entire root canal system with MTA is the next logical progression in the evolutionary application of this material.<sup>(8)</sup>

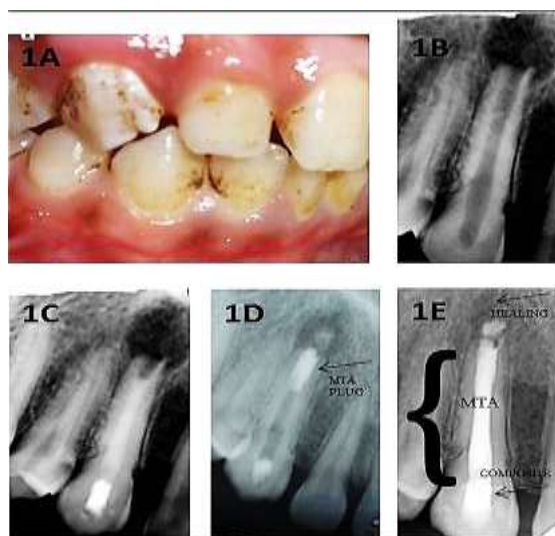
This case report describes the non-surgical management of transforming radicular cyst with open apex in maxillary canine treated with MTA.

### Case Report

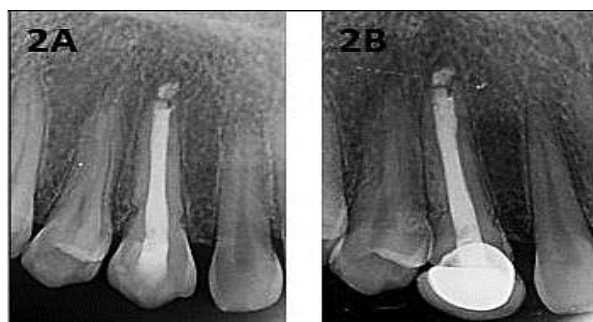A 25 year old male patient reported to the department of conservative dentistry and endodontics with a chief complaint of pain in the upper right front tooth region since 2 weeks. Patient gives a history of trauma 10 years back with a sudden blow in the canine region. The pain was intermittent and there was occasional swelling in the canine fossa region and subsided by itself after few days. Intra-oral clinical examination reveals tender on percussion and no sign of sinus opening in the buccal vestibule of tooth 13 (1A). On radiographic examination, it reveals open apex with peri-apical lesion measuring 5 x 5 mm in dimension in tooth 13 (1B). Pulp sensibility test with an electric pulp tester (Ashoo Sons API Pulp Tester, Delhi, India) showed negative response in tooth 13. Based on the clinical and radiographic finding it was diagnosed as infected granuloma transforming into radicular cyst in tooth 13. As the lesion was so huge and further root strengthening and development might be beneficial to the open apex, nonsurgical endodontic treatment was planned using MTA as a choice of material for obturation. The patient was explained about the treatment plan in detail and consent was obtained. After achieving proper local anaesthesia, under rubber dam isolation access cavity was prepared using no-2 Size access bur (Dentsply). Working length was established using electronic apex locator (Propex pixi, Dentsply) and the same was confirmed with IOPAR. Cleaning and shaping was performed using Protaper rotary files (Dentsply) under copious irrigation of saline and 5.25% NaOCl (Prime dental products, India) with the change of each instrument. The canal was dried with paper points and triple antibiotic paste placed using lentilo spirals to achieve maximum disinfection. The paste was placed beneath the cement-enamel junction to avoid the coronal discoloration and was sealed with cavif (3M, ESPE).

In the second visit the access cavity was reopened and irrigated with saline and 5.25% NaOCl agitation was done with endoactivator (Dentsply Maillefer) to

ensure complete removal of triple antibiotic paste. In the same visit calcium hydroxide dressing was placed and change of calcium hydroxide medicament was scheduled every 15 days for 3 months to evaluate the radiographic changes (1C). The lesion seemed to regress after 3 months; hence it was planned for obturation. The apical 5mm of the root canal was filled with MTA (1D) (MTA Plus Avalon Biomed Inc). Furthermore the lesion was descending in size and the tooth was completely asymptomatic. Hence the tooth was obturated completely with MTA below the cement enamel junction with vertically compaction using 1/3 and 5/7 endodontic pluggers and was restored with composite (1E). After 1 year visit it showed acceptable healing of the peri-apical region (2A). Porcelain fused to metal crown was placed. The recall radiograph after 24 months shows complete peri-apical healing and also suggested hard tissue layer over the mineral trioxide aggregate (2B).



**Fig. 1: (1A, 1B) Pre-operative intra-oral view and IOPAR, (1C)  $\text{Ca(OH)}_2$  dressing for 2 weeks. (1D) MTA plug at 4<sup>th</sup> month interval (1E) Post-operative IOPAR with MTA obturation**



**Fig. 2: (2A) Post-operative IOPAR at 1 year period. (2B) Post-operative IOPAR with Metal ceramic crown with 24 months of follow-up**

## Discussion

MTA is a bioactive silicate cement that is non-irritating to peri-apical tissues and also induces the regeneration of cementum and the PDL. The cement is an osteoinductive and cementogenic agent that stimulates immune cells to release lymphokines required for the repair and regeneration of cementum and stimulates bone coupling factors necessary for the biomineralization and healing of osseous peri-apical defects. MTA can stimulate hard tissue deposition when used as a root-end filling material.<sup>(9)</sup>

Several studies have shown that MTA placed as a root-end filling material promotes the regeneration of the PDL through a complex process of biologic repair. In an investigation in which MTA was used as a filling material in a canine model and compared against a glass ionomer sealer, MTA induced the closure of the main canals by new cementum deposition in all samples.<sup>(10)</sup> Histologic sections revealed biologic closure by the synthesis of new cementum and the regeneration of the PDL in the absence of inflammation. Furthermore, closure by deposition of cementum at the foramina of accessory canals was also a common finding in this study.<sup>(11)</sup> Similar histologic findings were observed at 180 days in canine models in which MTA perforation repairs were characterized by cementum formation and regeneration of an attached PDL. MTA might stimulate PDL fibroblasts to display the osteogenic phenotype and promote the production of osteonectin, osteopontin, and osteonidogen and increase alkaline phosphatase levels. It appears that when MTA is used for obturation purposes, it can induce biologic repair mechanisms more consistently than other traditional canal filling materials such as gutta-percha.<sup>(12)</sup>

The sealing ability of MTA has been shown to be superior to other conventional materials currently used in endodontics. A study that compared 3- to 5-mm MTA plugs against complete orthograde MTA obturation of root canals tested with a fluid filtration device revealed no significant difference in sealing ability after 4 weeks. Evidence supports the ability of MTA to provide a reliable bacteria resistant barrier when used as a retrofilling material. A recent study demonstrated that a 5-mm apical plug of MTA completely resisted microbial leakage when challenged in a model with *Actinomyces viscosus* during a 70-day test period.<sup>(13)</sup>

In a clinical retrospective outcome study, MTA was used as an artificial barrier in teeth with immature apices. By means of a peri-apical index score, 17 of 20 (85%) teeth showed healing. Also, when the MTA apexification procedure is compared against calcium hydroxide as a control, MTA demonstrated higher clinical and radiographic success at inducing root-end closure. In obturation of root canal systems by using MTA, it has been shown that MTA combined with propylene glycol paste is far easier to place in canals in

canine models.<sup>(14)</sup> The biologic response in peri-apical tissues is similar when compared with conventional obturation when MTA is mixed with distilled water. In a more recent retrospective study, 144 teeth with open apices and no apical barriers were obturated with ultrasonically compacted MTA and completed in a 1- or 2-visit protocol. Interim placement of calcium hydroxide was implemented in the 2-visit sequence. Teeth were restored and sealed in the coronal third with bonded composite. With a recall rate of 54% and a mean time to recall of 19.4 months, cases recalled after 1 year or longer showed a favourable outcome, with healing in 93.5% with 1 visit and 90.5% in teeth treated in 2 visits. It was concluded by the investigators that MTA placed in teeth with open apices in 1 visit was a viable alternative to calcium hydroxide therapy before MTA obturation by using 2 visits to promote apical closure.<sup>(15)</sup>

In general, the disadvantages of MTA are retrieval difficulties (particularly in curved canals), technique sensitivity, discoloration (grey MTA), slow set, cost and larger canal preparation requirement are reported. In the present case, MTA obturation seems to prove the better healing rate compared to conventional retrograde restoration.

Therefore developing a typical, reliable, porosity-free and easy method of orthograde MTA packing may prevent a number of needless endodontic surgeries or may help the surgical procedure to be minimally invasive.

## Conclusion

In spite of many innovations in dentistry, technical efficiency is mainly integrated with today's endodontics. As peri-apical lesions are the most commonly seen cases in the out-patient department, there is a necessity for the modus operandi and material availed to be expeditious and brisk. This case report focuses on the skills of using the most biocompatible and effective material, MTA in the peri apical lesions.

## Reference

1. Madison S, Wilcox LR. An evaluation of coronal microleakage in endodontically treated teeth: part III—in vivo study. *J Endod* 1988;14:455–8.
2. Jacobson HL, Xia T, Baumgartner JC, Marshall JG, Beeler WJ. Microbial leakage evaluation of the continuous wave of condensation. *J Endod* 2002;28:269–71.
3. Magura ME, Kafrawy AH, Brown CE Jr, Newton C (1991) Human saliva coronal microleakage in obturated root canals: an in vitro study. *Journal of Endodontics* 17, 324–31.
4. Bhomavat AS, Manjunatha RK, Rao RN, Kidiyoor KH. Endodontic management of badly broken down teeth using the canal projection method: Two case reports. *Int Endod J*. 2009;42:76–83.
5. Alves J, Walton R, Drake D. Coronal leakage: endotoxin penetration from mixed bacterial communities through obturated, post-prepared canals. *J Endod* 1998;24:587–91.

6. Xavier CB, Weismann R, de Oliveira MG, Demarco FF, Pozza DH (2005) Root-end filling materials: apical microleakage and marginal adaptation. *Journal of Endodontics* 31, 539–42.
7. Torabinejad M, Watson TF, Pitt Ford TR. Sealing ability of mineral trioxide aggregate as a root end filling material. *J Endod*. 1993;19:591–5.
8. Siqueira JF Jr., Rocha IN, Favieri A, Abad EC, Castro AJ, Gahyva SM. Bacterial leakage in coronally unsealed root canals obturated with 3 different techniques. *Oral Surg Oral Med Oral Pathol Oral Radiol Endod* 2000;90:647–50.
9. Pitt Ford TR, Torabinejad M, McKendry DJ, Hong CU, Kariyawasam SP. Use of mineral trioxide aggregate for repair of furcal perforations. *Oral Surg Oral Med Oral Pathol Oral Radiol Endod* 1995;79:756–63.
10. Regan JD, Gutmann JL, Witherspoon DE. Comparison of Diaket and MTA when used as root-end filling materials to support regeneration of the periradicular tissues. *Int Endod J* 2002;35:840–7.
11. Zhao G, Zinger O, Schwartz Z, Wieland M, Landolt D, Boyan BD. Osteoblast-like cells are sensitive to submicron-scale surface structure. *Clin Oral Implants Res* 2006;17:258–64.
12. Koh ET, Torabinejad M, Pitt Ford TR, Brady K, McDonald F. Mineral trioxide aggregate stimulates a biological response in human osteoblasts. *J Biomed Mater Res* 1997;37:432–9.
13. Yaltirik M, Ozbas H, Bilgic B, Issever H. Reactions of connective tissue to mineral trioxide aggregate and amalgam. *J Endod* 2004;30:95–9.
14. Economides N, Pantelidou O, Kokkas A, Tziafas D. Short-term periradicular tissue response to mineral trioxide aggregate (MTA) as root-end filling material. *Int Endod J* 2003;36:44–8.
15. Martin RL, Monticelli F, Brackett WW, et al. Sealing properties of mineral trioxide aggregate orthograde plugs and root fillings in an in vitro apexification model. *J Endod* 2007;33:272–5.