

Surgical management of external root resorption by MTA on middle third of the root- A Case Report

Mrunal Deshmukh^{1,*}, Baswraj Biradar², S. Saikalyan³, Aparna Palekar⁴, Nakul Rathod⁵

^{1,5}PG Student, ^{2,3}Reader, ⁴Professor & Head, Dept. of Conservative & Endodontics

***Corresponding Author:**
Email: drmrunal7@gmail.com

Abstract

A 25 year old male patient reported to department with the chief complaint of pain in lower left back region of jaw since 2-3 months based on patients history, clinical and different angulated radiographic examination, the case was diagnosed as external root resorption by chronic mechanical injuries.

After completion of endodontic (RCT) treatment, different approaches exists in the treatment of external root resorption. Previously amalgam, GIC, Super EBA, IRM was used to repair the resorption but these materials are associated with formation of periodontal defects.

New bioactive root end filling material (MTA) has excellent biological and regenerative properties and it has no toxic effects on cells so that here we chose root canal therapy combined with surgical correction/placement of MTA at defective site.

The case presented here was successful both clinically and radiographically as there were no further complaints from patient in follow up and no periodontal defects were observed at surgical site.

Keywords: External root resorption, Mineral trioxide aggregate (MTA), Surgical Endodontic Therapy.

Introduction

Resorption is the combination of physiological or pathological factors leading to the loss of enamel, dentin, cementum, and the alveolar bone by the action of polynuclear giant cells. Tooth resorption is common sequelae following injuries to or irritation of PDL and or pulp. Odontoblasts and osteoclasts cells are mainly involved in resorption.

Types of tooth resorption are mainly Internal and External resorption. One of the cause of root resorption is presence of either necrotic pulp or bacteria which is present within dentinal tubules that attracts large number of osteoclasts to the area. Consequently, resorption progresses until root canal is exposed.

In cases without perforation, the granulation tissue and the blood supply to the resorbing cells followed by repair of the perforation site with a suitable sealing material should be sufficient.⁽²⁾ However, in cases in which a pathway between the pulp canal space and the periodontal tissues is present, then root canal treatment should be done with perforation repair.

There are different types of resorption seen clinically and histologically.

Classification of Resorption

Resorption can be classified into internal and external resorption (Table 1). External resorption further classified as replacement resorption, inflammatory resorption, resorption associated with systemic diseases, cervical resorption and resorption caused by chronic mechanical injuries.⁽¹⁸⁾

Management of the root resorption involves an accurate diagnosis and insight knowledge of the various

etiological factors, and the pathological processes involved.

The following case of root resorption arrested by endodontic RCT therapy followed by surgical placement of MTA.

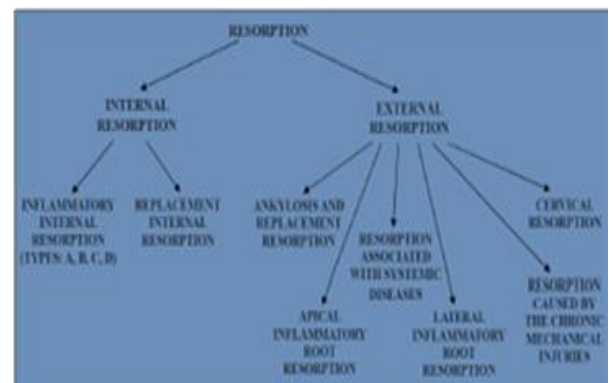


Table 1: Classification of resorption

Case Report

A 25-year-old male patient reported to the Department of Conservative dentistry and Endodontics of the Rural Dental College, Loni, with a chief complaint of pain in lower left back region of jaw since 2-3 months. Past dental history revealed extraction of an lower left molar tooth about 6 month earlier.

Based on patients history, clinical examination and different angulated radiographs the case was diagnosed as external root resorption caused by chronic mechanical injuries. The periapical radiographic film showed ragged, irregular bordered radiolucency on external surface of the root. (Fig. 1)

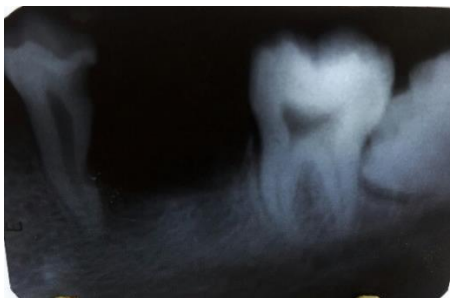


Fig. 1: Preoperative radiograph

Under local anaesthesia, root canal therapy was completed in a single visit with hand and rotary protaper universal system with Copious irrigation of saline, 1.2% chlorhexidine and 2.5% sodium hypochlorite. Root canal was obturated with gutta percha and AH plus sealer. The access cavity was restored with a glass ionomer cement filling.

After endodontic RCT therapy patient was recalled for the surgical management of the Root Resorption. Before starting of surgery whole detail treatment procedure was explained to patient and written consent was taken. Routine Blood investigations was advised to patient.

The procedure was started by anaesthetizing the area of interest and triangular flap was raised by giving crevicular and releasing incision in lower left first premolar region.⁽³⁵⁾ The whole granulation tissue was removed from the site defect with curette. MTA powder was mixed with distilled water and placed in the affected area. After initial set of MTA, 4-0 abraded silk sutures was used to close the flap using direct interrupted suturing technique (Fig. 2) and intraoral radiograph was taken (Fig. 3). Postoperative instructions were given to the patient.

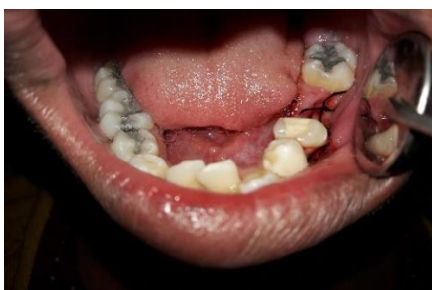

Fig. 2: Clinical picture of flap closure

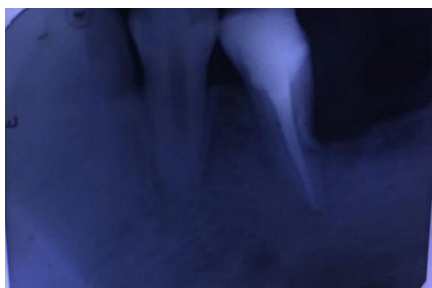

Fig. 3: Radiograph immediate after surgery

Patient was recalled after seven days for removal of sutures. Patient was recalled after 1, 3 and 6 months (Fig. 4) for follow up and radiograph was taken (Fig. 5), satisfactory healing was seen.

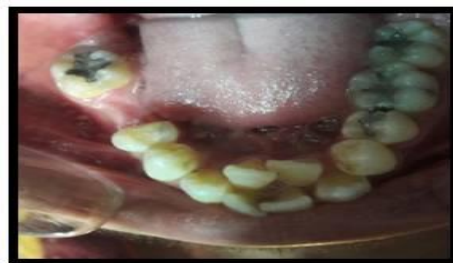

Fig. 4: Follow up clinical picture

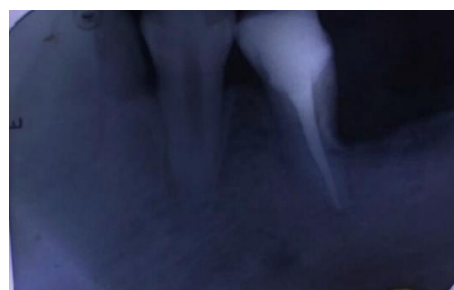

Fig. 5: Follow up radiograph

Discussion

The lesion in this case was diagnosed as external root resorption which was based on radiographic examination. Different approaches exist in the treatment of external root resorption. Previously amalgam, GIC, super EBA, IRM was used to repair the resorption but these materials are associated with formation of periodontal defect.

Amalgam produces corrosive by-products.^(1,2,3) Also it is moisture sensitive and causes tissue tattooing. Scattered particles of amalgam are difficult to remove and are non resorbable.

A study by Tanzilli et al suggested that amalgam gives a poor seal and it does not prevent penetration of microorganisms and their products in the periradicular tissues when used as a retrograde filling material. Georgiev et al.⁽⁵⁾ reported Clinical case of paresthesia due to disseminated amalgam retrograde filling in the upper jaw and soft tissues. Based on clinical studies many surveys have re-reported poor outcomes with amalgam used as a root-end filling material.^(1,6)

The sealing ability of polycarboxylate cement, as shown by Barry et al using dye penetration methods is inferior to amalgam.⁽⁷⁾ Mostly super EBA and IRM are commonly used zinc oxide cements. Pitt Ford TR et al concluded that the tissue response to Super-EBA as a root-end filling is acceptable and considerably more favorable than that to amalgam. ZOE cement is also moisture sensitive, causes initial tissue irritation, reasonability is questionable. But, super-EBA is

radioluscent and technique sensitive. The eugenol content of super-EBA may be a source of irritation to the tissues.

Grey Mineral trioxide aggregate (MTA) was developed at Loma Linda University, California by Torabinajed & co-workers in 1993. Compared with other root-end filling materials MTA has shown excellent seal and hard tissue repair. The hydrophilic particles present in powder are able to set in the presence of moisture. Hydration of the powder forms a colloidal gel that hardens.⁽⁴⁾ Tissue culture experiments suggest that MTA induces cementogenesis, permitted cementoblast attachment and growth. MTA has no toxic effects on cells and is reported to cause an increase in cell proliferation and released calcium in high amounts.⁽¹⁴⁾

Retrograde filling by using composite resins requires more conservative preparation of the root-end cavity. Some authors have reported that some composite resins have cytotoxic effect that may persist 30 days or longer.⁽⁸⁾ Biodentine is a calcium silicate based material introduced in 2010 as a material for repair of perforations, resorption repair and root-end fillings.⁽⁹⁾ An in vitro study to compare the sealing ability of MTA, Calcium phosphate cement and Biodentine, MTA showed the highest seal and the least dye absorbance. Biodentine showed a seal slightly less than MTA.⁽¹⁰⁾

Bioaggregate is a new bioceramic root repair. Bioaggregate is more biocompatible than MTA.⁽¹¹⁾ Leal et al showed that the sealing ability of white MTA and Bioaggregate were similar in preventing glucose penetration, but slightly less than Ceramicrote. An in vitro comparative study of the sealing ability of Diadent Bioaggregate and other root-end filling materials (Gutta-percha, amalgam, IRM, White MTA) was done using methylene blue dye penetration technique. The results showed that microleakage was significantly less in Bioaggregate when compared to amalgam, IRM and White MTA.⁽¹²⁾

Several dye leakage studies have demonstrated the fact that MTA leaks significantly less than other root-end filling materials. Fischer et al⁽¹³⁾ determined the time needed for *Serratia marcescens* to penetrate a 3 mm thickness of zinc-free amalgam, Intermediate Restorative Material (IRM), Super-EBA, and MTA when these materials were used as root-end filling materials. The number of days required for *S. marcescens* to penetrate the four root-end filling materials and grow in the phenol red broth was recorded and analyzed. They reported that most of the samples filled with zinc-free amalgam leaked bacteria in 10 to 63 days. IRM began leaking in 28 to 91 days. Super-EBA began leaking in 42 to 101 days. MTA did not begin leaking until day 49. At the end of the study, four of the MTA samples had not exhibited any leakage. Statistical analysis of the data indicated Mineral Trioxide Aggregate to be the most effective root-end filling material against penetration of *S. marcescens*. The marginal adaptation of MTA was better with or without

finishing when compared to IRM and Super EBA.⁽¹⁴⁾ MTA, when used as a root-end- filling material, showed evidence of healing of the surrounding tissues.^(15,16) Most characteristic tissue reaction of MTA was the presence of connective tissue after the first postoperative week. Lindeboom et al⁽¹⁷⁾ performed a randomized clinical prospective study to evaluate the application of MTA and IRM as retrograde sealers in surgical endodontics. One hundred single-rooted teeth were surgically treated. After randomization, MTA or IRM was used as a retrosealer. Radiographs were taken 1 week, 3 months, and 1 year postoperatively. Complete healing was observed in 64% of the MTA treated teeth vs 50% of the IRM-treated teeth. Incomplete healing was seen in 28% (MTA) vs 36% (IRM), and unsatisfactory in 6% (MTA) vs 14% (IRM). Only 1 failure was seen (MTA). No statistically significant differences were found between the 2 retrofilling materials.

Compared with other root end filling materials MTA having an excellent biological and regenerative properties. MTA has negligible cellular toxicity and thereby, promotes hard tissue repair. It also provides good seal even in the presence of moisture and blood and is more radio- opaque. So that, here we chose root canal therapy combined with surgical correction or placement of MTA at defective site of root.

In this case, no periodontal defect was observed. The case presented here, was successful both clinically and radiographically.

Conclusion

The case presented here was successful both radiographically and clinically, as there were no further complaints from patient in follow up and survival rate (or life of tooth) of affected tooth is increased by using MTA biomaterial.

References

1. Chong BS, Ford TRP. Root-end filling materials rationale and tissue response. *Endodontic Topics*.2005;11:114-130.
2. Hohenfeldt PR, Aurelio JA, Gerstein H. Electro chemical corrosion in the failure of apical amalgam. Report of two cases. *Oral Surg Oral Med Oral Pathol*. 1985;60(6):658-60.
3. Pleva J. Corrosion and Mercury Release from Dental Amalgam. *Journal of Orthomolecular Medicine*. 1989;4(3):141-158.
4. Zhu Q, Safavi KE, Spangberg LS. Cytotoxic evaluation of root-end filling materials in cultures of human osteoblast-like cells and periodontal ligament cells. *Endod*. 1999 Jun;25(6):410-2.
5. Georgiev T, Peev S, Papanchev G, Borisova-Papancheva Ts, E Aleksieva. A clinical case of paresthesia due to amalgam retrograde filling disseminated in the upper jaw and soft tissues. *Scripta Scientifica Medica*. 2012;44(2):97-101.
6. Pereira CL, MS Cenci, FF Demarco. Sealing ability of MTA, Super EBA, Vitremer and amal-gam as root-end filling materials. *Braz Oral Res*; 2004;18(4):317-21.
7. Gene Norman Barry, Alan. G. Selbst, Erbert W. D' Anton, Richard M. Madden, Sealing quality of polycarboxylate

- cements when compared to amalgam as a retro-filling material, *Journal of oral medical, oral surgery and oral pathology*, 42(1), 1976, 109-116.}
8. Andreasen J, Munksgaard E, Fredebo L, Rud J. Periodontal tissue regeneration including cementogenesis adjacent to dentin-bonded retrograde composite fillings in humans. *J Endod*.1993;19:151-3.
 9. Trond Bjorvik Osen, Ina Iselin Astrup, Carl Haavard Knutsson, Biodentine as a root-end filling, 2012.
 10. Tulsi Sanghavi, Nimisha Shah, Ruchi Rani Shah, Comparative analysis of sealing ability of Biodentine and Calcium phosphate cement against MTA as a furcal repair material, *National journal of integrated research in medicine*, 4(3), 2013, 56-60.
 11. Yusuf-Burak Batur, Gozde Acar, Yagmur Yalcin, Seckin Dindar, Hande Sancakli, Ugur Erdemir, The cytotoxic evaluation of mineral trioxide aggregate and bioaggregate in the subcutaneous connective tissue of rats, *Medical oral Pathology Oral Cir Bucal*, 18(4), 2013, 745-751.
 12. El Sayed MA, Saeed MH. In vitro comparative study of sealing ability of Diadent Bioaggregate and other root-end filling materials, *Journal of conservative dentistry*, 15(3), 2012, 249-252.
 13. Fischer E, Arens D, Miller C. Bacterial leakage of mineral trioxide aggregate as compared with zinc free amalgam, intermediate restorative material and Super-EBA as a root-end filling material *J Endod*. 1998;24:176-179.
 14. Gondim E, Zaia AA, Gomes BPPA, Ferraz CCR, Teixeira FB, Souza-Filho FJ. Investigation of the marginal adaption of root-end filling materials in root-end cavities prepared with ultrasonic tips. *Int Endod J*. 2003;36:491-499.
 15. Torabinejad M, Pitt Ford TR. Root end filling materials-a review. *Endodont Dent Traumatol*. 1996;12:161-178.
 16. Torabinejad M, Wilder Smith P, Pitt Ford TR. Comparative investigation of marginal adaptation of mineral trioxide aggregate and other commonly used root end filling materials. *J Endod*. 1995;21:295-99.
 17. Lindeboom JA, Joost WFH, Frans K, Akker H A. comparative prospective randomized clinical study of MTA and IRM as root-end filling materials in single-rooted teeth in endodontic surgery. *Oral Surg Oral Med Oral Pathol*. 2005;100:495-500.
 18. Sak Anna K, Szkaradkiewicz, algorzata Radeck Tooth root resorption: etiopathogenesis and classification. *MicroMedicine* 2016;4(1):21-31.